Annals of Clinical Case Studies

ISSN: 2688-1241

Case Report

An Orthodontic Approach to Improve Speech and Swallowing of Patients with Kennedy Disease

Abdulraheem S[1], AlMutairi S[2], Alyahya Y[3] and Alduraie A[4*]

[1]Department of Orthodontics, Bneid Algar specialty Dental Center, Kuwait

[2]Department of Orthodontics, Al-Jahra specialty Dental Center, Kuwait

[3]Department of Oral and Maxillo-Facial Surgery, Al-Jahra specialty Dental Center, Kuwait

[4]Dental Administration, Health Capital Area, Kuwait

Abstract

Background: Kennedy disease is a rare inherited X-linked recessive disorder that manifests mainly as muscle weakness leading to difficulty in speech and swallowing.

Objective: The purpose of this report is to present an orthodontic intervention that improved the quality of life for a patient with Kennedy disease.

Methods: The treatment method used employed orthodontic miniscrews combined with elastics.

Results: Using orthodontic elastics reduced patient's effort to elevate the mandible and it resulted in enhanced function.

Conclusion: Significant improvements such as speech, swallowing, and facial expressions were achieved after the intervention.

Keywords: Kennedy disease; Miniscrews; Orthodontic elastics; Speech; Swallowing

Introduction

Spinal and bulbar muscular atrophy, or Kennedy Disease (KD), is an X-linked recessive disorder caused by pathogenic CAG expansion in the first exon of the androgen receptor, inducing degeneration of spinal and bulbar a-motor neurons and loss of sensory neurons in the dorsal root ganglia. The reported prevalence ranged between 1 in 40,000 to 1.6 in 100,000 [1,2]. The clinical characteristics consisted of progressive muscle weakness, muscle atrophy and bulbar involvement, fasciculations of limb and facial muscles, speech and swallowing difficulties, and often gynecomastia and infertility [3]. Concerning orthodontics, patients with KD have predominant muscle atrophy and weakness in the tongue and proximal musculature, leading to jaw-dropping and impairment of speech and mastication [4].

Previous data were not published describing interventions to aid speech for patients with KD. Therefore, this case report was done to evaluate the effectiveness of using orthodontic miniscrews combined with elastics to aid speech for patients suffering from KD.

Case Presentation

A 58 years old male presented at the oral maxillofacial department with a chief complaint of speech difficulty. His medical reports showed that he has KD with positive fatigue, type II diabetes mellitus, peripheral neuropathy, and hypertension. He has been suffering from muscle weakness for the past 4 years.

Clinical examination of the head and neck region showed muscle weakness mainly affecting the mandibular elevator muscles with good tongue control (Figure 1A and B). The patient had difficulty in speech and most of his words were not clearly understood. To aid speech and mastication, the patient uses his hand to lift the mandible and produce pressure on the chin, in the anterior-posterior direction. This direction simulates the class III elastic force (Figure 2A and B). Figure 3 and 4 show extra and intra-oral photos of the patient.

Treatment objective, plan, and other alternatives

Improving patient's speech and mastication were the treatment objectives. After consulting the orthodontic department, a decision was made to place four miniscrews, one in each quadrant. The miniscrews are to be placed in positions that insure, when connected with intermaxillary elastics, the simulation of class III elastics force, which we assumed that it will help in seating the temporomandibular joint in its normal position. If the intervention was successful but the miniscrews failed with time, surgical plates with hooks will be the replacement for better long-term stability.

Treatment progress and results

Periapical radiographs were taken on the sites decided for miniscrews placement to ensure that enough space is available between the roots (Figure 5). Local anesthetic agent (2% Lidocaine 1/100000 epinephrine) was used, and the four miniscrews were inserted in predetermined sites. Periapical radiographs were taken to check the positions of miniscrews relative to adjacent roots, showing

Citation: Abdulraheem S, AlMutairi S, Alyahya Y, Alduraie A. An Orthodontic Approach to Improve Speech and Swallowing of Patients with Kennedy Disease. Ann Clin Case Stud. 2021; 3(1): 1040.

Publisher Name: Medtext Publications LLC

Manuscript compiled: Apr 16th, 2021

***Corresponding author:** Alhanoof Alduraie, Dental Administration, Ministry of Health, Kuwait, Tel: +965-99945988; E-mail: alhanoof.alduraie@gmail.com

Figure 1: A and B) Anterior and lateral view of the patient while resting.

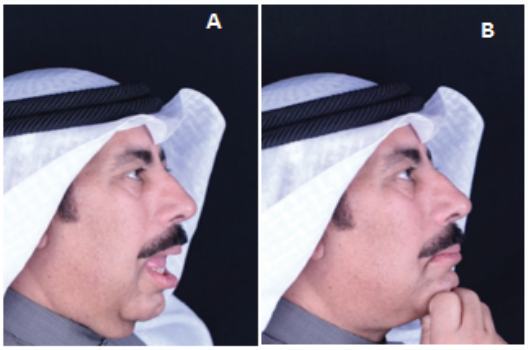

Figure 2: A and B) Lateral view during rest and during chin support using the fist to improve speech.

no interference (Figure 6). Finally, miniscrews were connected using double elastics on each side (Figure 7).

The patient reported significant improvements in pronunciation and speech clarity. In addition, the patient's smile improved significantly (Figure 8).

The patient was asked to read sentences in Arabic in three different positions. Videos 1, 2 and 3 show the patient reading without any help, using his hand, and using elastics, respectively.

video 1 - https://youtu.be/TRLz1xq36f0
video 2 - https://youtu.be/38G9qLO-C1I
video 3 - https://youtu.be/-AqnDk4hShI

Discussion

Treatment of speech impairment in patients with KD is not reported in the literature. Theoretically, multiple noninvasive auxiliaries such as chin cap and chin strap could be used to improve speech and mastication; however, these devices are unesthetic as they are placed extra-orally. Although orthodontic mini plates with hooks need to be placed under general anesthesia; yet, they were considered the best intervention in relation to long-term stability. The success rate of orthodontic miniplates is 89%, while orthodontic miniscrews inserted buccally have a success rate of 71% [4-6]. Miniscrews were used for this case as they can be placed under local anesthesia, and are cheaper.

Having an equal distance between miniscrews on each side will ensure equality of force (Figure 7). The elastics can be changed either for both sides or at one side until the patient feels comfortable. The elastic force direction must simulate the patient's hand support force direction.

The end results of the intervention were extremely satisfying for both the patient and the authors. Not only the main goals of the treatment where achieved, facial expressions were also improved, especially smiling, as using elastics to support the mandible helped facial expression muscles to be more relaxed.

Summary and Conclusion

Mini-screws combined with elastics significantly improve speech, mastication, and facial expressions in patients with KD.

References

1. Fischbeck KH. Kennedy disease. J Inherit Metab Dis. 1997;20(2):152-8.
2. Guidetti D, Sabadini R, Ferlini A, Torrente I. Epidemiological survey of X-linked bulbar and spinal muscular atrophy, or Kennedy disease, in the province of Reggio Emilia, Italy. Eur J Epidemiol. 2001;17(6):587-91.
3. Kennedy WR, Alter M, Sung JH. Progressive proximalspinal and bulbar muscular atrophy of late onset. A sex-linked recessive trait. Neurology. 1968;18(7):671-80.
4. Cheng SJ, Tseng IY, Lee JJ, Kok SH. A prospective study of the risk factors associated with failure of mini-implants used for orthodontic anchorage. Int J Oral Maxillofac Implants. 2004;19(1):100-6.
5. Sobue G, Hashizume Y, Mukai E, Hirayama M, Mitsuma T, Takahashi A. X-linked recessive bulbospinal neuronopathy: a clinicopathological study. Brain. 1998;112(pt 1): 209-32.

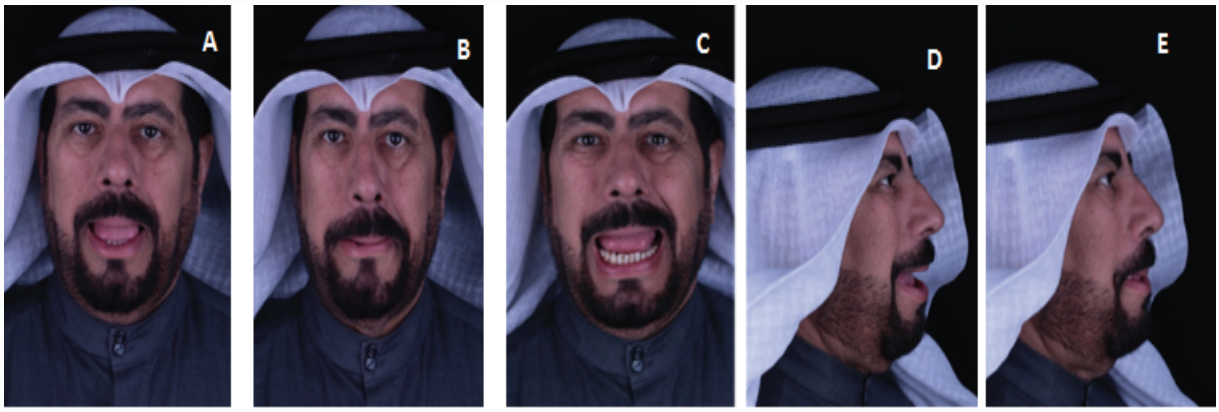

Figure 3: A) Frontal view at rest B) Frontal view during Closure C) Frontal view while smiling D) Lateral view at rest E) Lateral view during closure.

6. Hourfar J, Bister D, Kanavakis G, Lisson JA, Ludwig B. Influence of interradicular and palatal placement of orthodontic mini-implants on the success (survival) rate. Head Face Med. 2017;13(1):14.

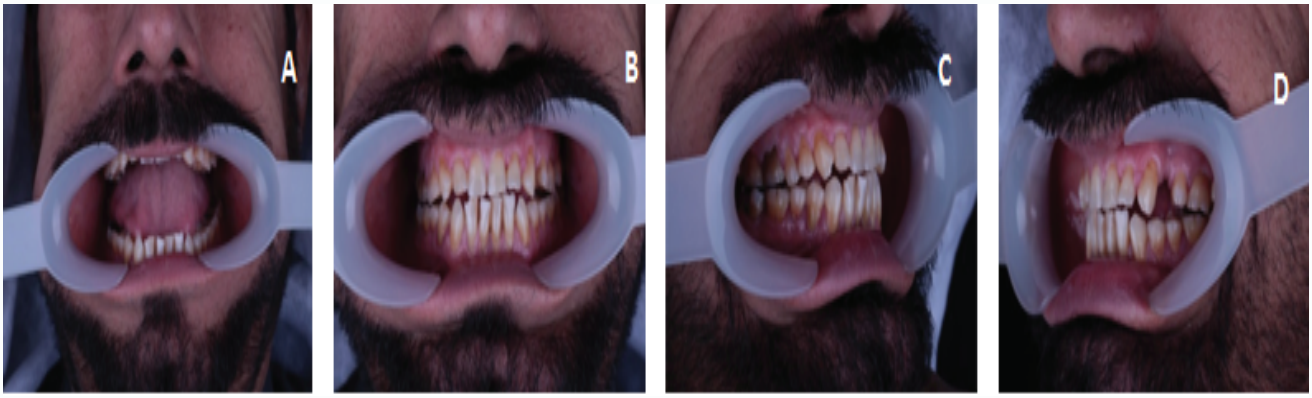

Figure 4: Intra oral photos; A) Frontal view at rest B) Frontal view during Closure C) Right lateral view D) Left lateral view.

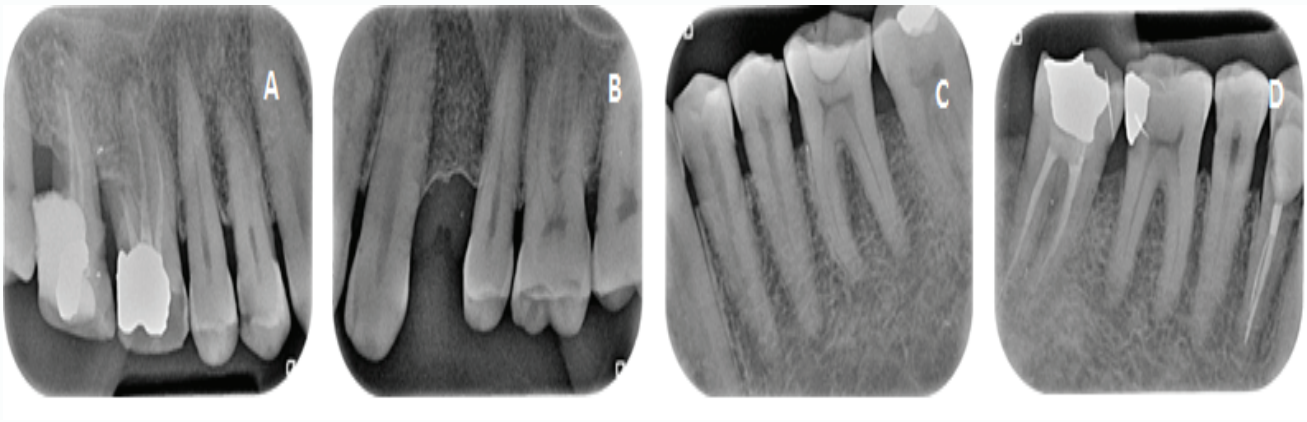

Figure 5: Intra-oral periapical radiographs showing interradicular space between the roots to determine locations for mini-screws insertion. A) Maxillary right side B) Maxillary left side C) Mandibular left side and D) Mandibular right side.

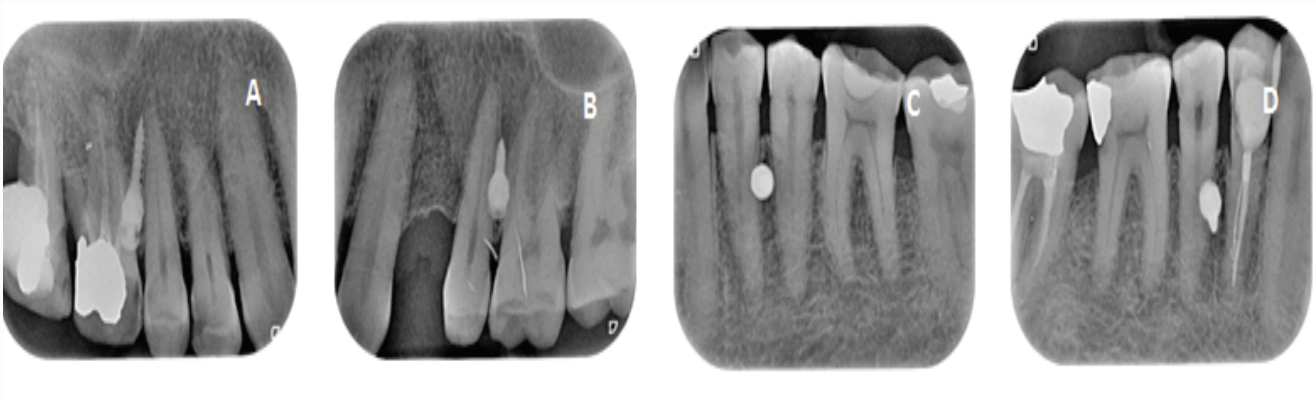

Figure 6: Intra-oral periapical radiographs of the mini-screws after insertion; A) Maxillary right side B) Maxillary left side C) Mandibular left side and D) Mandibular right side.

Figure 7: Intra-oral photos after mini-screws insertion; A) Frontal B) Right lateral view C) Left lateral view.

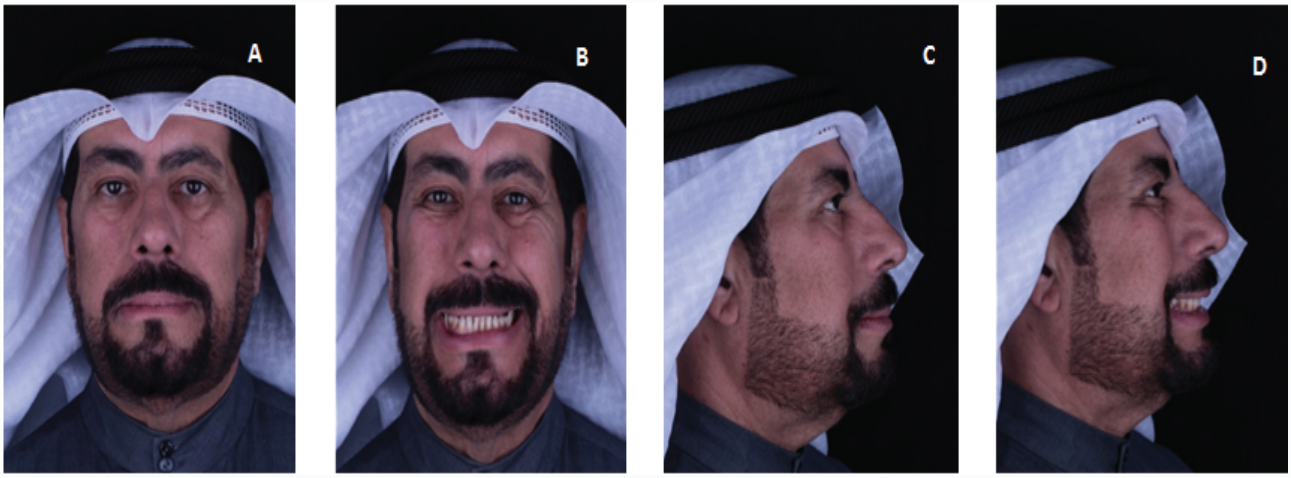

Figure 8:Intra-oral photos showing patient facial expressions; A) Frontal view at rest B) Frontal view during smiling C) Lateral view at rest D) Lateral view during smiling.