Cardiovascular Surgery International

ISSN 2692-7969

Research Article

Cardiac Fulcrum

Trainini Jorge[1], Beraudo Mario[2], Wernicke Mario[3], Trainini Alejandro[1,2], Lowenstein Jorge[4], Bastarrica María Elena[2] and Lowenstein Diego[4]*

[1]*Department of Cardiac Surgery, Hospital Presidente Perón, Argentina*

[2]*Department of Cardiac Surgery, Clínica Güemes, Argentina*

[3]*Department of Pathology, Clínica Güemes, Argentina*

[4]*Department of Cardiology, Investigaciones Médicas, Argentina*

Abstract

Objective: The cardiac muscle cannot be anatomically free in the thorax. Therefore, think and analyze that there could be a myocardial support point (lever fulcrum).

Material and methods: They were used: 1) cardiac dissection in ten young (two years old) bovine hearts (800 g to 1000 g); 2) cardiac disection in eight human hearts: one embryo, 4 g; one 10 years old, 250 g; and six adult, mean weight 300 g. The myocardial band was unrolled in its entirety. The extracted pieces were analyzed by anatomy and histology.

Results: In anatomical investigations we have found in the all human and bovine hearts studied a nucleus underlying the right trigone of bone, chondroid or tendon histological structure. The microscopic analysis revealed in bovine hearts a trabecular osteochondral matrix (fulcrum). In the ten year old human heart and in the fetus, a central area of the fulcrum formed by chondroid tissue was found. Histology found a tendon matrix in adult human hearts. This fulcrum is attached to the myocardium and would serve to support both the origin and the end of the myocardium.

Conclusion: The cardiac fulcrum found in the anatomical investigation of bovine and human hearts would clarify the point of support of the myocardial muscle to complete its rotating function.

Keywords: Heart; Cardiac anatomy; Ventricular band; Cardiac structure

Introduction

The development of the myocardial band exposed in 1970 by Torrent Guasp [1,2] allows to see that it starts and ends at the origin of the great vessels, therefore the anchoring of the fibers is not done in the atrioventricular rings. The myocardium is attached to these rings but not inserted into it. The myocardial band consists of a set of muscle fibers twisted on themselves like a string (theory of the string), flattened laterally as a band, which by turning two spirals defines a helicoid that delimits the two ventricles and conforms its functionality [3,4]. However, Torrent Guasp did not analyze the possibility of supporting the heart muscle, as the muscle has for its function.

Later, Maclvear [5-7] considered that the ventricular walls we are made up of an intricate Three-Dimensional (3D) network of aggregated cardiomyocytes specifying: "None of the histological studies of the myocardium that we are aware, in contrast, have provided any evidence for an origen and insertion as described for the alleged unique myocardial band" [5].

In this research we consider that the muscle fibers are inevitably forced to "intertwine" with the cardiac fulcrum to fulfill its hemodynamic function of shortening-torsion and elongation-distortion [8,9]. Therefore, we think and analyze that there could be a myocardial support point (lever fulcrum).

Citation: Jorge T, Mario B, Mario W, Alejandro T, Jorge L, María Elena B, et al. Cardiac Fulcrum. Cardiovasc Surg Int. 2021;2(1):1011.

Publisher Name: Medtext Publications LLC

Manuscript compiled: Mar 11th, 2021

***Corresponding author:** Jorge Carlos Trainini, Hospital Presidente Perón, Avellaneda, Provincia de Buenos Aires, Argentina, Tel: + 5411 15 40817028; E-mail: jctrainini@hotmail.com

Material and Methods

The methods used were:

1) Cardiac dissection in ten bovine hearts (two years old, 800 g to 1000 g).
2) Cardiac disection in eight human hearts: one embryo, 4 g; one 10 years old, 250 g; and six adult, mean weight 300 g.
3) Histology was performed with 10% formalin buffer hematoxylin-eosin stain; Masson's trichrome staining technique and four microns seccions.

The hearts examined correspond to material from morgue (human) and slaughterhouses (bovine). The study had the approval of the Ethics Committee of all the institutions involved. The key maneuver to achieve myocardial unwinding consists in severing superficial fibers called interventricular or aberrant fibers [1] that extend transversely through the anterior aspect of the ventricles to be able to enter through the anterior interventricular groove. It should be understood that as the myocardial band is unfolded, separating the pulmonary artery and the pulmo-tricuspid cord (anterior) from the ascending segment (posterior), the vision of the homogeneous anatomical reality is lost. This concurrence of the beginning and end of the muscle band in the cardiac fulcrum constitutes a meeting point between the right segment and the ascending segment, origin and end of the myocardial band (Figure 1).

Results

This structure, which we have called cardiac fulcrum, was the only perceptible edge where the muscle band fibers originate and end

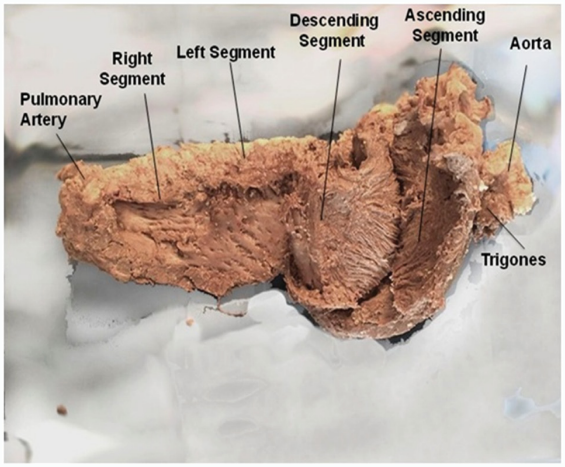

Figure 1: Unfolding of the myocardium.

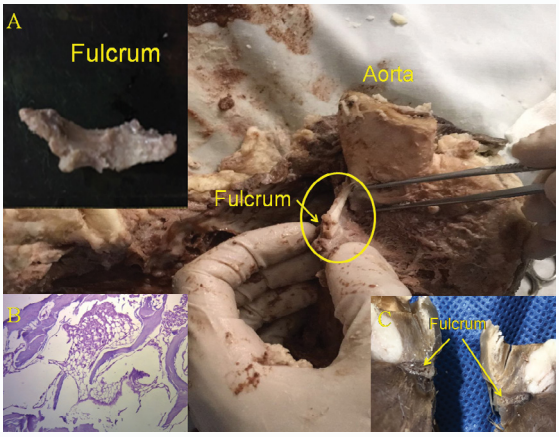

Figure 2: Cardiac fulcrum (bovine heart). (A): Resected piece; (B): Mature trabecular bone forming the cardiac fulcrum tissue. Hematoxylin-eosina stain at low magnification (10x); (C): Cardiac fulcrum in other view.

(Figures 2 and 3). In analogy, as with skeletal muscle, we found in the myocardial muscle that its contraction takes place between a fixed point of support (insertion of the ascending segment in the fulcrum) and a more mobile one (insertion of the right segment in the anterior face of the fulcrum) (Figures 3 and 4). This last point was shown in the dissection of a fragile character, totally opposite to the solidity of the opposite end of the band in its attachment to the fulcrum.

Histology

In bovine, microscopy of the cardiac fulcrum finds an osteochondral matrix (Figure 2). The size of the fulcrum was 45 mm × 15 mm and its shape was triangular. The same structure was found in chimpanzees [10].

In the 10-year-old human heart, Figure 5A shows that the central area of the fulcrum is formed by chondroid tissue. It is logical, given the age, that the fulcrum is smaller and has more chondroid tissue than bone. In the 23-week-old human fetus, this finding was repeated. Characteristic prechondroid bluish areas can be seen in a myxoid stroma (Figure 5B).

The osseous structure in the bovine os cordis and its relationship with the myxoid-chondroid cardiac fulcrum texture in human hearts, even in gestational stages, is rational for the interpretation analysis. This disparity is associated with the different age evolution from chondroid to osseous material and by the greater force developed in bovids requiring a more rigid supporting point.

However, the histological analysis of the fulcrum in adult human hearts evidenced a tendinous collagenous matrix, needing an additional clarification. In principle, there is constancy in the detection, site and morphology of the fulcrum in all the hearts analyzed. This means that from a functional point of view, its presence is akin to myocardial band insertion, as established in the histological analysis, becoming a solid point of interpretation to achieve its biomechanical function. In this supporting point, the muscle fibers are inevitably forced to "intertwine" with the connective, chondroid or osseous fulcrum, and our anatomical and histological investigations have shown that this insertion attaches both the origin and end of the myocardial band (Figures 6 and 7).

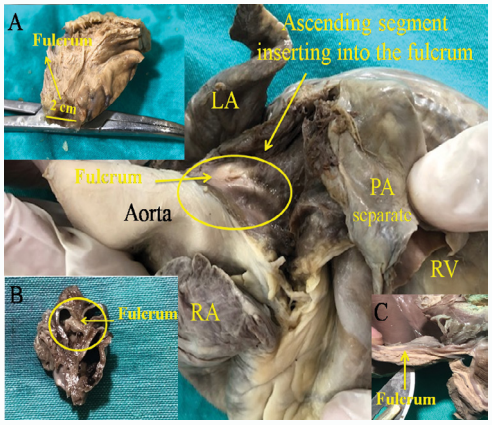

Figure 3: Cardiac fulcrum (human hearts). (A): 10-year-old; (B): 23 week gestation human embryo heart; (C): fulcrum resected from an adult human heart.

Figure 4: Fulcrum in the adult human heart. Note the right segment corresponding to the Right Ventricle (RV) arising from the fulcrum.

Discussion

We are located in front of the aortic valve at the level of the origin of the right coronary artery. In this place the bridge band and the anterior septal band are born, both belonging to the right segment of the myocardial band, forming a muscular raphe, where precisely the point of origin of the myocardial band is considered [11-13].

The pulmo-tricuspid cord, where the myocardial band begins with its right segment, is located in front of a compact area of

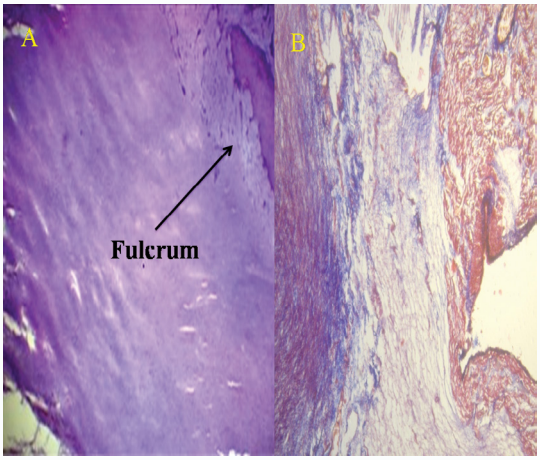

Figure 5: (A): Ten year old human heart. Central area of the fulcrum formed by chondroid tissue. Hematoxylin-eosin stain (15x). (B): Cardiac fulcrum in a 23-week gestation fetus showing prechondroid bluish areas in a myxoid stroma. masson´s trichrome staining technique (15x).

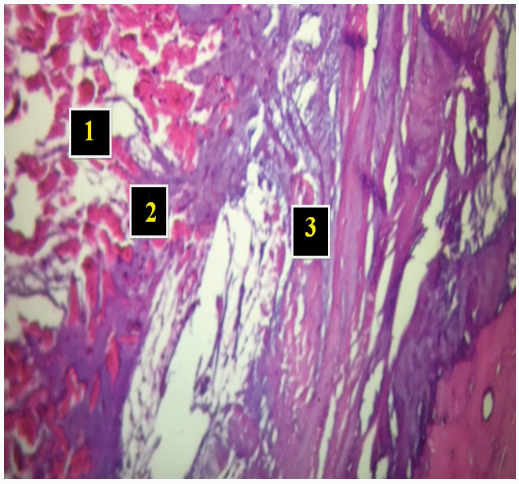

Figure 6: Insertion of the myocardium in the fulcrum (bovine heart). (1): Myocardial fibers and myxoid stroma; (2): Myocardial tapes in a chondroid stroma (insertion); (3): Bony cortical tissue of the fulcrum.

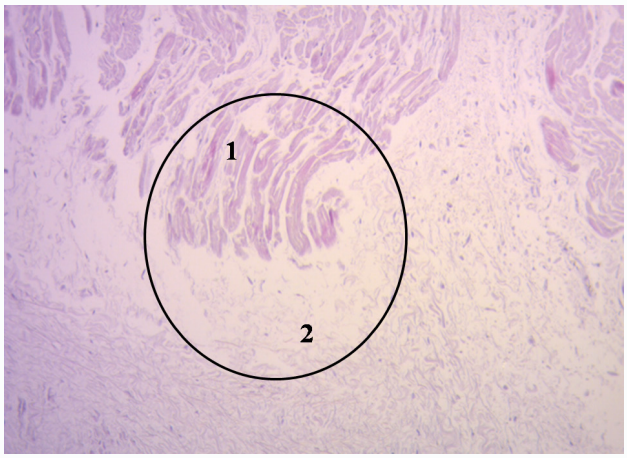

Figure 7: Cardiomyocytes penetrating the fibro-colagenous tissue (adult human heart). (1): Cardiomyocytes; (2): Fibrocolagenous matrix. The circle details the insertion site.

fibrous connective tissue that surrounds the anterior two thirds of the circumference of the U-shaped aortic ring, whose open end (posterior) is occupied by the anterior leaflet of the mitral valve. At its ends this tissue has two trigones. The right fibrous trigone has the tricuspid valve on its right, the aortic ring behind it and the pulmo-tricuspid cord anteriorly. The less prominent left trigones lies between the left mitral valve on the left and the aorta. Both trigones are connected medially by collagen fibers. In the continuity of the aortic orifice with the posterior leaflet of the mitral there is no connective tissue, since laterally, the two fibrous bodies are continued by a band of connective tissue that surrounds the orifice of the mitral valve partially to gradually fade. The septal valve of the mitral is located between both trigones as a wedge.

Adjacent to the right trigone (anterior and inferior) we found a structure with solidity to palpation and homogeneous osteo-chondroid histology where the fibers of the right segment and ascending segment are tied. This insertion is the fulcrum of the myocardium both at the level of its origin and that of its termination.

In relation to this finding, research on this fixation point, which we call cardiac fulcrum, becomes a piece that supports and allows the band to exert with the necessary force the fundamental rotatory movements of the left ventricle [14,15]. The fact that the band is anchored to the cardiac fulcrum in its finalization corresponds to the active movements of the cardiac cycle (systole and suction) that involves the apical loop (descending and ascending segments).

Conclusion

The cardiac fulcrum found in the anatomical investigation would clarify the point of support of the myocardial band to complete its rotating function. Without its presence, the heart could not meet the hemodynamic efficiency of ejecting blood at a speed of 300 cm/s.

References

1. Trainini JC, Elencwajg B, López Cabanillas N, Herreros J, Lago N, Lowenstein J, et al. Stimuli propagation, muscle torsión and cardiac suction effect through electrophysiological research. In. Basis of the New Cardiac Mechanics. The Suction Pump. Trainini JC and col. Lumen, Bs. 2015:39-61.
2. Guasp FT, Buckberg G, Carmine C, Cox J, Coghlan H, Gharib M. The structure and function of the helical heart and its buttress wrapping. I. The normal macroscopic structure of the heart. Semin Thorac Cardiovasc Surg. 2001;13(4):301-19.
3. Buckberg GD, Coghlan HC, Torrent Guasp F. The structure and function of the helical heart its buttress wrapping. VI. Geometrics conceps of heart failure and use for structural correction. Sem Thorac Cardiovasc Surg. 2001;13(4):386-401.
4. Ballester M, Ferreira A, Carreras F. The myocardial band. Heart Fail Clin. 2008;4(3):261-72.
5. MacIver DH, Stephenson RS, Jensen B, Agger P, Sanchez-Quintana D, Jarvis JC, et al. The end of the unique myocardial band: Part I. Anatomical considerations. Eur J Cardiothorac Surg. 2018;53(1):112-19.
6. MacIver DH, John B, Partridge JB, Agger P, Stephenson RS, Boukens BJD, et al. The end of the unique myocardial band: Part II. Clinical and functional considerations. Eur J Cardiothorac Surg. 2018;53(1):120-28.
7. Anderson R, Ho S, Redman K, Sanchez-Quintana D, Punkenheimer P. The anatomical arrangement of the myocardial cells making up the ventricular mass. Eur J Cardiothoracic Surg. 2005;28(4):517-25.
8. Trainini JC, Trainini A, Valle Cabezas J, Cabo J. Left Ventricular Suction in Right Ventricular Dysfunction. EC Cardiol. 2019;2(1):572-7.
9. Streeter DD, Spotnitz HM, Patel J, Ross J, Sonnenblick EH. Fiber orientation in the canine left ventricle during diastole and systole. Biophysical J. 1969;24:339-47.

10. Moittié S, Baiker K, Strong V, Cousins E, White K, Liptovszky M, et al. Discovery of os cordis in the cardiac skeleton of chimpanzees (Pan troglodytes). Sci Rep. 2020;10:9417.

11. Carreras F, Ballester M, Pujadas S, Leta R, Pons-Lladó G. Morphological and functional evidences of the helical heart from non-invasive cardiac imaging. Eur J Cardiothoracic Surg. 2006;29(Suppl 1):S50-5.

12. Trainini JC, Elencwajg B, López-Cabanillas N, Herreros J, Lowenstein J, Bustamante-Munguira J, et al. Ventricular torsion and cardiac suction effect: The electrophysiological analysis of the cardiac band muscle. Interventional Cardiol. 2017;9(1):45-51.

13. Mora V, Roldán I, Romero E, Saurí A, Romero D, Perez-Gozabo J, et al. Myocardial contraction during the diastolic isovolumetric period: analysis of longitudinal strain by means of speckle tracking echocardiography. J Cardiovasc Dev Dis. 2018;5(3):41.

14. Kocica MJ, Corno AF, Carreras-Costa F, Ballester-Rodes M, Moghbel MC, Cueva CN, et al. The helical ventricular myocardial band: global, three-dimensional, functional architecture of the ventricular myocardium. Eur J Cardiothorac Surg. 2006;29(Suppl 1):S21-40.

15. Henson RE, Song SK, Pastorek JS, Ackerman JH, Lorenz CH. Left ventricular torsion is equal mice and humans. Am J Physiol Heart Circu Physiol. 2000;278:H1117-23.