American Journal of Surgery Case Reports

Short Communication

Clear Cell Carcinoma of the Ovary: A Case Report

*FZ El Hachami *, Sabiri R, Imami Y, Berrehili H, Gotni A, Boufettal H, Mahdaoui S and Samouh N*

Department of Obstetrics and Gynaecology, CHU Ibn Rochd Casablanca, Morocco

Abstract

Clear cell carcinoma is a rare carcinoma of the ovary, often associated with endometriosis. Patients are often diagnosed at an early stage of the disease, which improves prognosis and management. The general guidelines for the treatment of CCC are the same as those used for high-grade serous carcinoma.

Keywords: Ovary; Clear cells; Carcinoma; Surgery; Chemotherapy

Introduction

Epithelial carcinomas of the ovary can be grouped into five histological subtypes, which differ in their histopathological characteristics and molecular pathogenesis. Its histological types are: High-grade serous, endometrioid, Clear-Cell (CCC), mucinous and low-grade serous carcinomas [1]. Clear-Cell Carcinoma (CCC) is a rare malignant tumor of the ovary. Women diagnosed with clear cell carcinomas are generally younger, diagnosed at earlier stages than those with high-grade serous histological types [2]. The aim of this work is to analyze the epidemiological characteristics, clinical, evolutionary and therapeutic outcomes, through a case study of histologically confirmed clear-cell carcinoma of the ovary managed at the Aile 8 gynecology department of Casablanca University Hospital.

Results

The patient, a 50-year-old mother of two children by vaginal delivery with no personal history of pathology, had consulted for abdominal distension with chronic pelvic pain of the heaviness type for 6 months, with no urinary or digestive signs, all evolving in a context of conservation of general condition.

Initial clinical examination revealed a distended abdomen with no other associated signs, and an unremarkable gynaecological examination. Pelvic ultrasound revealed a left ovarian cyst with endophytic vegetations and an effusion layer. The rest of the ultrasound examination was unremarkable (Figure 1).

Abdominal-pelvic CT scan revealed an abdominal-pelvic mass of probable left ovarian origin, with a fleshy portion enhanced by contrast medium and calcifications. The mass measured 14 in long axis, reaching inferiorly and posteriorly intimate contact with the uterine body with no separating line, and inferiorly in contact with the bladder with no sign of invasion.

The cervico-uterine smear was without abnormality. Tumour markers showed CA125 at 100 IU/ml. Surgical exploration initially revealed a 13 cm solid cystic mass over the left ovary. A left adnexectomy was performed with multiple peritoneal and epiploic biopsies. Post-operative management was straightforward.

The anatomopathological result of the left adnexectomy showed a clear-cell carcinomatous proliferation of the ovary, while the epiploic and peritoneal biopsies showed no sign of malignancy.

The patient was rescheduled for total hysterectomy with right adnexectomy, infragastric omentectomy, peritoneal biopsy and ascites sampling (Figure 2).

The final results of the total hysterectomy and right adnexectomy showed no signs of malignancy, while the omentectomy and peritoneal biopsy showed atypical clear-cell glandular structures with congestive and fibroinflammatory changes and the peritoneal cytology showed clusters of atypical cells.

Discussion

Clear cell carcinoma of the ovary is a rare histological type distinct from epithelial carcinomas of the ovary often associated with endometriosis. Endometriosis is considered a major risk factor for the development of clear cell carcinoma of the ovary, and can be considered a precursor of this tumor, as it is identified in over 50% of patients with clear cell carcinoma [2-6].

Clear cell carcinoma of the ovary accounts for around 10% of all ovarian carcinomas, with incidence ranging from 5 to 25% depending

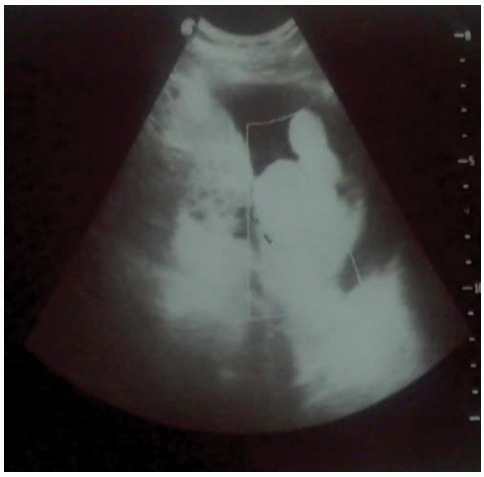

Figure 1: Ultrasound image of a left ovarian cyst with endophytic vegetations and an effusion layer.

Citation: FZ El Hachami, Sabiri R, Imami Y, Berrehili H, Gotni A, Boufettal H, et al. Clear Cell Carcinoma of the Ovary: A Case Report. Am J Surg Case Rep. 2024;5(1):1113.

Publisher Name: Medtext Publications LLC

Manuscript compiled: Jan 31st, 2024

***Corresponding author:** Fatim Zohra El Hachami, Department of Obstetrics and Gynaecology, CHU Ibn Rochd Casablanca, Morocco

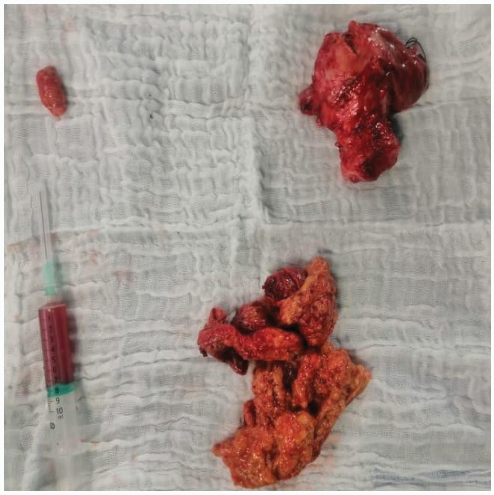

Figure 2: Surgical specimens for total hysterectomy, right adnexectomy, omentectomy, peritoneal biopsy and peritoneal cytology.

on geographic location, ethnic and/or racial factors. The highest incidence of ovarian CCC has been observed in Asian women [3]. Patients with BCC are younger and more often at an earlier stage of diagnosis than those with serous carcinoma of the ovary.

The mean age at diagnosis ranges from 50.2 to 55.7 years, and FIGO stage is I in 45.0%-78.0%, II in 9.6%-15.1%, III in 8.9%-35.2% and IV in 1.9%-11.5% of cases, respectively [7].

Different molecular pathways and alterations have been identified in clear cell ovarian carcinoma compared to other epithelial subtypes of ovarian carcinoma including:

- Cooperation between concomitant mutations in ARID1A and PIK3CA via interleukins 6 and 5.
- Histones (HDAC 6/7) that modify chromatin, resulting in altered apoptosis, mitosis, migration and angiogenesis.
- Cytoplasmic expression of HDAC 6 correlated positively with two ligands: PD-L 1, involved in programmed death, and CD44, involved in the maintenance of cancer stem cell phenotype [1,2,5,6,8-10].

Clinically, patients with ovarian BCC usually present with pelvic or abdominal symptomatology.

Radiologically: Ultrasound, CT and Magnetic Resonance Imaging (MRI) are the most sensitive imaging techniques for detecting and characterizing ovarian tumors [11]. These ovarian masses are unilateral in over 90% of cases, which are generally large in size, up to 30 cm in diameter, with an average of 13 cm to 15 cm [12,13].

Paraneoplastic syndromes as well as thromboembolic events, such as venous thrombosis, pulmonary embolism or cerebral infarction, hypercalcemia, QT interval shortening and cardiac arrhythmias have been described can also be part of the symptoms of ovarian CCC [5,14].

Biologically, the serum marker CA-125 is elevated in 78.9% to 87% of patients with ovarian CCC [15]. The prognosis is good for patients with early-stage ovarian BCC, whereas patients diagnosed at an advanced stage have a poor prognosis [16].

The therapeutic strategy of standard early-stage ovarian surgical treatment consists of aggressive cytoreductive surgery based on bilateral salpingo-oophorectomy with hysterectomy, peritoneal lavage, peritoneal biopsies, infracolic omentectomy and bilateral pelvic and para-aortic lymphadenectomy with adjuvant platinum-based chemotherapy [17].

In terms of chemotherapy, several studies have demonstrated the chemoresistance of clear cell carcinoma of the ovary, given the involvement of HNF-1b, a transcription factor that regulates the expression of several genes specific to this histology, such as dipeptidyl peptidase IV, involved in glycogen synthesis, which plays multiple roles in carcinogenesis and chemoresistance via the alteration of glycolytic processes and oxidative phosphorylation [2,9,10,18].

Several retrospective studies suggest that adjuvant chemotherapy has limited benefit in patients with stage I ovarian BCC, while the role of radiotherapy is controversial depending on the stage and progression of the disease [2].

Conclusion

Clear cell carcinoma of the ovary is a rare and distinct histological type of epithelial carcinoma of the ovary. Several studies have identified the molecular alterations that make this type of cancer chemo-resistant. Despite its bad prognosis in the advanced stages, its therapeutic management is in line with the protocol used for high-grade serous carcinoma.

References

1. Prat J, D'Angelo E, Espinosa I. Ovarian carcinomas: at least five different diseases with distinct histological features and molecular genetics. Hum Pathol. 2018;80:11-27.
2. Gadducci A, Multinu F, Cosio S, Carinelli S, Ghioni M, Aletti GD, et al. Clear cell carcinoma of the ovary: Epidemiology, pathological and biological features, treatment options and clinical outcomes. Gynecol Oncol. 2021;162(3):741-50.
3. Kato N, Sato Y, Kamataki A, Fukase M, Uchigasaki S, Kurose A. PIK3CA hot spot mutations and cyclooxygenase-2 expression in ovarian clear cell carcinomas: a close association with stromal features. Hum Pathol. 2019:86:32-7.
4. Jang JYA, Yanaihara N, Pujade-Lauraine E, Mikami Y, Oda K, Bookman M, et al. Update on rare epithelial ovarian cancers: based on the Rare Ovarian Tumors Young Investigator Conference. J Gynecol Oncol. 2017;28(4):e54.
5. Boland JL, Shahbazi D, Wang SE, Shahbazi SZ. Mixed serous and clear cell adenocarcinoma of the ovary presenting with symptomatic hypercalcemia: a case report and clinical considerations. Perm J. 2020;24:19-125.
6. Prat J, D'Angelo E, Espinosa I. Ovarian carcinomas: at least five different diseases with distinct histological features and molecular genetics. Hum Pathol. 2018;80:11-27.
7. Park JY, Kim DY, Suh DS, Kim JH, Kim YM, Kim YT, et al. Significance of Ovarian Endometriosis on the Prognosis of Ovarian Clear Cell Carcinoma. Int J Gynecologic Cancer. 2017.
8. Uno K, Homma S, Satoh T, Nakanishi K, Abe D, Matsumoto K, et al. Tissue factor expression as a possible determinant of thromboembolism in ovarian cancer. Br J Cancer. 2007;96(2):290-5.
9. Kobayashi H, Yamada Y, Kanayama S, Furukawa N, Noguchi T, Haruta S, et al. The role of hepatocyte nuclear factor1beta in the pathogenesis of clear cell carcinoma of the ovary. Int J Gynecol Cancer. 2009;19(3):471-9.
10. Oda K, Hamanishi J, Matsuo K, Hasegawa K. Genomics to immunotherapy of ovarian clear cell carcinoma: unique opportunities for management. Gynecol Oncol. 2018;151(2):381-9.
11. Joo HL, Shin YR, Rha SE, Park CS, Shim DJ, Kim K. Preoperative discrimination of tumour stage in clear cell carcinoma of the ovary using computed tomography and magnetic resonance imaging. Eur J Radiol. 2018:109:19-26.
12. Zhao T, Shao Y, Liu Y, Wang X, Guan L, Lu Y. Endometriosis does not confer improved

prognosis in ovarian clear cell carcinoma: a retrospective study at a single institute. J Ovarian Res. 2018;11(1):53.

13. Pozzati F, Moro F, Pasciuto T, Gallo C, Ciccarone F, Franchi D, et al. Imaging in gynecological disease (14): clinical and ultrasound characteristics of ovarian clear cell carcinoma. Ultrasound Obstet Gynecol. 2018;52(6):792-800.

14. Bai H, Cao D, Yuan F, Sha G, Yang J, Chen J, et al. Prognostic value of endometriosis in patients with stage I ovarian clear cell carcinoma: experiences at three academic institutions. Gynecol Oncol. 2016;143(3):526-31.

15. Bai H, Sha G, Xiao M, Gao H, Cao D, Yang J, et al. The prognostic value of pretreatment CA-125 levels and CA-125 normalization in ovarian clear cell carcinoma: a two-academic-institute study. Oncotarget. 2016;7(13):15566-76.

16. Shu CA, Zhou Q, Jotwani AR, Iasonos A, Leitao MM, Konner JA, et al. Ovarian clear cell carcinoma, outcomes by stage: The MSK experience. Gynecol Oncol. 2015;139(2):236-41.

17. Fujiwara S. Clinical perspectives of rare ovarian tumors: clear cell ovarian cancer. Jpn J Clin Oncol. 2023;53(8):664-72.

18. Chene G. [Endometriosis and ovarian cancer: An old story..]. Gynecol Obstet Fertil. 2016;44(2):77-8.