American Journal of Surgery Case Reports

Clinical Image

Concomitant Ischemic Stroke and Myxomatous Cerebral Aneurysm in Cardiac Myxoma

Praveen Kesav[1], Seby John[2], Prince Thakkar[3], Sabahat Wasti[3], Moncy Thomas DM[1] and Syed Irteza Hussain[2]*

[1]*Department of Neurology, Cleveland Clinic Abu Dhabi, Neurological Institute, UAE*

[2]*Department of Neurology and Neurointerventional Surgery, Cleveland Clinic Abu Dhabi, Neurological Institute, UAE*

[3]*Department of Neuro-rehabilitation, Cleveland Clinic Abu Dhabi, Neurological Institute, UAE*

Abstract

A 26-year-old male with no significant past medical illnesses presented for evaluation of acute onset left sided weakness. Baseline neuroimaging studies revealed acute infarct involving the right MCA territory, with CT Angiogram of the neck and cerebral vessels demonstrating fusiform aneurysm in the left MCA M2/M3 junction with no large vessel occlusion or hemodynamically significant stenosis. Cardiac echocardiogram showed a 2.5 cm × 2.2 cm, heterogenous mass in the left atrium which on resection turned out to be a Cardiac myxoma. Cardiac myxoma, the most common primary cardiac tumour has myriad clinical presentations, with the most common neurological manifestation being ischemic strokes. The latter occurs due to embolization of myxomatous fragments, whereas segmental deposition followed by infiltration of vessel wall contributes to myxomatous aneurysms hitherto rare. Our case demonstrates both the neurological manifestations of Cardiac myxoma namely ischemic stroke and myxomatous aneurysms respectively, which is rarely reported in literature.

Keywords: Cardiac myxoma; Ischemic stroke; Cerebral aneurysm

Clinical Image

A 26-year-old male with no significant past medical illnesses presented for evaluation of acute onset left sided weakness, 12 hours after onset of symptoms. His baseline NIHSS was 13. Baseline NCCT Head followed by MRI Brain revealed acute infarct involving the right MCA territory, with CT Angiogram of the neck and cerebral vessels demonstrating fusiform aneurysm in the left MCA M2/M3 junction with no large vessel occlusion or hemodynamically significant stenosis (Figure 1 A-D). Transthoracic followed by Transesophageal echocardiogram showed a 2.5 cm × 2.2 cm heterogenous mass in the left atrium which on resection turned out to be a Cardiac myxoma (Figure 1 E). In addition to undergoing resection of cardiac myxoma, he was maintained on Aspirin 100 mg once daily and Atorvastatin 40 mg once daily for secondary stroke prophylaxis, with definitive management of the unruptured fusiform aneurysm to be decided on the basis of follow up neuroimaging studies as well as clinical evolution.

Cardiac myxoma, the most common primary cardiac tumour with up to 88%1 arising from the left atrium, occurs twice more commonly in females with age predilection from third to sixth decades [1-4]. They manifest with either constitutional (fever, weight loss, fatigue), cardiac (obstruction of mitral valve) or embolization (cerebral or peripheral) symptoms [1,2]. Intraluminal embolization from cardiac myxoma contributes to ischemic strokes which are by far the most common central nervous system manifestation [1-4]. Myxomatous intracranial aneurysms are much less common, with the possible etiopathogenic mechanism postulated to be "metastasize and infiltrate" theory [2-4]. Myxomatous micro-fragments embolize to cerebral circulation gets deposited in the vessel wall followed by local infiltration in the setting of an inflammatory response generated by the cardiac myxoma [3,4]. Due to its rarity, there are lacks of guidelines in the management of intracranial myxomatous aneurysms, with majority recommending conservative management for unruptured ones [5]. Cardiac myxoma manifesting with ischemic stroke and underlying myxomatous aneurysms as depicted in our index case is rarely reported in literature [4]. Even though rare, a high index of suspicion should be entertained in appropriate clinical scenario for timely diagnosis and prompt surgical treatment of underlying cardiac myxoma due to possibility of devastating consequences including sudden cardiac death.

Citation: Kesav P, John S, Thakkar P, Wasti S, Moncy Thomas DM, Hussain SI. Concomitant Ischemic Stroke and Myxomatous Cerebral Aneurysm in Cardiac Myxoma. Am J Surg Case Rep. 2023;4(3):1063.

Copyright: © 2023 Praveen Kesav

Publisher Name: Medtext Publications LLC

Manuscript compiled: Apr 05th, 2023

***Corresponding author:** Seby John, Staff Physician, Department of Neurology and Neurointerventional Surgery, Neurological Institute, Cleveland Clinic Abu Dhabi, Abu Dhabi, PO Box: 112412, UAE, Tel: +971-2509000; E-mail: JohnS5@clevelandclinicabudhabi.ae

References

1. Lee VH, Connolly HM, Brown RD Jr. Central nervous system manifestations of Cardiac Myxoma. Arch Neurol. 2007;64(8):1115-20.
2. Nucifora PGP, Dillon WP. MR diagnosis of myxomatous aneurysms: report to two cases. AJNR Am J Neuroradiol. 2001;22(7):1349-52.
3. Xu Q, Zhang X, Wu P, Wang M, Zhou Y, Feng Y. Multiple intracranial aneurysms followed left atrial myxoma: case report and literature review. J Thorac Dis. 2013;5(6):E227-31.
4. Kesav P, John S, Joshi P, Gaba WH, Hussain SI. Cardiac myxoma embolization causing ischemic stroke and multiple partially thrombosed cerebral aneurysms. Stroke. 2021;52(1):e10-4.
5. Zheng J, Li S, Cao Y, Wang S, Wang R, Zhao J. Multiple cerebral aneurysms: what is the optimal treatment? J Stroke Cerebrovasc Dis. 2015;24(1):232-8.

© 2023 - Medtext Publications. All Rights Reserved.

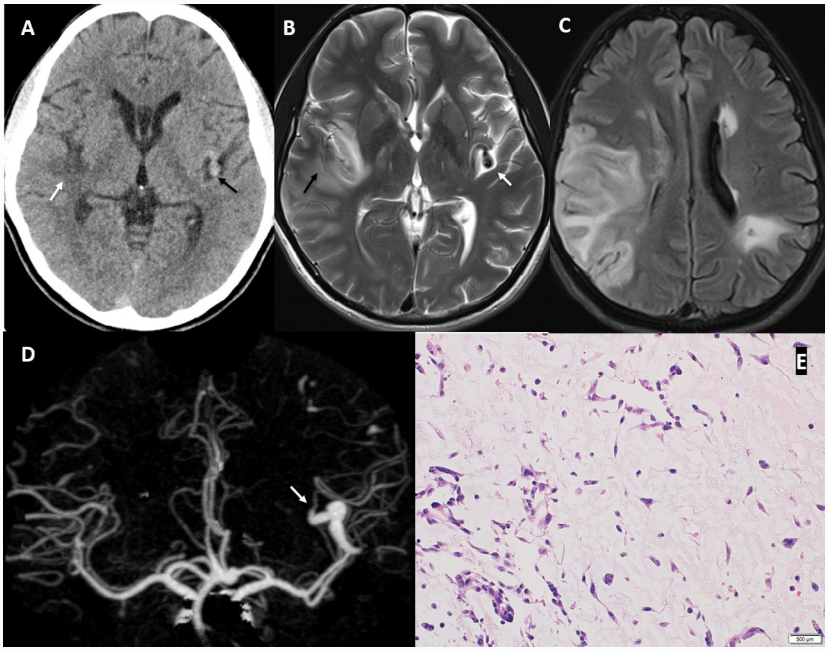

Figure 1: (A). Non-contrast CT Head shows right temporal infarct (white arrow) and hyperdensity in left sylvian fissure (black arrow). MRI Brain T2 and FLAIR axial images show (B). acute right temporal infarct (black arrow), fusiform dilatation of left MCA distal segment (white arrow) and chronic infarcts in left caudate, parietal lobe (C). (D). Reconstructed axial CT Angiogram of cerebral vessels show fusiform aneurysm of left MCA M2/M3 junction (white arrow). (E). Hematoxylin and Eosin staining shows neoplastic polygonal myxoma cells with eosinophilic cytoplasm, indistinct cell borders and oval nucleus within myxoid stroma.

© 2023 - Medtext Publications. All Rights Reserved.