American Journal of Surgery Case Reports

ISSN: 2766-8304

Case Report

Concurrent Robotic-Assisted Pulmonary Lobectomy for Stage-IIIA Right Lung Adenocarcinoma and Robotic-Assisted Paraesophageal Hernia Repair with Nissen Fundoplication

Jobelle J.A.R. Baldonado[1,3,4], David Straughan[3], Sirish Parvathaneni[1], Kenneth L. Meredith[2,3,4] and Eric M. Toloza[1,3,4]*

[1]*Departments of Thoracic Oncology, Moffitt Cancer Center, USA*

[2]*Departments of Gatrointestinal Oncology, Moffitt Cancer Center, USA*

[3]*Departments of Surgery, University of South Florida Health Morsani College of Medicine, USA*

[4]*Departments of Oncologic Sciences, University of South Florida Health Morsani College of Medicine, USA*

Abstract

Introduction: Stage IIIA Non-Small Cell Lung Cancer (NSCLC) is generally treated with induction chemotherapy and radiation therapy, followed by surgery, possibly by minimally invasive approach. Paraesophageal hiatal hernia complicated by gastric volvulus should be surgically repaired, preferably *via* laparoscopy. We describe a case of concurrent robotic-assisted paraesophageal hernia repair with Nissen fundoplication and robotic-assisted pulmonary lobectomy.

Case: A 64-year-old diabetic smoker was diagnosed with 6.3 cm Right Upper Lobe (RUL) lung mass, with enlarged hilar and subcarinal Lymph Nodes (LNs), but without distant metastasis. Needle biopsies of the RUL lung mass and para-azygous LNs revealed CK7-positive/TTF1-positive adenocarcinoma, confirming stage-IIIA disease. Gastric volvulus, complicating his paraesophageal hernia, was treated non-surgically prior to chemoradiation. He then underwent induction carboplatin/paclitaxel chemotherapy, with concurrent 50-Gy external beam Radiation Therapy (XRT). Robotic-assisted laparoscopic crurapexy and Nissen fundoplication were done. Under the same anesthetic, he underwent robotic-assisted video-thoracoscopic RUL lobectomy and mediastinal LN dissection. Total operative (skin-to-skin) time was 545 min, with 341 min for paraesophageal hernia repair and 204 min for lobectomy, with estimated blood loss of 360 mL Postoperative course was complicated by pulmonary embolus on Postoperative Day (POD) #3, atrial fibrillation with rapid ventricular rate on POD#5, dysphagia requiring repeated swallow evaluations and slow advance to regular diet, prolonged air leak, and enlarging right pneumothorax after chest tube removal, requiring CT-guided right pleural pigtail catheter. Pathology revealed 4 cm poorly-differentiated carcinoma, 99% necrotic or fibrotic, with all 13 hilar and mediastinal LNs uninvolved by NSCLC. On POD#17, he was discharged home on therapeutic dalteparin, with pigtail catheter connected to Pneumostat valve, removed on POD#26. He survived for 7.2 years postoperatively.

Discussion: Robotic-assisted paraesophageal hernia repair with Nissen fundoplication and robotic-assisted pulmonary lobectomy have each been reported as feasible and safe, but both procedures under the same anesthesia has not been reported. Our patient's comorbidities and induction chemotherapy-XRT likely contributed to postoperative complications, but he successfully underwent these 2 complex procedures.

Conclusion: We report the first known concurrent robotic-assisted paraesophageal hernia repair with Nissen fundoplication and robotic-assisted pulmonary lobectomy, with long-term survival. Combined complex abdominal and thoracic robotic-assisted operations are feasible and safe.

Keywords: Robotic-assisted surgery; Pulmonary lobectomy; Lung cancer; Paraesophageal hernia; Hiatal hernia; Nissen fundoplication

Introduction

Minimally invasive approaches to lung cancer resections have become standard of care especially for early-stage disease. For locally advanced non-small cell lung cancer, however, patients receive neoadjuvant chemoradiotherapy followed by resection, possibly through minimally invasive means. Symptomatic or giant hiatal hernias also require repair, and laparoscopy is standard of care. These minimally invasive approaches in general intend to decrease perioperative risks and improve perioperative outcomes.

We describe here a case of a patient with locally advanced lung cancer with giant hiatal hernia and who successfully underwent the first report of robotic-assisted resection of lung cancer and concomitant robotic-assisted repair of hernia.

Case Presentation

A 64-year-old diabetic man, with 160-pack-year smoking history, was diagnosed with 6.3 cm Right Upper Lobe (RUL) lung mass, with enlarged hilar and subcarinal Lymph Nodes (LNs). PET/CT revealed increased FDG avidity in the RUL mass as well as the right hilar

Citation: Jobelle J.A.R. Baldonado, Straughan D, Parvathaneni S, Meredith KL, Toloza EM. Concurrent Robotic-Assisted Pulmonary Lobectomy for Stage-IIIA Right Lung Adenocarcinoma and Robotic-Assisted Paraesophageal Hernia Repair with Nissen Fundoplication. Am J Surg Case Rep. 2021;1(1):1005.

Publisher Name: Medtext Publications LLC

Manuscript compiled: Jan 18th, 2021

***Corresponding author:** Eric M. Toloza, Departments of Thoracic Oncology, Moffitt Cancer Center, 12902 USF Magnolia Drive, Suite CSB-6, Tampa, FL 33612, USA. Tel: +813-745-6895; Fax: +813-449-8446; E-mail: eric.toloza@moffitt.org

lymph node, but without distant metastasis. Needle biopsies of the RUL lung mass and para-azygous lymph node revealed Cytokeratin-7 (CK7)-positive, Thyroid Transcription Factor-1 (TTF1)-positive adenocarcinoma, confirming stage-IIIA non-small cell lung cancer. The patient was referred for neoadjuvant chemoradiotherapy (Figure 1).

Figure 1: Axial image from preoperative chest Computerized Tomography (CT) scan with intravenous contrast (upper panel) and axial Positron-Emission Tomography (PET) (middle panel) and CT scan (lower panel) images from preoperative PET-CT scan each showing the right upper lobar lung mass (arrows).

However, prior to initiation, he was hospitalized for incarceration gastric volvulus through the paraesophageal hiatal hernia, which was treated non-surgically with bowel rest and nasogastric tube decompression, but which delayed the induction treatment.

He eventually underwent induction carboplatin/paclitaxel chemotherapy for seven weeks, with concurrent 50-Gy external-beam Radiation Therapy (XRT) to the RUL and mediastinum. A follow-up chest CT scan showed that both his RUL mass and right hilar LN have decreased in size after chemoradiation. The RUL lung mass decreased to 5.4 cm, while the hilar LN decreased from 2.5 cm to 2.0 cm. He was then referred for surgical resection. Considering that he had been suffering from gastroesophageal reflux disease since age 17 due to a hiatal hernia, as well as the recent hospitalization for incarcerated gastric volvulus, it was decided that he would undergo a concomitant operation to repair his giant hiatal hernia (Figure 2).

The operation began with a laparoscopic reduction of paraesophageal hernia and resection of hiatal hernia sac, followed by robotic-assisted crurapexy and Nissen fundoplication. A Hasson port was placed through a 12 mm incision 6 cm superior to the umbilicus. After the abdomen was insufflated with CO_2 to an intraperitoneal pressure of 15 mmHg, additional port sites were placed, including an

Figure 2: Axial and coronal images from preoperative CT scan showing the paraesophageal hiatal hernia (arrows).

8 mm port site at the costal margin in the right midclavicular line, 8 mm right paramedian port incision, two 8 mm left subcostal port incisions, as well as a 5 mm subxiphoid incision for a Nathanson liver retractor. The hiatal hernia, which contained the stomach, omentum, and small intestine, was reduced, and the hernia sac was excised. The short gastric vessels were taken down using the Harmonic scalpel up to the left crura of the diaphragm. After the pars flaccida was incised, a posterior window was created, and the daVinci® "Si™" robotic patient cart (Intuitive Surgical Corp.; Sunnyvale, CA, USA) was docked to the patient. A crurapexy was then performed, followed by a Nissen fundoplication (Figure 3).

The thoracic portion of the case was then undertaken using the robotic approach as well. A 4.5 cm incision was made in the 6th Inter Costal Space (ICS) at the anterior axillary line. Other port incisions were made, including a 1 cm incision in the 3rd ICS at the anterior axillary line and a 1.5 cm incision in the 9th ICS at the posterior axillary line. Attention was then turned to the hilum, where the pulmonary veins and arteries supplying the right upper lobe were identified, dissected free from surrounding structures, and ligated and divided using a linear endostapler with vascular stapler loads. The same procedure was undertaken with the right upper lobe bronchus; although, a tissue stapler load was used. Meanwhile, level 10R and level 11R lymph nodes were sent to pathology. The horizontal fissures, along with the superior portion of the oblique fissure were completed by serial application of another linear endostapler. The right upper lobectomy was then delivered through the 6th ICS port incision using an endopouch. Calcified lung nodules were noted in the right middle lobe and the superior segment of the right lower lobe, and these were

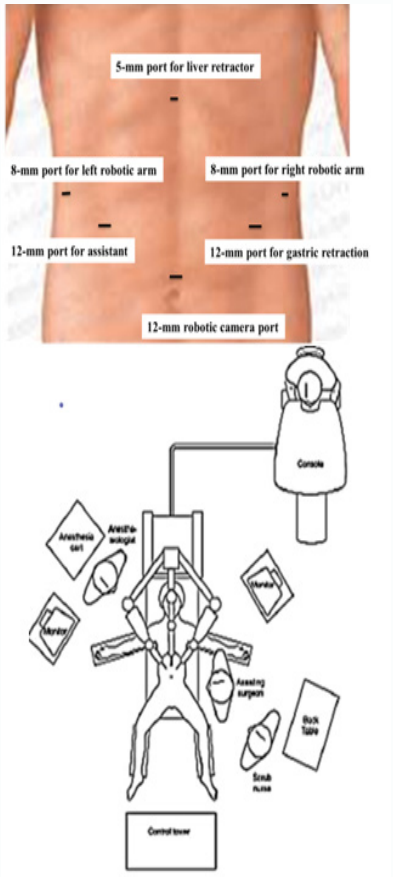

Figure 3: Abdominal port placement for robotic-assisted laparoscopic portion of the procedure (upper panel), and illustration of operating room layout (lower panel) showing relationship of the robotic patient cart with the operating table.

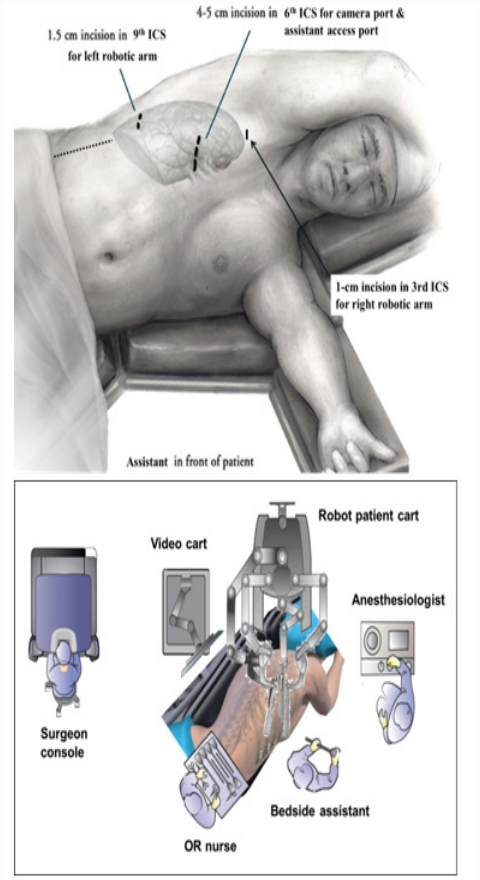

Figure 4: Right thoracic port placement for robotic-assisted video-thoracoscopic portion of the procedure (upper panel), and illustration of operating room layout (lower panel) showing relationship of the robotic patient cart with the operating table.

each removed within wedge resections performed by serial application of the linear endostapler. Levels 2R, 4R, and 7 lymph nodes were each dissected free and sent to pathology. The inferior pulmonary ligament was then divided, and level 9R lymph nodes were dissected free and sent to pathology. A second right lower lobe superior segmental lung nodule was then identified and removed within another wedge resection. Hemostasis was confirmed, and incisions were closed (Figure 4).

Total operative duration was 545 minutes, with 341 minutes for paraesophageal hernia repair and 204 minutes for the right upper lobectomy, with total estimated blood loss of 360 mL. The postoperative course was complicated by pulmonary embolus on Post Operative Day (POD) #3, atrial fibrillation with rapid ventricular rate on POD#5, dysphagia requiring repeated swallow evaluations and slow advance to regular diet, prolonged air leak, and enlarging right pneumothorax after chest tube removal, requiring CT-guided right pleural pigtail catheter. On POD#17, he was discharged home on therapeutic dalteparin, with pigtail catheter connected to Pneumostat valve, removed on POD#26.

Final pathology revealed a 4 cm RUL poorly-differentiated carcinoma, 99% necrotic or fibrotic, with one (level 4R) of 14 hilar and mediastinal LNs involved by NSCLC. He survived for 7.2 years postoperatively and died of unspecified causes.

Discussion

Paraesophageal Hernias (PEH), demonstrate increased incidence with advancing age. With progressive weakening of the phreno-esophageal membrane and enlargement of the hiatus, the gastroesophageal junction and a part of the stomach become displaced, ending up above the diaphragm [1]. Because of this abnormal location, patients typically present with heartburn, regurgitation, postprandial fullness, and dysphagia and/or chest pain. Our patient specifically presented with chronic regurgitation managed medically, followed by chest pain and incarceration, which was also managed conservatively. In a study published by Sihvo et al. [2] 16.4% of patients, who are hospitalized for symptomatic PEH and treated conservatively, die within a mean of 42 months. This usually results from complications, such as obstruction, strangulation, perforation, and bleeding, hence the need to surgically intervene as soon as patient becomes symptomatic from PEH. The tendency to manage conservatively for many years often lead to a fairly large hernia and, therefore, a potentially challenging reduction and resection of hernia sac as well as repair of a large hiatal defect.

Laparoscopic repair of PEH has become the standard of care in place of traditional open repair. One large series of laparoscopic repair of PEH showed minimal complication rate, a 2-day hospital length of stay, and reasonable intermediate results [3]. However, another video-assisted approach is being increasingly utilized in the recent years-robotic-assisted repair.

The internally articulating arms, fine instrumentation, three-dimensional imaging, and improved ergonomics and maneuverability all favor the use of robotic-assisted surgery over conventional laparoscopic or thoracoscopic approaches to complex thoracic and upper gastrointestinal surgery. In 2011, Schraibman reported on use of robotic surgery for 21 patients with GERD [4]. These patients had to have some kind of co-morbidity to be included in the case series, such as a previous major upper abdominal surgery, the presence of a giant hiatal hernia, or a BMI of >30 kg/m^2. As there were no complications and operative duration progressively improved over time, the conclusion was made that robotic-assisted fundoplication seems to have an equivalent safety and feasibility profile compared to the conventional laparoscopic technique, and may even offer advantages over the alternative for complex cases, such as redo surgeries and giant hernias. Morelli and colleagues prospectively analyzed six patients with giant hiatal hernias, for whom they did robotic-assisted repair, and noted favorable outcomes over three years. Not one required reoperation for recurrence, and all six claimed absence of symptoms postoperatively [5,6]. Another case series comparing equal cases of robotic-assisted and laparoscopic fundoplication demonstrated longer operative time but better short-term functional outcome in the robotic group compared to laparoscopic group. This is attributed to the improved dissection within the esophageal hiatus. The complications and hospital length of stay were similar [6]. There was also a systematic review of randomized controlled trials showing that both robotic-assisted and laparoscopic fundoplication were similar in duration of hiatal dissection, conversion to open surgery, intraoperative complications, total operative duration, hospital length of stay, total cost, postoperative anti-secretory medication, and postoperative dysphagia [7].

As opposed to hiatal hernia repair, robotic-assisted pulmonary lobectomy has been gaining much attention in the recent years. In a recent systematic review and network meta-analysis, minimally invasive thoracic surgery, including both thoracoscopic and robotic-assisted technologies, had reduced 30-day mortality, reduced pulmonary and overall complication rates, and similar 5-year overall survival when compared with open lobectomy [8,9]. Robotic-assisted surgery offers some promising short-term quality metrics for oncologic resections, such as the number of lymph nodes resected and stations sampled less blood loss and consequent transfusions, conversion to thoracotomy, R0 resection rates, hospital length of stay, and readmission rates [10-12]. With regard to long-term quality metrics, Cerfolio and colleagues reported on promising stage-specific outcomes for >1300 robotic lobectomies done at 4 institutions; although, the median follow-up was only 30 months. For stage-IIIA disease, for instance, the 5-year survival in their retrospective review was 62% [13].

The case presented is the first to be ever written in the literature for concurrent robotic-assisted pulmonary lobectomy and PEH repair. Robotic-assisted hiatal hernia repair with fundoplication and robotic-assisted pulmonary lobectomy have each been reported as safe, feasible, and effective, but doing both procedures under the same anesthesia has not been reported. Understandably, operative duration is prolonged, and cost will be an issue, but the fact remains that this case utilizes only one bout of anesthesia and, hence, one post-anesthesia recovery for the patient.

Our patient's comorbidities and induction chemoradiotherapy likely contributed to postoperative complications, although one can argue that the prolonged operative duration may also be contributory. The operative duration will certainly improve with time, considering that this is the first case recorded. This minimally invasive, robotic-assisted approach facilitated both surgical resection of a locally advanced lung cancer and PEH repair concurrently in a patient who otherwise would have require staged procedures, which would possibly delay any additional therapy for the locally advanced lung cancer. Doing the two procedures concurrently also avoids the possibility of patients refusing the subsequent, equally necessary staged second surgery and also avoids incurring additional costs of a second admission for the hernia surgery or for additional hospitalizations from complications of an unrepaired PEH, such as gastric volvulus after pulmonary lobectomy.

Conclusion

We report here the successful completion of a concurrent robotic-assisted pulmonary lobectomy and robotic-assisted hiatal hernia repair with Nissen fundoplication for a patient with stage-IIIA lung cancer and paraesophageal hernia. While his postoperative course was not without complications, this case demonstrates that concomitant thoracic and abdominal robotic-assisted operations can be performed on patients with multiple comorbidities safely and effectively.

Acknowledgements

This case report was presented in part at the Inaugural Asian Congress of Robotic Surgery in Hong Kong in December 2015, at the 2016 Annual Meeting &Scientific Session of the Society of American Gastrointestinal and Endoscopic Surgeons (SAGES) in Boston, MA, USA, in March 2016, and at the Chest World Congress 2016 in Shanghai, China, in April 2016.

We gratefully acknowledge Joseph R. Garrett MPH ARNP-C, Carla C. Moodie PA-C, Jonathan Hernandez MD, Maki Yamamoto MD, and Tannous Fakhry MD for their assistance with the care of this patient.

Informed Consent: Permission was obtained from the patient for publication of this case report and any accompanying images for education purposes as part of our institutional surgical informed consent. A copy of the written consent is available for review by the Editor-in-Chief of this journal.

Conflict-of-Interest (COI) Disclosures

K.L.M. and E.M.T. have had financial relationships with Intuitive Surgical Inc. in the form of honoraria as robotic thoracic surgery proctors and observation sites. K.L.M. is currently Medical Director for Gastrointestinal Surgical Oncology at Sarasota Memorial Hospital, Sarasota, FL, USA. None of the other authors have any COI to disclose.

Provenance and Peer Review

Not commissioned, externally peer-reviewed.

References

1. Gangopadhyay N, Perrone J, Soper N, Matthews B, Eagon C, Klingensmith M, et al. Outcomes of Laparoscopic Paraesophageal Hernia Repair in Elderly and High-risk patients. Surgery. 2006;140(4):491-9.

2. Sihvo E, Salo J, Rasanen J, Rantanen T. Fatal Complications of Adult Paraesophageal Hernia: A Population-based study. J Thorac Cardiovasc Surg. 2009;137(2):419-24.

3. Luketitch J, Raja S, Fernando H, Campbell W, Christie N, Buenaventura P, et al. Laparoscopic Repair of Giant Paraesophageal Hernia: 100 Consecutive Cases. Ann Surg. 2000;232(4):608-18.

4. Schraibman V, Macedo ALDV, Okazaki S, Mauro FC, Epstein MG, Goldman SM, et al. Surgical Treatment of Hiatus Hernia and Gastroesophageal Reflux Disease in

Complex Cases using Robotic-assisted Laparoscopic Surgery: A Prospective Study/ consistent Experience in a Single Institution. J Robotic Surg. 2011:5(1):29-33.

5. Morelli L, Guadagni S, Mariniello MD, Pisano R, D'Isidoro C, Belluomini MA, et al. Robotic Giant Hiatal Hernia Repair: 3 Year Prospective Evaluation and Review of Literature. Int J Med Robot. 2015;11(1):1-7.

6. Melvin WS, Needleman BJ, Krause KR, Schneider C, Ellison EC. Computer-enhanced *vs.* standard laparoscopic antireflux surgery. J Gastrointest Surg. 2002;6(1):11-5.

7. Zhang P, Tian JH, Yang KH, Li J, Jia WQ, Sun SL, et al. Robot-assisted Laparoscope Fundoplication for Gastroesophageal Reflux Disease: A Systematic Review of Randomized Controlled Trials. Digestion. 2010;81(1):1-9.

8. Sesti J, Langan RC, Bell J, Nguyen A, Turner AL, Hilden P, et al. A Comparative Analysis of Long-Term Survival of Robotic *Versus* Thoracoscopic Lobectomy. Ann Thorac Surg. 2020;110(4):1139-46.

9. Aiolfi A, Nosotti M, Micheletto G, Khor D, Bonitta G, Perali C, et al. Pulmonary lobectomy for cancer: Systematic review and network meta-analysis comparing open, video-assisted thoracic surgery, and robotic approach. Surgery. 2020:S0039-6060(20)30613-9.

10. Farivar AS, Cerfolio RJ, Vallières E, Knight AW, Bryant A, Lingala V, et al. Comparing robotic lung resection with thoracotomy and video-assisted thoracoscopic surgery cases entered into the Society of Thoracic Surgeons Database. Innovations (Phila). 2014;9(1):10-5.

11. Toker A, Özyurtkan MO, Kaba E, Ayalp K, Demirhan Ö, Uyumaz E. Robotic anatomic lung resections: the initial experience and description of learning in 102 cases. Surg Endosc. 2016;30(2):676-83.

12. Veronesi G. Robotic lobectomy and segmentectomy for lung cancer: results and operating technique. J Thorac Dis. 2015; 7(suppl 2):S122-30.

13. Cerfolio RJ, Ghanim A, Dylewski M, Veronesi G, Spaggiari L, Park BJ. The Long-term Survival of Robotic Lobectomy for Non-Small Cell Lung Cancer: A Multi-institutional Study. J Thorac Cardiovasc Surg. 2018;155(2):778-86.