American Journal of Surgery Case Reports

ISSN: 2766-8304

Case Report

Concurrent Robotic-Assisted Right Upper Lobectomy for Lung Cancer and Robotic-Assisted Excision of Esophageal Leiomyoma: A Case Report

*Indira T. Ranaweera[6], Farah Khalil[1,3,5], Jobelle J.A.R. Baldonado[1,4,5], Kenneth L. Meredith[2,4,5] and Eric M. Toloza[1,4,5]**

[1]Departments of Thoracic Oncology, Moffitt Cancer Center, USA

[2]Department of Gastrointestinal Oncology, Moffitt Cancer Center, USA

[3]Department of Pathology, Moffitt Cancer Center, USA

[4]Departments of Surgery, University of South Florida Health Morsani College of Medicine, USA

[5]Department of Oncologic Sciences, University of South Florida Health Morsani College of Medicine, USA

[6]University of South Florida Health Morsani College of Medicine, USA

Abstract

Stage-I Non-Small Cell Lung Cancer (NSCLC) and esophageal leiomyomas are both primarily treated by surgical resection, preferably with Minimally Invasive Surgery (MIS). We present a case of a 41-year-old woman with a 6-pack-year tobacco history and a father who had lung cancer in his 30s. The patient presented with a 2 cm Right Upper Lobe (RUL) lung Adenocarcinoma consistent with NSCLC and an esophageal leiomyoma within the upper esophageal wall. A combined Robotic-Assisted Video-Thoracoscopic (RAVT) right upper lobectomy and RAVT excision of esophageal leiomyoma was performed. This combined surgery demonstrates the usefulness of RAVT surgery and its potential for combined procedures involving different surgical fields.

Keywords: Robotic surgery; Pulmonary lobectomy; Lung cancer; Esophageal leiomyoma

Introduction

Stage-I Non-Small Cell Lung Cancer (NSCLC) is primarily treated by surgical resection with systematic mediastinal lymph node dissection, preferably *via* Minimally-Invasive Surgery (MIS) [1]. After surgical resection, the prognosis for stage-1 NSCLC is reported to range from 60% to 80% [1]. Pulmonary lobectomy *via* Video-Assisted Thoracoscopic (VATS) surgery, a form of MIS, has been demonstrated to have fewer complications, lower operative mortality, shorter hospital length of stay, and at least equivalent long-term survival as open lobectomy via traditional thoracotomy [1].

Symptomatic esophageal leiomyomas are also primarily treated via surgical resection, preferably *via* MIS as well. With MIS, patients undergoing esophageal leiomyoma excision benefit from limited operative trauma, less postoperative pain, shorter hospital Length of Stay (LOS), and better wound cosmetics, as compared to open thoracotomy [2]. Traditional open thoracotomy for esophageal leiomyoma excision is being gradually replaced with the minimally invasive thoracoscopic approach, which has been found to be safe and effective, especially for tumors smaller than 5 cm and those located in the upper two-thirds of the esophagus [3].

Robotic-Assisted Video-Thoracoscopic (RAVT) surgery, in particular, overcomes the limitations of routine open thoracotomy by allowing ease of movement, limited operative trauma, shorter postoperative recovery, and reduced morbidity [4,5]. We report the first known case of a combined robotic-assisted pulmonary lobectomy NSCLC with robotic-assisted excision of esophageal leiomyoma.

Case Presentation

The patient is a 41-year-old woman with a 6-pack-year tobacco history and a father who had lung cancer in his 30's. She presented to the thoracic surgery clinic with bilateral lower extremity weakness, dizziness, and nausea. Subsequent workup with a chest x-ray revealed that she had a Right Upper Lobe (RUL) lung mass. Computerized Tomography (CT) scan of the thorax confirmed a 2 cm RUL lung mass with no hilar or mediastinal lymphadenopathy (Figure 1). Transbronchial biopsies of the lung revealed CK7-positive, TTF1-positive moderately-differentiated Adenocarcinoma, consistent with primary NSCLC, clinically stage-I.

On preoperative review of symptoms, she complained of dysphagia to liquids and solids. Preoperative Positron-Emission Tomography (PET) scan revealed the RUL lung mass to be PET-positive, with maximum Standardized Uptake Value (SUV) 3.3, as well as a PET-negative nodule within the upper esophageal wall (Figure 2). The patient subsequently underwent RAVT right upper lobectomy, with Mediastinal Lymph Node Dissection (MLND), performed in left

Citation: Ranaweera IT, Khalil F, Jobelle J.A.R. Baldonado, Meredith-KL, Toloza EM. Concurrent Robotic-Assisted Right Upper Lobectomy for Lung Cancer and Robotic-Assisted Excision of Esophageal Leiomyoma: A Case Report. Am J Surg Case Rep. 2021;2(1):1006.

Publisher Name: Medtext Publications LLC

Manuscript compiled: Jan 18th, 2021

***Corresponding author:** Eric M. Toloza, Departments of Thoracic Oncology, Moffitt Cancer Center, 12902 USF Magnolia Drive, Suite CSB-6, Tampa, FL 33612, USA. Tel: +813-745-6895; Fax: +813-449-8446; E-mail: eric.toloza@moffitt.org

Figure 1: Computerized Tomography (CT) scan axial image showing a 2 cm right upper lobe lung mass *via* lung window (top panel) and an esophageal mass *via* mediastinal window (bottom panel).

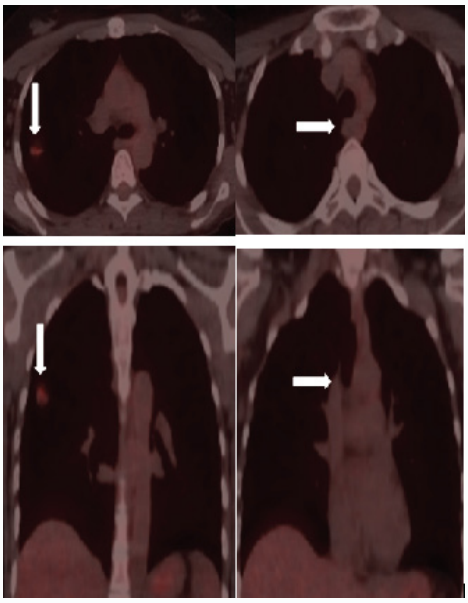

Figure 2: Positron-Emission Tomography (PET)-CT scan axial fusion images showing Fluoro-Deoxy-Glucose (FDG)-avid right upper lobe lung mass (left upper panel) and FDG-negative (right upper panel). PET-CT scan coronal fusion images showing FDG-avid right upper lobe mass (left lower panel) and FDG-negative esophageal mass (right lower panel).

lateral decubitus *via* 3 thoracoscopy ports, including a 4 cm camera port along the 6th Inter Costal Space (ICS) at the anterior axillary line, which doubled as the assistant's access port, a 1 cm instrument port along the 3rd ICS at the anterior axillary line, and another 1 cm instrument port along the 9th ICS at the posterior axillary line (Figure 3).

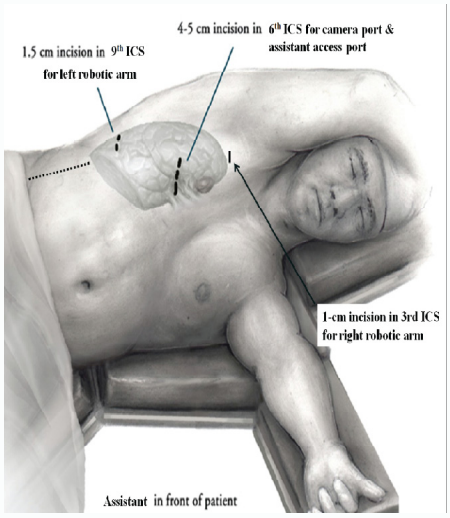

Figure 3: Port sites for combined robotic-assisted right upper lobectomy and robotic-assisted excision of esophageal leiomyoma.

Attention was then directed to the anterior hilar area, where dissection and isolation of the RUL branches of the right superior pulmonary vein and of the pulmonary artery were performed. These were divided using a linear endostapler using vascular stapler loads. The RUL bronchus was also divided using a linear endostapler. Serial application of linear endostapler to the horizontal fissure and to the superior portion of the oblique fissure then followed, completing the right upper lobectomy. A systematic Mediastinal Lymph Node Dissection (MLND) then followed, with levels 2R, 4R, 7, and 9 all being sent for pathology.

After the right upper lobectomy and MLND, the patient underwent, through the same thoracoscopy ports, a concurrent RAVT excision of what appeared grossly to be a 1.5 cm esophageal leiomyoma, which was confirmed on frozen section. The esophageal wall musculature was subsequently closed with interrupted 3-0 silk sutures over an intact esophageal mucosa, which was confirmed by upper endoscopic visualization and endoluminal air insufflation, with the repair suture line covered within the pleural cavity with sterile water irrigation revealing no air leak from the esophagus. The mediastinal pleura were ultimately closed with 4-0 PDS suture over the esophageal muscle suture line.

There were no intraoperative complications. Total operative (skin-to-skin) time was 275 min. Total intraoperative estimated blood loss was 125 mL.

Esophagram on postoperative day (POD)#1 revealed no evidence of esophageal leak, but showed delayed gastric emptying, although she was able to advance to regular diet by POD#2. She did develop a urinary tract infection, for which oral sulfamethoxazole/trimethoprim was started on POD#3. Her chest tube was removed on POD#4, at which time she was discharged to home.

Final pathology revealed a 1.5 cm moderately-differentiated right upper lobe Adenocarcinoma, with negative margins and 11 negative

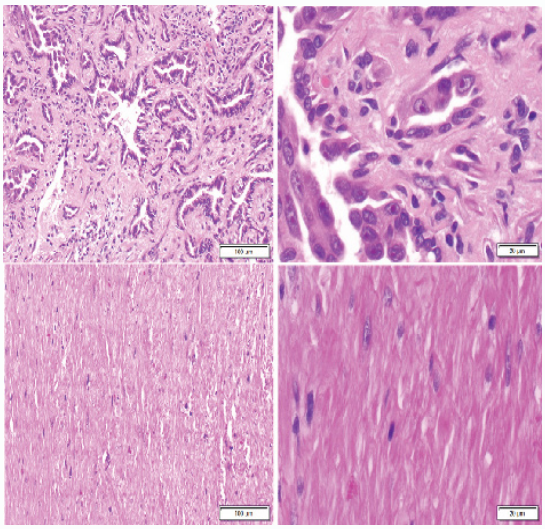

Figure 4: Photomicrographs of right lung cancer (Hematoxylin & Eosin [H&E] stained) at low power (upper left panel) and at high power (upper right panel) and of esophageal leiomyoma (H&E stained) at low power (lower left panel) and at high power (lower right panel).

interlobar, hilar, and mediastinal lymph nodes (T1aN0M0), as well as the 2.5 cm esophageal leiomyoma. The lung Adenocarcinoma was immunohistochemically positive for CK7 and TTF-1, consistent with lung primary. The spindle cells comprising the leiomyoma were immunohistochemically positive for actin, desmin, smooth muscle myosin, and vimentin and negative for AE1/AE3 and CAMS.2. Manual morphometric analysis of Ki-67 showed approximately 1% tumor cells positive. Throughout 8.4 years of postoperative lung cancer surveillance with serial chest CT scans, she has had no evidence of recurrent or metastatic lung cancer and has had no further complaints of dysphagia.

Discussion

Stage-I primary lung cancers are generally cured by surgical resection, and symptomatic esophageal leiomyomas are also generally treated by surgical excision. In both situations, patients benefit from MIS over surgery via open thoracotomy. While VATS and RAVT surgery are both used in MIS, RAVT lobectomy has been shown to significantly reduce the mortality rate when compared with VATS lobectomy, and perioperative morbidity of RAVT lobectomy is similar to that of VATS lobectomy [6]. RAVT lobectomies provide the advantages of decreased perioperative complications, shorter hospital LOS, and more effective MLND compared to VATS lobectomies [7].

Robotic surgical systems also can address some of the limitation of VATS; they provide three-dimensional imaging with 7 degrees of freedom that provide for dexterity of movement (da Vinci). A study reviewing 325 patients that underwent RAVT lobectomies for primary NSCLC in three different centers found median operative time of 210 min, overall morbidity of 25.3%, median chest tube duration of 3 days, median hospital LOS of 5 days, median tumor size of 2.2 cm, median number of 5 lymph nodes dissected, and 12% of patients experiencing major complications [8]. The majority of these operations were for upper lobectomies (51%), Adenocarcinoma subtype (73%), and pathologic stage-I disease (76%) [8]. Other studies have found mean operative time for RAVT lobectomies to range from 217-240 min and mean postoperative hospital LOS from 4 to 4.5 days [9-11]. These results again affirm that RAVT lobectomy is at least as safe and efficacious as compared to VATS lobectomy.

Esophageal leiomyomas, which comprise 60 % to 70% of all benign tumors of the esophagus, are the most common benign esophageal tumor, despite their overall rare incidence compared to carcinomas in general [12]. The majority of leiomyomas are asymptomatic; however, symptomatic patients most frequently complain of dysphagia [13]. Surgical enucleation of the tumor remains the standard of care, although the ideal technique is under debate depending on the size, shape, and location of the leiomyoma. Reviews of esophageal leiomyomas resected by the minimally invasive VATS approach have found mean operative time of 89 to 100 min for average tumor sizes ranging from 5 cm to 6 cm [2,3,5]. Average blood loss was reported to be 25 ml in one review of nine cases and negligible in a review of ten cases [3,5]. Mean postoperative hospital LOS ranged from 2 to 3.2 days, with one review reporting 7 days due to less costly hospital LOS in Taiwan where the operations were performed [2,3,5].

The flexibility of the da Vinci surgical robotic system has allowed for unique combined surgical cases, such as a combined robotic-assisted radical nephrectomy with a robotic-assisted radical prostatectomy and a combined robotic-assisted laparoscopic prostatectomy and laparoscopic with hemicolectomy [14,15]. However, the majority of these cases, including those utilizing laparoscopic or thoracoscopic approaches, remain within the same surgical field, demonstrating that there is room for development of cross-discipline approaches to combined surgical cases.

Conclusion

To the best of our knowledge, this is the first reported case of a successfully performed concurrent RAVT pulmonary lobectomy for lung cancer concurrent with RAVT excision of an esophageal leiomyoma. The combined procedure had several benefits to the patient, including a shorter intraoperative time, lower estimated blood loss, and shorter postoperative hospital LOS than if the two procedures were performed individually. In addition, there were no intraoperative or postoperative complications.

Though this is the first case of this particular combined robotic-assisted surgery, combined MIS and robotic-assisted surgeries are becoming more commonplace. Combined procedures in general have the advantages of reducing morbidity, convalescence, inconvenience, and cost intrinsic of multiple operations.

Acknowledgements

This case report was previously presented in part as a poster at the 22nd European Conference on General Thoracic Surgery of the European Society of Thoracic Surgery in Copenhagen, Denmark on June 10, 2014.

We gratefully acknowledge Carla C. Moodie PA-C and Joseph R. Garrett MPH ARNP-C for their assistance with the care of this patient.

Informed consent: Permission was obtained from the patient for publication of this case report and any accompanying images for education purposes as part of our institutional surgical informed consent. A copy of the written consent is available for review by the Editor-in-Chief of this journal.

Conflict-of-Interest (COI) Disclosures

K.L.M. and E.M.T. have had financial relationships with Intuitive Surgical Inc. in the form of honoraria as robotic thoracic surgery proctors and observation sites. No other authors have any COI to disclose. K.L.M. is currently Medical Director for Gastrointestinal

Surgical Oncology at Sarasota Memorial Hospital, Sarasota, FL, USA. I.T.R. (now MD) is currently a resident in the Department of Obstetrics & Gynecology at Beth Israel Deaconess and Harvard Medical Centers, Boston, MA, USA.

Provenance and Peer Review

Not commissioned; externally peer-reviewed.

References

1. Howington JA, Blum MG, Chang AC, Balekian AA, Murthy SC. Treatment of stage i and ii non-small cell lung cancer: Diagnosis and management of lung cancer, 3rd ed: american college of chest physicians evidence-based clinical practice guidelines. Chest. 2013;143(5 suppl):e278S-e313S.
2. Luh SP, Hou SM, Fang CC, Chen CY. Video-thoracoscopic enucleation of esophageal leiomyoma. World J Surg Oncol. 2012;10(1):52.
3. Ben-David K, Alvarez J, Rossidis G, Desart K, Caranasos T, Hochwald S. Thoracoscopic and Laparoscopic Enucleation of Esophageal Leiomyomas. J Gastrointest Surg. 2015;19(7):1350-4.
4. Elli E, Espat NJ, Berger R, Jacobsen G, Knoblock L, Horgan S. Robotic-assisted thoracoscopic resection of esophageal leiomyoma. Case Reports Surg Endosc. 2004;18(4):713-6.
5. Claus CMP, Cury Filho AM, Boscardim PC, Andriguetto PC, Loureiro MP, Bonin EA. Thoracoscopic enucleation of esophageal leiomyoma in prone position and single lumen endotracheal intubation. Surg Endosc. 2013;27(9):3364-9.
6. Wei S, Chen M, Chen N, Liu L. Feasibility and safety of robot-assisted thoracic surgery for lung lobectomy in patients with non-small cell lung cancer: a systematic review and meta-analysis. World J Surg Oncol. 2017;15(1):98.
7. Velez-Cubian FO, Ng EP, Fontaine JP, Toloza EM. Robotic-Assisted Videothoracoscopic Surgery of the Lung. Cancer control. 2015;22(3):314-25.
8. Park BJ, Melfi F, Mussi A, Maisonneuve P, Spaggiari L, Da Silva RK, et al. Robotic lobectomy for non-small cell lung cancer (NSCLC): long-term oncologic results. J Thorac Cardiovasc Surg. 2012;143(2):383-9.
9. Gharagozloo F, Margolis M, Tempesta B. Robot-assisted thoracoscopic lobectomy for early-stage lung cancer. Ann Thorac Surg. 2008;85(6):1880-5; discussion 5-6.
10. Park BJ, Flores RM, Rusch VW. Robotic assistance for video-assisted thoracic surgical lobectomy: technique and initial results. J Thorac Cardiovasc Surg. 2006;131(1):54-9.
11. Veronesi G, Galetta D, Maisonneuve P, Melfi F, Schmid RA, Borri A, et al. Four-arm robotic lobectomy for the treatment of early-stage lung cancer. J Thorac Cardiovasc Surg. 2010;140(1):19-25.
12. Seremetis MG, Lyons WS, deGuzman VC, Peabody JW. Leiomyomata of the esophagus. An analysis of 838 cases. Cancer. 1976;38(5):2166-77.
13. Jiang W, Rice TW, Goldblum JR. Esophageal leiomyoma: experience from a single institution. Dis Esophagus. 2013;26(2):167-74.
14. Lavery HJ, Patel S, Palese M, Kasabian NG, Gainsburg DM, Samadi DB. Combined Robotic Radical Prostatectomy and Robotic Radical Nephrectomy. JSLS. 2010;14(4):603-7.
15. Lavery HJ, Patel SA, Chin E, Samadi DB. Combined Robotic-Assisted Laparoscopic Prostatectomy and Laparoscopic Hemicolectomy. JSLS. 2011;15(4):550-4.