Annals of Biomedical Imaging

Research Article

Craniofacial Pain Eagle Syndrome

*Jesus J. Aguaviva Bascunana**

Department of Surgery, Gynecology and Obstetrics, University of Zaragoza, Spain

Abstract

The Eagle syndrome is an infrequent nosological entity described in 1937 by W. Eagle, secondary to the elongation of the styloid process and calcification of the hyoid-style ligament. Although in the majority of cases it occurs asymptomatically, the pressure exerted by this alternative structure from the anatomical point of view against the neighboring areas can trigger a great variety of symptoms.

It generates a frequent diagnostic error that generates multiple inter consultations to different professionals, so the professional must take it into account in those cases of pain in the maxillofacial region without a clear etiology.

The case of a 51-year-old patient is presented, with no significant pathological history except for L5-S1 disc herniation, without foraminal involvement, with a history of 8 years of evolution of right, deaf cervical-occipital pain, sometimes described as a whiplash, which radiates to the mandibular branch, of a few seconds duration and repeated numerous times throughout the day, with progressive worsening in the last year, and in which studies with computed tomography with 3D reconstruction demonstrated an elongation of both styloid process.

Keywords: Eagle syndrome; Occipital neuralgia; CBCT

Introduction

Eagle syndrome, first described in 1937 by Eagle himself, is a nosological entity that is due to an elongation of the styloid processes with the consequent compression of neighboring structures. Although approximately 4% of the population possesses this styloid elongation, only between 4% to 10.3% of these patients will report symptoms related to this syndrome [1,2].

The styloid process is a thin cylindrical bone projection, which measures 25 mm on average. Its origin is in the tympanic portion of the temporal bone, and it is related to the external and internal carotid arteries, sternomastoid foramen, facial nerve and sternomastoid artery. From the styloid process, three muscles originate: stylohyoid, styloglossus and stylopharyngeal, in addition to two ligaments: the stylohyoid and the stylomandibular [3].

Population studies indicate that elongation of the styloid process is more frequent in women between 60 and 79 years of age [4], although they are longer in men. In a laterality analysis, the findings indicate that bilateral elongations are more frequent, with greater length on the right side [5].

The first published case describes a calcified elongation of the stylohyoid ligament in 1652 by Pietro Marchetti, a surgeon from Padua. Subsequently, and already in 1872, Weinlechner described the first case of elongation of the surgically treated stylohyoid process. And it was not until 1937 when Dr. Watt W. Eagle, from Duke University, began to define the syndrome as a result of the elongation of the styloid process, getting to describe it in two syndromes (classic syndrome after tonsillectomy and stylocarotid syndrome not associated with tonsillectomy), establishing a length greater than 25 mm of the styloid process as responsible for the symptoms [6].

Embryology

Classically, it is considered that the origin of the hyoid bone is derived from the cartilage of the second and third pharyngeal arches. Through a condensation process in the 2nd pharyngeal arch, the Reichert cartilage is formed, which at one end contacts the otic capsule and at the other end with the hyoid. Subsequently, after 2 months of gestation, the central part is reabsorbed, leaving a cranial part (styloid process) and a caudal part (minor hyoid horn) [7].

The lesser horn, together with the upper part of the hyoid body, would therefore be formed, from the ossified ventral limb of the cartilage of the second arch and is joined with its counterpart on the opposite side.

The cartilage of the third arch joins the ventral end of the cartilage of the second corresponding arch and, through the midline, with the cartilage of the second and third arches on the opposite side.

When ossification occurs, the cartilage of the third arch becomes the greater horn and the caudal portion of the body of the hyoid, thus Hamilton and Mossman, 1975, and similarly the authors in whose embryology texts (Sadler, 1996, Moore and Persaud, 1999, Carlson, 2009) have pointed out that the lesser antlers and the upper half of the body derive from the cartilage of the second arch and the lower half of the body and the greater antlers of the cartilages of the third arches [8].

Importance health expenditure

The importance of knowing this pathology is that, since the symptoms are variable and nonspecific, patients seek treatment in several different specialties, such as otolaryngology, family medicine, neurology, neurosurgery, psychiatry and dentistry, by which seems to be of great importance to carry out additional studies with large samples to clarify the etiology of this disorder [9].

Citation: Bascunana JJA. Craniofacial Pain Eagle Syndrome. Ann Biomed Imaging. 2019; 1(1): 1002.

Copyright: © 2019 Jesus J. Aguaviva Bascunana

Publisher Name: Medtext Publications LLC

Manuscript compiled: October 03rd, 2019

***Corresponding author:** Jesus J. Aguaviva Bascunana, Department of Surgery, Gynecology and Obstetrics, Albalate of Cinca Health Center (Huesca), University of Zaragoza, Spain, E-mail: jjaguaviva@gmail.com

All of this, logically, increases the health expenditure in addition to the inconvenience for the patient generates the pilgrimage itself, and on few occasions, towards the aforementioned consultations. Therefore, it should be taken into consideration in the differential diagnosis of some cervicalgia and in cases of glossopharyngeal neuralgia [2,10].

The diagnosis therefore requires a high index of suspicion, based primarily on the history and physical examination. Atypical, unilateral or bilateral cervicofacial pain, the absence of response to the corresponding analgesic treatment, palpation of the apophysis in the tonsillar fossa, and other data such as pain relief after the infiltration of local anesthetics and pain can lead to this syndrome. Persistent pharyngeal exacerbated by neck rotations, mouth opening or swallowing itself [11,12].

Pathophysiological theories

Eagle syndrome is a rare neurological syndrome. It consists of a pain in the cervical and craniofacial region caused by elongation and angulation of the styloid process, as well as the associated calcification of the stylohyoid ligament. Sometimes, this radiological alteration is only a casual finding [13].

Different Pathophysiological theories have been proposed to explain the allergic symptoms, such as compression of the cranial nerves V, VII, IX, X and XII, irritation of the pharyngeal mucosa and posterior fibrosis of the tonsillar bed, traction of blood vessels of the parapharyngeal space, irritation of sympathetic innervations by external compression or degenerative or inflammatory changes of the stylohyoid ligament [1,11].

Likewise, other theories about the stimulation of ossification are contemplated, including a history of surgical and non-surgical cervical trauma, anatomical variations, postmenopausal endocrinological alterations (early menopause) and genetic predisposition, and autosomal dominant inheritance has even been described. On the other hand, histological and immunohistochemical studies have shown that the abnormal ossification of the styloid process and the styloid complex results from a protective response to increased tensile stress of the styloid ligament on the styloid process, which could lead to the expression of osteogenic proteins. In the periodic fibrous tissue of this [12]

On the other hand, the Pathophysiological mechanisms for pain of this entity would include [14].

Compression of the neural elements, the glossopharyngeal nerve, the inferior branch of the trigeminal nerve and the tympanic cord by the elongated styloid process, Fracture of the ossified stylohyoid ligament, followed by the proliferation of granulation tissue that causes pressure on the surrounding structures and produces pain, Impact on the carotid vessels by the styloid process, causing irritation of the sympathetic nerves in the arterial sheath, Degenerative and inflammatory changes in the tendon portion of the stylohyoid insertion, a condition called insertion tendinosis. Irritation of the pharyngeal mucosa by direct compression by the styloid process, Stretching and fibrosis involving cranial nerves V, VII, IX and X in the post-tonsillectomy period.

Diagnostic criteria

Orofacial and cervical pain is a very frequent reason for consultation in Primary Care, and may be related to multiple pathological processes. Among them is Eagle syndrome, an under diagnosed, controversial entity whose criteria have been modified in successive classifications of the International Headache Society (IHS) [13].

Currently, Eagle syndrome is included in the international classification of IHS headaches, within the group of secondary headaches, specifically those attributable to cranial, cervical, and ocular, ear, nose, paranasal sinuses, teeth, mouth or other structures. Heading 11.8 is headache or facial pain attributed to inflammation of the stylohyoid ligament and refers to Eagle syndrome. The diagnostic criteria are [15].

A- Any headache, neck, pharynx and facial pain that meets the criteria C.

B- Radiological evidence of elongation or calcification of the stylohyoid ligament.

C- Causality demonstrated by at least two of the following

- Pain is triggered or exacerbated by palpation of the stylohyoid ligament.
- Pain is triggered or exacerbated by cephalic turns.
- Pain is significantly improved by local infiltration of anesthetic into the stylohyoid ligament, or by styloidectomy.
- Pain is ipsilateral to the inflamed stylohyoid ligament.

D- It is not better explained by another diagnosis of ICHD-3.

Differential diagnosis

The differential diagnosis must be made with several pathologies [16-21]. Glossopharyngeal Neuralgia, Ernest Syndrome, Pseudo stylohyoid Syndrome and Anterior Cervical Pain Syndrome. Similarly, trigeminal, sphenopalatine, superior and geniculate laryngeal neuralgia, pharyngeal and tongue-based tumors and chronic pharyngotonsillitis should be considered.

In the glossopharyngeal neuralgia the pain is sharp and sharp, of great intensity, being located in the pharynx and irradiated to the ear or vice versa. The distribution of pain is diagnostic: pain radiates from the pharynx, the amygdala and the base of the posterior tongue towards the eustachian tube and the inner ear or mandibular angle. It has a subtle initial phase with an average duration of 30 seconds. Crises usually occur during the day, and swallowing, and probably cold liquids, are the most common triggers. Speech, sneezing, manipulation of the oral cavity and even sudden movements of the head, elevation of the upper limb of the affected side and lateral movement of the jaw can also behave as triggers of the allergic picture [22].

This neuralgia is associated with tumors, infections, vascular lesions and a differential diagnosis should be made with the Eagle and Trotter syndromes, the latter due to pain related to the jaw, tongue and lateral area of the head.

Ernest's syndrome, in which the stomaco mandibular ligament is damaged, sometimes due to a whiplash syndrome, caused by hyper flexion or forced hyperextension of the cervical spine and the temporomandibular joint, is characterized by the presence of pain in the region preauricular and mandibular angle, irradiated to the neck, shoulder and eye of the same side, associated with pain during palpation of the stylomandibular ligament [23].

© 2019 - Medtext Publications. All Rights Reserved.

In the pseudo stylohyoid syndrome, the stylohyoid ligament is not calcified but hardened by age which produces the symptoms of a stilalgia.

The anterior cervical painful syndrome described by Kunachak summarizes three painful syndromes at the throat level in a similar way to how Eagle or stylohyoid syndrome manifests; these are hyoid syndrome, thyroid cartilage syndrome and cricoid cartilage syndrome.

Third molars should be excluded in the radiological diagnosis as possible causes of pain radiated to the throat.

Temporomandibular disorders that include muscle trigger points and inflammatory and symptomatic joint disorders among others should also be ruled out.

The craniocervical muscle component can generate symptomatic contributions that can be confused with an Eagle syndrome. Trigger points in the muscles of the styloid process produce sub auricular, mastoid pain. Cervical trauma generates a protective muscle contraction in the posterior and anterior cervical muscles that compromise the supra hyoid muscles and generate hypo mobility and asynchronous movements in the tongue that mimic a stilalgia.

Radiological diagnosis

The diagnostic confirmation logically goes through the radiological detection of the elongation of the styloid process, which is considered normal in 20 mm to 25 mm, although a variation between approximately 1.53 mm to 4.77 mm is described, and there is some unanimity in considering it as responsible of the syndrome from a length greater than 30 mm [24].

The cervical spine and skull radiography, orthopantomography and computerized tomography can be useful in this regard from the Primary Care consultation, although it is the development of three-dimensional tomography (3D) and the introduction of the cone beam (CBCT) what has made possible a better description of the anatomy of adjacent structures [25]. The CBCT is capable of providing a sub-millimeter resolution in images of high diagnostic quality, with short scan times (10 seconds to 70 seconds) and radiation doses 15 times lower than those necessary for conventional CT scans [26]. In addition, it provides a reliable three-dimensional image of the spatial relationship between the teeth and the face and their surrounding anatomical structures allowing an adequate evaluation of the tissues [27].

In relation to radiological studies, panoramic and lateral skull radiography is those used in the first instance. Tele radiographs are a fundamental part of dentistry studies, in the branch of orthodontics, since they allow the angles and proportions of the bones of the patient's face to be measured and thus know the relationship between their facial structures. Therefore, Teleradiographs are also called cephalometries, and from them what are known as cephalometric studies are prepared.

Regarding orthopantomography, a technique widely used in the Orofacial region, it offers information on the vertical dimension of the bone, the location of various anatomical points, and all facial structures (jaw, maxilla, support structures and temporomandibular joint) in a single image. It provides good results, with a correct cost-benefit ratio, exposing the patient to minimal radiation.

The disadvantage of these two techniques lies in their degree of distortion, up to 37%, which can lead to diagnostic errors, so it is convenient to perform a tomography of the patient with an open mouth to determine the length and degree of relationship between the stylohyoid complex and the structures related to the angle of the jaw [18].

Multi Detector Computed Tomography (MDCT) is considered the method of choice to confirm the diagnosis, as it allows for three-dimensional reconstructions, visualization of the elongated styloid processes and calcification of the stylohyoid ligament.

Other radiological examinations, such as angiography or Doppler, may be useful for demonstrating compression of the carotid artery in the carotid syndrome.

Based on its radiographic appearance, the stylohyoid complex can be classified into 3 types [18]:

1. Type I. Elongated: This calcified stylohyoid complex has the radiographic appearance characterized by an unbroken integrity of the styloid image.
2. Type II. Pseudo-articulated: In this type of radiographic appearance, the styloid process is attached to the stoma mandibular ligament or the stylohyoid ligament by a single pseudo-joint located superior to the lower edge of the jaw (tangentially).
3. Type III. Segmented: This type consists of portions of the styloid process that are short or long, that is not continuous or interrupted segments of the mineralized ligament. The appearance is of a styloid complex that is mineralized and segmented.

Depending on the type of calcification, we consider [28]:

A. Calcified outside the line

B. Partially calcified

C. Nodular

D. Fully calcified

Treatment

The treatment will depend on the intensity of the symptoms. In case of mild or moderate pain, treatment with habitual analgesics or management in pain units is recommended.

Infiltrations in pain units to relieve the occipital neuralgic picture constitute a simple and underutilized, highly effective procedure that manages to avoid or reduce the chronic use of drugs orally, does not generate serious adverse effects during or after the procedure and compared with the Chronic pharmacotherapy is low cost [29].

Surgery is usually reserved for cases that occur with severe pain or refractory to pharmacology. This surgical treatment can be performed by a transoral or cervical approach [1,10].

The transoral or oropharyngeal approach is used when the caudal portion of the styloid process has to be removed, and when this portion is easily palpable through the tonsillar fossa. It is a difficult procedure, since it is performed blindly and at high risk of injuring the glossopharyngeal nerve, the facial nerve or the external carotid artery [28]. In the described technique, a Boyle Davis mouth opener is placed for better visualization of the surgical area, identifying the styloid process by digital palpation at the level of the tonsil fossa and then making an incision on the mucosa, dissection on the upper constrictor muscle to expose the tip of the styloid process and its skeletonization.

© 2019 - Medtext Publications. All Rights Reserved.

Tendon and muscle inserts are approached and finally the styloid process is removed as close as possible to its base with the help of a Kerrison clamp-legra [18].

In the extra oral or transcervical access, Hinds approach, we proceed to make a sub mandibular linear incision of about 10 cm in length, which extends from the mastoid process along the anterior edge of the sternocleidomastoid to the level of the hyoid bone, dissecting by planes, until locating the elongated process. Muscles inserted in it are dissected with legra and the process is fractured with Kelly's tweezers.

The cervical approach presents greater safety and better visualization of neurovascular structures, thus reducing the risk of injuries and favoring a better visibility of the surgical field and a lower risk of infection of the deep spaces of the neck [6,18,28].

Material and Methods

Clinical case

The case of a 51-year-old patient is presented, with no significant pathological history except for L5-S1 disc herniation, without foraminal involvement, with a history of 8 years of evolution of right, deaf cervical-occipital pain, sometimes described as a whiplash, which radiates to the mandibular branch, of a few seconds duration and repeated numerous times throughout the day, with progressive worsening in the last year, and in which studies with computed tomography with 3D reconstruction demonstrated an elongation of both styloid process.

In follow-up for about 2 years in outpatient ENT, neurology and pain unit (up to 3 different centers) multiple treatments had been prescribed to date without success:

- NSAIDs and COX-2 (diclofenac, etoricoxib)
- Corticosteroids (prednisone in descending patterns).
- Amitriptyline.
- Oxcarbazepine.
- Carbamazepine.
- Topiramate.
- Pregabalin.
- Gabapentin.
- Baclofen.
- Clonazepan.
- Botulinum toxin.
- Topical Lidocaine 5%.
- Discharge splints and physiotherapy.
- 4 infiltrations in pain units for the occipital neuralgic picture (simple and underutilized procedure, highly effective, which manages to avoid or reduce chronic use of drugs by mouth, does not generate serious adverse effects during or after the procedure and compared with pharmacotherapy chronic results of low cost). With all of them he had a bad response. He had not reported episodes of dysphonia, or burning sensation or paraesthesia in hemicara or retroocular pain.
- Radiofrequency of the occipital nerve (major and minor) and medial C3-C4.

A series of complementary explorations had been carried out, without revealing interesting findings:

- Cervical MRI.
- Cranial MRI.
- Nasofibrolaringoscopy and a telearingoscopy.

In the Primary Care consultation, the physical examination showed a normal oral cavity, with an anodyne neurological examination and a discrete contracture of the paravertebral musculature. The patient's history was reviewed and it was decided to complete the study with an orthopantomography, and a simple x-ray of the skull and cervical spine, without finding any interesting findings.

Subsequently, CT was requested plus 3D reconstruction of the skull and neck. Sagittal and coronal MPR reconstruction, VR, 3D was performed. The only finding of interest for the reason for consultation was a styloid process of 4.98 cm and 4.67 cm respectively, so in the clinical context and evolutionary history of the patient, the diagnosis of bilateral Eagle syndrome was established (Figures 1 and 2).

Given these findings, a specialized ENT consultation was referred to in these cases, confirming our diagnostic suspicion, and concluding in Arnold neuralgia, sub occipital contracture and Aubin stylalgia in the context of an Eagle syndrome. Given the previous long-term therapeutic failure, the intensity of the condition and the findings in the diagnostic imaging tests, a surgical approach was decided at the lateral cervical level, bilaterally and under general anesthesia, for partial resection of both processes.

The evolution during the 5 months after the intervention was satisfactory, with the disappearance of pain and the progressive abandonment of the medication, being able to consider the labor incorporation. However, in the following months, the picture reappeared, of lower alkaline intensity, also refractory to the mentioned drugs, requiring a bilateral infiltration at the corticosteroid and local anesthetic level, leaving a very long picture until now.

Discussion

Eagle syndrome is usually asymptomatic and represents a casual finding on a routine radiographic exam. In few patients who have a partially or completely calcified stylohyoid ligament as well as an abnormal elongation of the styloid apophysis, atypical facial neuralgia syndromes can be observed.

Figure 1: CBCT-3D. Elongated styloid process.

© 2019 - Medtext Publications. All Rights Reserved.

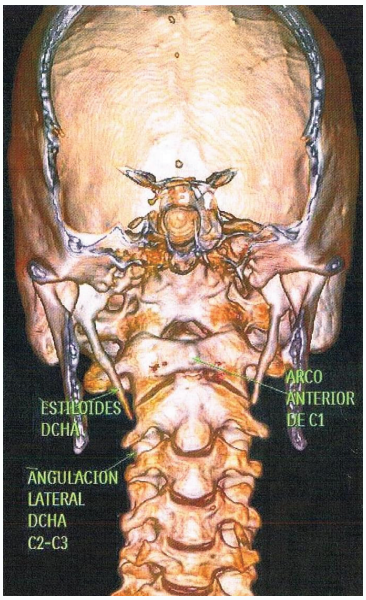

Figure 2: CBCT-3D. Elongated styloid process.

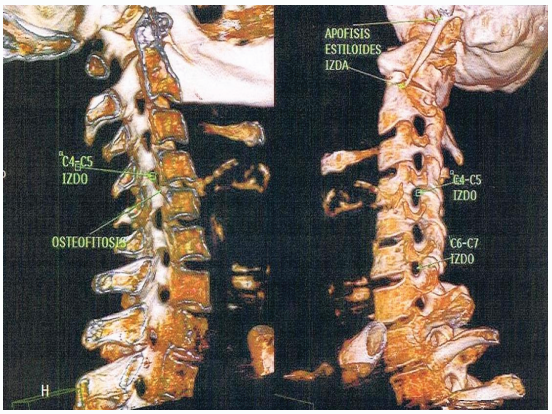

Figure 3: CBCT-3D. Elongated styloid process.

Eagle described two clinical presentations. In the first place, he presented a classic form in which the cardinal symptoms were odynophagia, dysphagia and the pharyngeal foreign body sensation, whose appearance occurred almost immediately after a tonsillectomy. In this case the symptoms appear due to the irritation of neighboring structures, secondary to the calcification of the stylohyoid process; secondly, he described the syndrome of the carotid artery, in which the antecedent of tonsillectomy may or may not exist, and the discomfort is due to a compression of the internal or external carotid artery, which triggers a pain of parietal and periorbital location, generating even dizziness, fugax amaurosis, cervicalgia and syncopal picture with the rotational movements of the head [5].

The radiological study carried out since the Primary Care consultation covers simple cervical spine and skull radiography, which may already show elongated styloid processes, orthopantomography and computerized axial tomography, which may be useful in confirming the finding [2,4].

In the case described, the symptomatology reported in principle did not lead to thinking about the syndrome, but when reviewing the imaging study and correlating it with the symptomatology and clinical history presented by the patient, the diagnosis could be established. The literature review confirmed the coincidence of the table presented with those presented therein. As for the possible etiology, in this case we should attribute it to an anatomical variation, since there is no history of trauma or previous surgery.

In the differential diagnosis, the most common allergic syndromes that can be confused with odontogenic pain should be considered: temporary tenopathy, Ernest syndrome (inflammation of the stylomandibular ligament) and atypical trigeminal neuralgia. Glossopharyngeal and trigeminal neuralgias, temporal arthritis, myofascial pain, secondary molar pain, cervical arthritis, tumors, internal carotid artery syndrome and temporomandibular disorders should also be included.

Conclusion

Since Eagle syndrome is an infrequent pathology, it is worth emphasizing the importance of contemplating a differential diagnosis that fundamentally encompasses the pathologies that cause cervicofacial pain.

On the other hand, the different clinical variants of the pathology should not be overlooked, since they can manifest simultaneously in the same patient.

The exhaustive history and the multidisciplinary approach are essential to establish a correct diagnosis. At the level of diagnostic imaging, and from the Primary Care consultation, the cervical spine and skull radiography, panoramic radiography (orthopantomography) and Computed Tomography (CT) can be useful in this regard. The CBCT with 3D reconstruction accurately shows the elongation of the styloid process and adjacent structures, constituting a valuable tool now to plan the potential surgical treatment.

References

1. Rodríguez-Nagore FJ, Rodríguez-Clorio J. Long styloid process syndrome. An Orl Mex. 2017;62(2):81-8.
2. Gelabert-González M, García-Allut A. Eagle syndrome. A rare cause of cervicalgia. Neurosurgery. 2008; 19(3):254-6.
3. Fuentes Fernándes R, Porto Venegas G, Garay Carrasco I, Busts Medina L, Silva Mella H, Flores Flores H. Styloid Process in the Panoramics Radiographic Sample of Temuco-Chile City in a Panoramic Radiography Sample of the City of Temuco-Chile. Int J Morphol. 2007;25(4):729-33.
4. González-García N, García-Azorín D, Porta-Etessam J. Eagle syndrome towards clinical delimitation. Neurology. 2017.
5. Silva HJ, Moraes SR, Tashiro T. Morph metric analysis of the elements of the hyoid style chain. Rev Chil Anat. 2002;20(2):205-10.
6. Romero Jasso G, Nieto Munguía AM, Sánchez Amador AR. Eagle syndrome Patient management at the Regional Hospital «Licensed Adolfo López Mateos». Revista Odontológica Mexicana. 2015;19(4):254-58.
7. Tísner Nieto JV, Giraldo B Tisner, Abad Royo JM, Abbot Marco A. Calcification of the stylohyoid ligament: Aubin stylagia and Eagle syndrome. Report of 5 clinical cases Stylohyoid process ossification: stylalgie of Aubin and Eagle's syndrome. Report of five cases. O.R.L. Aragon. 2003;6(2):5-12.
8. Santos González ML. Contribution to the development of hyoid bone in humans. Doctoral thesis. Complutense University. Madrid. 2016.
9. Gokce C, Sisman Y, Sipahioglu M. Styloid Process Elongation or Eagle's Syndrome: Is There Any Role for Ectopic Calcification? Eur J Dent. 2008;2:224-8.
10. Mareque Bueno J, Hernández Alfaro F, Biosca de Tejada MJ. Intraoral approach in Eagle syndrome. Presentation of a clinical case. Rev Esp Cir Oral Maxillofac. 2011;33(4):157-6.

© 2019 - Medtext Publications. All Rights Reserved.

11. Nazar R, Naser A, Fullá J. Eagle syndrome in otolaryngology. Rev Hosp Clin Univ Chile. 2008;19:156-61.

12. Marisio G, Santamaría A, Alzérreca J. Eagle syndrome. Literature review Eagle syndrome. Literature reviews Rev. Otorhinolaryngol. Cir Head Neck. 2016;76:121-6.

13. González-García N. Eagle syndrome towards clinical delimitation. Neurology. 2017.

14. Khandelwal S, Singh Fairy Y, Harsh A. Eagle's syndrome - A case report and review of the literature Saudi Dent J. 2011;23(4):211-15.

15. Headache Classification Committee of the International Headache Society (IHS). The International Classification of Headache Disorders, 3rd edition Cephalalgia. 2018;38(1):1-211.

16. Blackett JW, Ferraro DJ, Stephens JJ, Dowling JL, Jaboin JJ. Trigeminal neuralgia post-styloidectomy in Eagle syndrome: a case report. J Med Case Rep. 2012;6:333.

17. Okeson JP. Pains of the temporomandibular joint. In Orofacial Pain according to Bell. 6th ed. 2008.

18. Martínez Montalbán M, Alonso B car, Paradisi Chacón CE, Lacoma Latre EM, Domene Moros R, Padrón Rodriguez N. Eagle syndrome: an under diagnosed pathology. 34 congress of the SERAM.

19. Acosta O. Differential diagnosis of orofacial pain I. Associated with intracranial, extracranial structures and psychogenic disorders. Journal of the Faculty of Dentistry, Universidad de Antioquia. 2001;13(1):5-16.

20. Acosta O. Differential diagnosis of orofacial pain II. Associated with neurovascular, vascular and musculoskeletal disorders. Journal of the Faculty of Dentistry, Universidad de Antioquia. 2001;13(1):17-28.

21. Acosta O. Differential diagnosis of orofacial pain III. Associated with neuropathic disorders. Journal of the Faculty of Dentistry, Universidad de Antioquia. 2001;13(1): 29-39.

22. Singh PM, Kaur M, Trikha A. An uncommonly common: Glossopharyngeal neuralgia. Ann Indian Acad Neurol. 2013;16:1-8.

23. Peñarrocha-Oltra D, Ata-Ali J, Ata-Ali F, Peñarrocha-Diago MA, Peñarrocha M. Treatment of orofacial pain in patients with stylomandibular ligament syndrome (Ernest syndrome). Neurology. 2013;28(5):294-8.

24. Balbuena L Jr1, Hayes D, Ramirez SG, Johnson R. Eagle's syndrome (elongated styloid process) South Med J. 1997;90(3):331-4.

25. Savranlar A1, Uzun L, UÄŸur MB, Ozer T. Three-dimensional CT of Eagle's syndrome. Diagn Interv Radiol. 2005;11(4):206-9.

26. Finlayson AF, Epifanio R. The conical beam computerized tomography. Ustasalud. 2008;7(2):125-31.

27. Bravo F, Navarrete A, Nino A, Rodríguez E, Carlos Martín A, Carmen Lucía, et al. Three-dimensional evaluation of the airway by cone beam computed tomography. University of Chile. AMC. 2012;16(3).

28. Villalba Leyton MA, Miranda Villasana E. Eagle syndrome: a case report Mexican Journal of Oral and Maxillofacial Surgery. 2009;5(1):26-31.

29. Gaye Saavedra GA. Occipital Neuralgia Treatment with anesthetic infiltration. Neurol Arg. 2013;5(1):34-36.

© 2019 - Medtext Publications. All Rights Reserved.