Annals of Clinical Case Studies

ISSN: 2688-1241

Case Report

Epidemiological and Clinical Characteristics of COVID-19: Two Couple Cases Report

Wang CM[#], Xu ZF[#], Wu WX and Pan AZ*

Department of Radiology, The First People's Hospital of Foshan, Guagndong, China

[#]Both the authors contributed equally for the article

Abstract

Objective: To analyse clinical data of two couples with Coronavirus Disease 2019 (COVID-19) in order to get familiar with the clinical features of the disease.

Methods: Two couples with COVID-19 admitted to the first Foshan people's hospital were enrolled from January 20 to February 25, 2020, and their clinical and imaging data were analysed.

Results: Both these two couples had contact history of epidemic area or patients. All patients in the two couples presented with fever and cough, and Blood routine examination in all patients showed white blood cells and lymphocytes were normal or decreased. Viral nucleic acid of husband were both positive, whereas for wife was negative. Lung CT showed that lesions and involved lobes were obvious in both husband, compared with wife. Although the nucleic acid is negative, lung lesions are already visible.

Conclusion: The data of these two couples showed typical clinical characteristics of COVID-19, which helped doctor to deepen the understanding of this disease.

Keywords: Coronavirus disease 2019; Severe acute respiratory syndrome coronavirus; Computed tomography; Aggregation; Case report

Abbreviations

COVID-19: Coronavirus Disease 2019; SARS-CoV-2: Severe Acute Respiratory Syndrome Coronavirus 2; CT: Computed Tomography; BCA: Blood Cell Analysis; GGO: Ground Glass Opacification; ACE2: Angiotensin-Converting Enzyme 2; VNA: Viral Nucleic Acid

Introduction

The atypical pneumonia case, caused by a Novel Coronavirus (2019-nCOV), was first reported and confirmed in Wuhan [1]. Initially confined to Wuhan, the infection has spread elsewhere; sporadic cases exported from Wuhan were reported in overseas. WHO names deadly virus from China as COVID-19, and 2019-nCOV named as Severe Acute Respiratory Syndrome Coronavirus 2 (SARS-CoV-2). The WHO Director-General declared that the COVID-19 outbreak constitutes a public health emergency of international concern and epidemic situation is only getting worse. As of March 1, 2020, COVID-19 has caused 79972 confirmed cases including 2873 deaths, 851 suspected cases in mainland released by the National Health Commission of China. Although, COVID-19 has been effectively suppressed in China, and a heavy price has been paid, the number is still rising. Now Korea has become the second most affected country with 3736 confirmed cases, and followed by Italy with 1128 confirmed cases, Iran with 978 confirmed cases and Japan with 956 confirmed cases. COVID-19 mainly transmitted ways was respiratory droplets and close contact and appeared in family aggregation, and dry cough and fever was the main clinical manifestations [2,3]. Now a days, we have a deep understanding of the clinical symptoms, laboratory examination and imaging features of COVID-19 based on the research and analysis of large cases, but also accumulated some experience. Here, we share the clinical data of two couple cases with COVID-19 in initial stage of the outbreak for providing more scholars with a better understanding.

Citation: Wang CM, Xu ZF, Wu WX, Pan AZ. Epidemiological and Clinical Characteristics of COVID-19: Two Couple Cases Report. Ann Clin Case Stud. 2020; 2(2): 1023.

Publisher Name: Medtext Publications LLC

Manuscript compiled: Apr 23rd, 2020

***Corresponding author:** Xu ZF, Department of Radiology, The First People's Hospital of Foshan, Guagndong, 528000, China, Tel: 0086-0575-83162120; E-mail: xuzf83@126.com

Pan AZ, Department of Radiology, The First People's Hospital of Foshan, Guagndong, 528000, China, Tel: 0086-0575-83162120; E-mail: pazhen2121@126.com

Methods

The first couple

Wife, aged 40, was admitted to hospital for "recurrent fever with cough for 2 weeks". She stayed in Wuhan (Hubei province, China) for two weeks to accompany her father (about from 25, December to 5 January, 2020). She denied having been to the south China seafood market in Wuhan. She had a fever on the high-speed train back to Guangzhou South railway station on January 6, 2020, and temperature reached 38.9°C, accompanied by headache, cough and runny nose. Later, she was diagnosed as "common cold" at a local clinic. After receiving intramuscular injection and oral medication (details were unclear), the symptoms improved and felt no fever. On January 20, she accompanied her husband to the hospital for treatment. Due to her epidemiological history and clinical manifestations in the epidemic area of Wuhan, she was needed isolation treatment as a suspected case.

Husband, aged 40, was admitted to hospital for "fever and cough for 10 days and exacerbation with shortness of breath for 3 days". His wife returned home from Wuhan on January 6, 2020, then he developed a fever four days later. He also was diagnosed as a "common cold" at a local hospital and then treated with medication (details

are unclear). However, the symptoms did not improve and became progressively worse. He was admitted to hospital on January 20 with suspected COVID-19. On January 21 (Day 15 of onset), the nucleic acid test of the SARS-CoV-2 was positive, then he was confirmed as the first imported case with COVID-19 in Foshan, Guangdong province.

For the couple, Blood Cell Analysis (BCA), Blood Gas Analysis (BGA), Nucleic acid test and Chest CT were all performed after hospitalization. Figure 1 showed the details of results and clinical data. Figure 2 demonstrated that the CT features of the couple. After treatment, both husband and wife were cured and discharged from hospital.

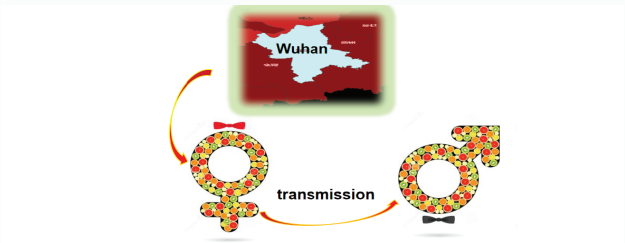

	Clinical symptom		BCA (10^9/L)		BGA (mmHg)		V-NA	Lung CT	Grade
	Cough	Fever	WBC	Lym	PO2	PC02	(n)	(lobes)	
Wife	+	+	7.56	5.02	108	21.2	-	+(2)	Mild
Husband	+	+	7.25	1.51	60.5	49.8	+(15th)	+(5)	Severe

Figure 1: The clinical data and related inspection results of the couple.

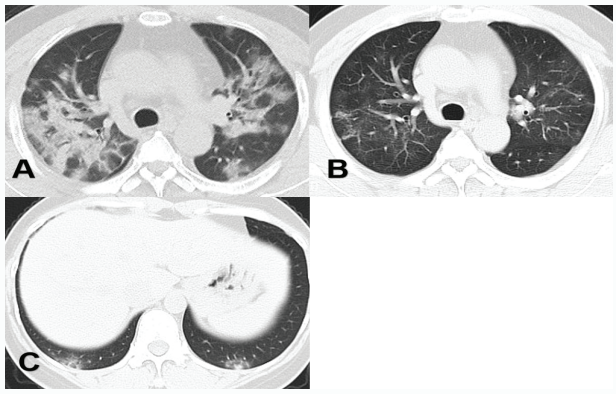

Figure 2: Chest CT examination of the couples. A and B were the images of the husband, A was the chest CT at onset showed multiple GGO and consolidations in bilateral lungs. B showed the lesions were obvious absorption after treatment. C was the chest CT at onset of the wife, showed some GGO lesions in the lower lobe of the bilateral lungs.

The second couple

Wife, aged 26, was admitted to hospital for "cough for 3 days". The patient returned to Foshan from Wuhan with her husband on January 21, 2020, and developed a cough on January 23 and accompanied by headache, but no stomach cold or fever. She denied having been to the south China seafood market in Wuhan. The virus nucleic acid was negative on January 24, 26 and 29. Chest CT showed A few patchy exudate foci in the lung. After treatment, she was cured and discharged from hospital on January 30.

Husband, aged 27, was admitted to hospital for "fever and cough with sputum for 1 day". The patient returned to Foshan from Wuhan on January 21, and developed fever on January 23, with a temperature of 38.5°C, accompanied by cough with sputum. He denied having been to the south China seafood market in Wuhan. He was isolated for suspected cases with COVID-19. Chest CT showed multiple plaques and nodular lesions, with cavity formation. Pulmonary tuberculosis was not excluded. On January 25, virus nucleic acid test showed positive and tuberculin test negative, then he was confirmed as NCP patients (Mild). After anti-infection treatment, the symptoms gradually improved. Viral nucleic acid tests were positive on January 28, February 7 and February 13, and became negative on February 18. Chest CT showed obvious absorption of the original lung lesions, on February 19. The patient remains hospitalized.

For the couple, BCA, BGA, Nucleic acid test and Chest CT were all performed after hospitalization. Figure 3 showed the details of results and clinical data. Figure 4 demonstrated that the CT features of the couple.

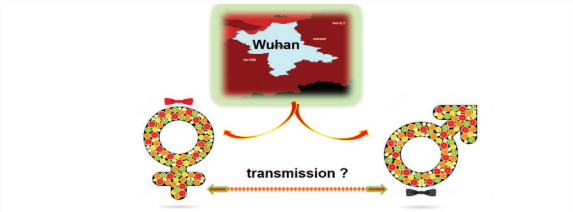

	Clinical symptom		BCA (10^9/L)		BGA (mmHg)		V-NA	Lung CT	Grade
	Cough	Fever	WBC	Lym	PO2	PC02	(n)	(lobes)	
Wife	+	-	5.92	2.39	87	38	-	+(1)	Mild
Husband	+	+	4.08	0.92	72.2	48.6	+(3th)	+(2)	Mild

Figure 3: The clinical data and related inspection results of the couple.

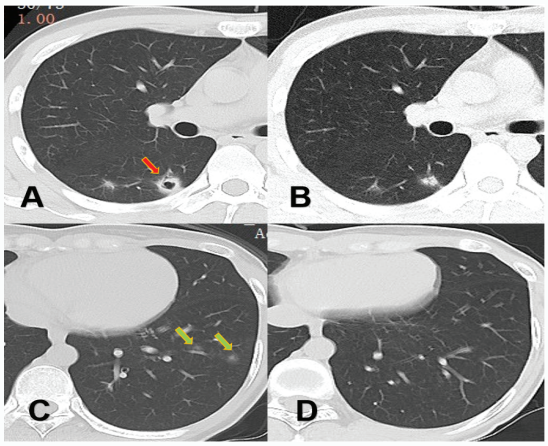

Figure 4: Chest CT examination of the couples. A and B were the images of the husband, A was the chest CT at onset showed nodules with cavity (red arrow) and patches in the lower lobe of the right lung; B showed the lesions were obvious absorption after treatment. C and D were the images of the wife. C was the chest CT at onset showed nodules (green arrow) in the lower lobe of the left lung; D showed the lesions were complete absorption after treatment.

Results and Discussion

Epidemiological and clinical characteristics

COVID-19 has the characteristics of human-to-human transmission and aggregation. Both couples had a history of directly or indirectly contact the epidemic area, and the wife in the first couple was traced back to December 25, 2019, when she was already

in the epidemic area and denied having been to the south China seafood market in Wuhan (source of the outbreak). This case may gave the evidence of human-to-human transmission of COVID-19 in Wuhan had appeared that was reported by Gao et al. [1]. A new model speculates that average R0 is 3.28, and the ability of human transmission was obviously stronger than SARS [2]. Three patients in two couples (75%) developed a fever and all patients (100%) had a cough, which was consistent with previous reports [3-5]. Fever and cough were the main clinical manifestations of COVID-19. A large clinical cases (1099 cases) study by professor Zhong et al. [5] found that only 43.8% showed fever in the early stages, but showed up to 87.9% if fever after hospitalization.

These two couples revealed that men tend to be sicker than women. In these cases, the lung lesions of the husbands were more obvious than that of the wife, and the BGA showed that the PO2 of the husbands were both lower and the PCO2 was both higher than that of the wives. In the first couple, the husband had diffuse involvement in bilateral lungs (5 lobes involved), was diagnosed as a severe patient with mild acidosis. A new study based on 72314 patients revealed that men are more likely to die (2.8%) than women (1.7%). Some scholars speculated that the higher expression of virus bound Angiotensin-Converting Enzyme 2 (ACE2) might be due to the relatively good lung development in men [4]. A study found that there is no significant difference on the expression of ACE2 gene between men and women, but ACE2 gene expression in smoker lung is significantly higher than non-smokers, which suggests smoking may be associated with gender differences in COVID-19 [6]. However, husbands in this two couple were non-smokers and without other illnesses. Therefore, the differences in male and female susceptibility still need to be further studied.

Laboratory examination of COVID-19

BCA of two couples showed that White Blood Cells (WBC) was normal, ranged $(4.08\text{-}5.92)\times10^9$ / L. Lymphocytes of wives was normal, but decreased in husbands (1.51×10^9 / L and 0.92×10^9 / L). These features were in accordance with previous showing consistent with BCA characteristics of COVID-19 [4,5]. Previous study has confirmed that the variation of lymphocyte number can reflect the development of the illness [7]. Lower lymphocytes would indicate the aggravation of disease and poor prognosis. The incidence of husband data in this study provide the case evidence.

Viral nucleic acid detection and chest CT

For the husbands, Viral Nucleic Acid (VNA) were both positive, but were both negative for wives, the positive rate was 50%. However, all patients (100%) were positive in chest CT. Correlation of chest CT and RT-PCR testing in COVID-19 base on 1014 cases were reported by Ai et al. [8]. They found that 59% RT-PCR was positive, while 88% chest CT results were positive. Meanwhile, 75% of the patients with negative RT-PCR showed positive CT results. The data of this group showed similar characteristics. It is suggested that even if VNA examination is negative, COVID-19 still cannot be exclude, moreover, the patient still has infectivity. Chest CT is of great value in the screening and diagnosis of patients and is recommended as a routine examination of COVID-19.

Two couples' chest CT scans were characterized by multiple Ground Glass Opacification (GGO) displaying small plaques, nodules and large frosted, which were consistent with previous report and demonstrated that GGO was the main imaging feature of COVID-19 [9]. Previous reports revealed that GGO as the key CT feature, can exist for a long time throughout the course of the disease, and may be unique CT feature in some early patients. Pathological basis of GGO is mainly diffuse alveolar injury, accompanied by cell fibromyxoid exudate, and lung transparent membrane formation [10].

Summary

The two couples' cases are very interesting. Being familiar with the clinical, laboratory and chest CT data can not only help us grasp the typical manifestations of COVID-19, but also help us understand the specific cases, which is helpful for the clinical screening and diagnosis of COVID-19.The key information obtained from the two couples in this study was as follows:

1. COVID-19 has clear characteristics of human-to-human transmission and aggregation onset, and the situation of man was relatively worse.

2. Fever and cough were the main clinical features of COVID-19. BCA often show WBC was normal or decreased and lymphocytes were decreased, and the lymphocytes change is related to the disease progression.

3. COVID-19 was characterized by GGO lesions in chest CT. In severe cases, wider extent in the lung was involved.

4. Some patients lack typical clinical features and have negative VNA test, but are still with infectivity. Chest CT has a higher positive rate and can be an important supplementary examination.

Funding Source

Science innovative project of Foshan (FSOAA-KJ218-1301-0021).

Ethical Approval

Our institutional review board waived written consent for this retrospective case series involved no potential risk to patients.

References

1. Li Q, Guan X, Wu P, Wang X, Zhou L, Tong Y, et al. Early Transmission Dynamics in Wuhan, China, of Novel Coronavirus-Infected Pneumonia. N Engl J Med. 2020;382(13):1199-207.
2. Liu Y, Gayle AA, Wilder-Smith A, Rocklöv J. The reproductive number of COVID-19 is higher compared to SARS coronavirus. J Travel Med. 2020;27(2).pii:taaa021.
3. Chen N, Zhou M, Dong X, Qu J, Gong F, Han Y, et al. Epidemiological and clinical characteristics of 99 cases of 2019 novel coronavirus pneumonia in Wuhan, China: a descriptive study. Lancet. 2020;395(10223):507-13.
4. WJ G, Ni Z, Hu Y, Liang WH, Ou C, He JX, et al. Clinical characteristics of 2019 novel coronavirus infection in China. medRxiv. 2020.
5. Huang C, Wang Y, Li X, Ren L, Zhao J, Hu Y, et al. Clinical features of patients infected with 2019 novel corona virus in Wuhan, China. Lancet. 2020;395(10223):497-506.
6. Cai G. Tobacco-Use Disparity in Gene Expression of ACE2, the Receptor of 2019-nCov. Preprints. 2020.
7. Liu J, Li S, Liu J, Liang B, Wang X, Wang H, et al. Longitudinal characteristics of lymphocyte responses and cytokine profiles in the peripheral blood of SARS-CoV-2 infected patients. medRxiv. 2020.
8. Ai T, Yang Z, Hou H, Zhan C, Chen C, Lv W, et al. Correlation of Chest CT and RT-PCR Testing in Coronavirus Disease 2019 (COVID-19) in China: A Report of 1014 Cases. Radiol. 2020.
9. Lei J, Li J, Li X, Xiaolong Q. CT Imaging of the 2019 Novel Coronavirus (2019-nCoV) Pneumonia. Radiol. 2020.
10. Xu Z, Shi L, Wang Y, Zhang J, Huang L, Zhang C, et al. Pathological findings of COVID-19 associated with acute respiratory distress syndrome. Lancet Respir Med. 2020;8(4):420-2.