American Journal of Cardiovascular Surgery

Clinical Image

Fatal Thrombosis after Discontinuation of Anticoagulation in A High-Risk Patient

*Violeta Chica-Sáez, María Sevilla-Martínez and Manuel García-Delgado**

Department of Cardiac Surgery Unit, Intensive Care Unit. Virgen de las Nieves Universitary Hospital, Spain

Clincial Image

A 51-year-old woman undergoing scheduled surgery for mechanical valve replacement for rheumatic mitral disease. Systemic lupus erithematous and antiphospholipid syndrome were main personal antecedents. In the past, she had suffered various thromboembolic events and was treated with acenocoumarol for this. A complicated postoperative course ocurred, including prolonged mechanical ventilation. After 14 days in ICU, interruption of anticoagulation with Unfractional heparin (UFC) was done because a percutaneous tracheostomy was necessary. Only at 4 hours without UFC, severe clinical deterioration happened: swelling of face, neck, upper body and arms, and hypoxemia.

CT angiography (Figure 1) showed thrombosis of the superior vena cava and a large thrombus, which occupied almost the entire left atrium, was found in transesophageal echocardiography (Figure 2 and 3). The patient, who had a high thromboembolic risk, died.

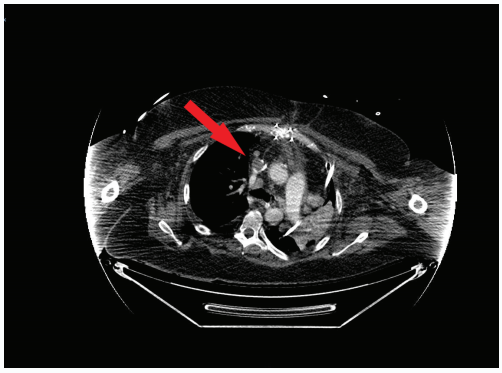

Figure 1: CT angiography of the chest. Thrombus in superior cava vein (red arrow).

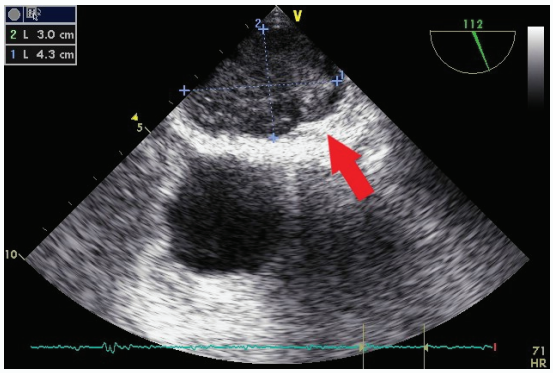

Figure 2: Transesophageal echocardiography, modified ME bicaval view. Large thrombus (30x43 mm) occupies the upper area of left atrium (red arrow).

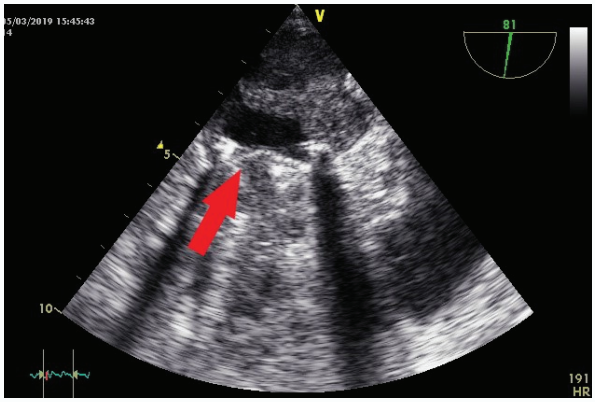

Figure 3: Transesophageal echocardiography, ME two chambers view. Thrombus is seen in the upper area of the image within the left atrium. Mechanical mitral valve (red arrow).

Citation: Chica-Sáez V, Sevilla-Martínez M, García-Delgado M. Fatal Thrombosis after Discontinuation of Anticoagulation in A High-Risk Patient. Am J Cardiovasc Sur. 2020;1(1):1005.

Copyright: © 2020 Violeta Chica-Sáez

Publisher Name: Medtext Publications LLC

Manuscript compiled: Sep 17th, 2020

***Corresponding author:** Manuel García-Delgado, Department of Cardiac Surgery Unit, Intensive Care Unit, UCI Hospital Universitario Virgen de las Nieves, Avda. Fuerzas Armadas, 2 18004 Granada, Spain, E-mail: mjgardel@hotmail.com

© 2020 - Medtext Publications. All Rights Reserved.