American Journal of Surgery Case Reports

Case Report

Frontal Sinus Encephalocele of Likely Late Onset: Case Report

Borges I[1], Ferreira F[1], Oliveira MV[1,2] and Oliveira GH[2*]

[1]Universidade Federal de São João del Rei (UFSJ), Brazil

[2]Department of Neurosurgery, Santa Casa de Misericórdia de São João del Rei, Brazil

Abstract

We describe the case of a 54-year-old man who presented with intense bilateral rhinorrhea and underwent multiple non-resolving treatments for rhinosinusitis. The patient had a history of head trauma approximately eight years prior to the onset of symptoms. A Computed Tomography (CT) scan showed isodensity regions in the frontal sinus and a veiling in the maxillary sinus, as well as the presence of bone defect in the frontal bone with contiguity of contents. The liquorrhea analysis revealed two-thirds of blood glucose value, confirming suspicions of intracranial fluid origin. Surgery was performed and the herniation was resolved, followed by a pericranial flap closure. There were neither postoperative repercussions nor recurrence of symptoms at 6 months of follow up.

Keywords: Frontal encephalocele; Cranial meningoencephalocele; CSF leak

Introduction

Traumatic Encephaloceles are of uncommon occurrence and frontal sinus encephalocele are even more so, as they tend to occur in more fragile regions of the skull (such as the cribriform plate or the lateral recess of the sphenoid sinus) [1]. This report describes a case of a 54-year-old male patient who presented with symptoms possibly related to a late onset of traumatic injury. The patient has a history of head trauma approximately eight years before the beginning of intense Cerebrospinal Fluid (CSF) rhinorrhoea.

Case Presentation

A 54-year-old male developed intense rhinorrhea two and a half years ago, which worsened with forward bending of the head. In addition, he complained of chronic nasal congestion, hyposmia and post-nasal drip. He underwent multiple assessments and received treatment for rhinosinusitis, but showed no response. Due to the lack of improvement, a computerized tomography scan was requested to evaluate the sinuses.

The patient, then, sought the service of Neurosurgery at the city of São João del Rei. He reported a head trauma from falling off the back of a pickup truck ten years ago, with onset of symptoms only eight years later. Physical examination revealed rhinoliquorrhea, confirmed by glucose dosage of the secretion, which indicated 2/3 of blood glucose value. The team then re-evaluated the patient's previous imaging exams and concluded that he had a post-traumatic encephalocele with herniation to the frontal sinus (Figure 1 and 2).

Citation: Borges I, Ferreira F, Oliveira MV, Oliveira GH. Frontal Sinus Encephalocele of Likely Late Onset: Case Report. Am J Surg Case Rep. 2023;4(7):1081.

Publisher Name: Medtext Publications LLC

Manuscript compiled: Jul 27th, 2023

***Corresponding author:** Gustavo Henrique Reis de Oliveira, Department of Neurosurgery, Santa Casa de Misericórdia de São João del Rei, São João del Rei, 36307-346, Brazil, Tel: +55-32-9944-0605

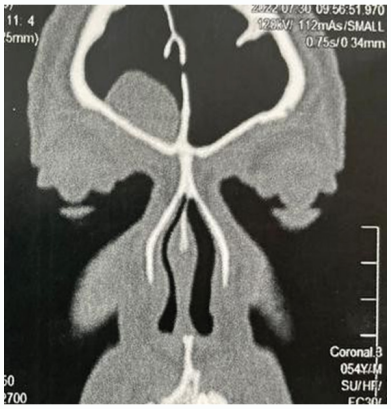

Figure 1: Head Computerized Tomography from the patient. The presence of isointense content in the frontal sinus can be observed.

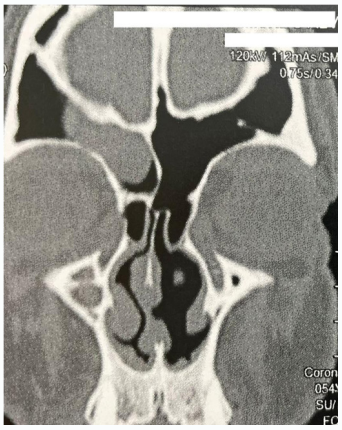

Figure 2: Head Computerized Tomography from the patient. The presence of isointense content in the frontal sinus can be observed.

After imaging evaluation, an open surgical approach was chosen, considering the location of the injury. For the procedure, the patient was positioned on the surgical table and had his head fixed with Mayfield pins for the realization of a bifrontal craniotomy. A coronal

approach was made with a Sutar incision (bi-temporal incision), exposing the frontal bone. Subsequently, nasal and orbital osteotomies were performed to remove the supraorbital bar, allowing access to the frontal sinus where the herniation was observed (Figure 3).

At this stage, the exact nature of the herniation remained unknown and was assessed by means of direct needle puncture, which yielded a negative result and confirmed the presence of brain tissue. The content was then reduced and a careful closing was performed in order to prevent future herniations or CSF fistulas (Figure 4).

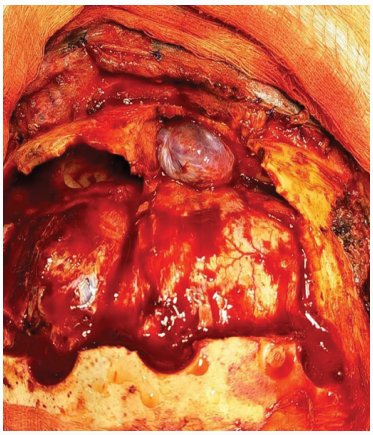

Figure 3: Low bifrontal craniotomy with exposure of the lesion. Herniation content located inside the frontal sinus prior to meningeal resection.

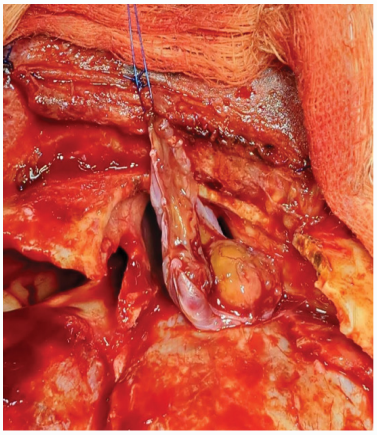

Figure 4: Excision of the herniation. Opening of the lesion with exposure of the cortical tissue sent for analysis.

To isolate the sinus to the exposed cranial cavity, a pericranial flap was realized. Hemostasis was thoroughly checked, addressing any bleeding spots through cauterization, followed by the application of prolene stitches at the excision site (Figure 5). Finally, the osteotomy was performed (Figure 6).

Discussion

Encephaloceles may originate from congenital or acquired causes. Anterior congenital ones, most frequently found in Southeast Asia, are typically a result of neural tube closure defects [2,3]. Regarding the etiology of acquired Encephaloceles, they can be classified as traumatic, non-traumatic (such as in cases of intense osteitis or tumors) and spontaneous [1]. More than 90% of acquired Encephaloceles happen due to traumatic events, followed by hydrocephalus and tumors (that

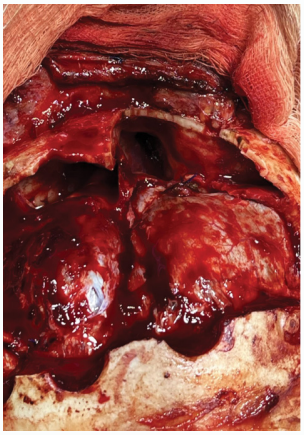

Figure 5: Prolene stitch on excision area. Prolene suture after excision of the lesion.

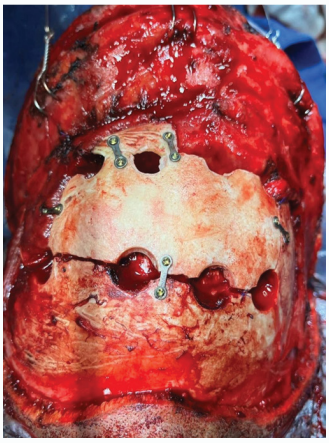

Figure 6: Cranioplasty showing exclusion of the frontal sinus with pedicled periosteum.

can directly erode the cranial bones or indirectly generate herniation by the means of the raise in intracranial pressure) [4].

The range of symptoms of Encephaloceles includes unilateral CSF rhinorrhea (such as in the patient described) that may present the "reservoir sign", which is the increased discharge of the CSF fluid stored in the sinuses after getting up [1]. Other possibilities are recurrent meningitis (e.g. those reported in references [5-7]) and, especially in temporal herniations, the occurrence of seizures [2]. Other symptoms may vary in accordance with the affected area. In the case published by Arun and collaborators [3], for instance, the patient presented with a headache and decreased visual acuity.

Patients who present important rhinorrhea commonly undergo, at the first moment, an otorhinolaryngology evaluation. Important rhinorrhea can lead diagnosis into an investigation of complicated rhinosinusitis (which was the case of our patient and those presented by 1 and 2) and result in the realization of Computed Tomography (CT). Since the main causes of sinus opacification are also otorhinolaryngological (such as severe rhinosinusitis and cysts), that may delay definitive diagnosis. According to Mantur et al. [8], once suspected a CSF leak, the fluid can be tested for the presence of β-2-transferrin, beta-trace protein or undergo a glucose-oxidase strip test. In the reality where our case was conducted, however, a glucose dosage of the fluid (which indicates high suspicion for the presence of

CSF if 2/3 of blood glucose is present) is usually performed due to its cost-effectiveness. In cases where standart CT or Magnetic Resonance (MR) imaging exams are not sufficient to identify the leak's location or multiple defects are suspected, contrast enhanced CT or MR Cisternography can be indicated [9,10].

In terms of treatment, Encephaloceles have been classically repaired by open surgery with pericranial flap closure, as performed in the described case. Although endoscopic treatment of frontal sinus CSF leaks and Encephaloceles have been progressively addressed [10,11], with success rates between 88% and 98% for the second condition, open surgery remains the primary choice for consideration in scenarios of higher complexity and difficult approach (e.g. far lateral and superior frontal sinus) [1]. Regarding post-operative concerns, management of rising Intracranial Pressure (ICP) is advised, as interventions such as CSF shunt or drug therapy (e.g., the use of acetazolamide) have been found to have a higher success rate for primary repair (92.82%) compared to cases where no intervention was performed (81.87%) [1].

Conclusion

Acquired frontal sinus Encephaloceles are rare and delayed diagnosis, often resulting from a prior suspicion of rhinosinusitis, can lead to critical scenarios such as meningoencephalitis. In the described case, in which the encephalocele occurrence happened approximately ten years after head trauma, the possibility of an occurrence etiologically disassociated can be considered. Nevertheless, a direct traumatic lesion or a skull fragilization and posterior raise in ICP pressure causing the fistula remain as the principal hypothesis. Finally, it is worth noting that comparing the levels of glucose in the secretion and in the blood can be a cost-effective alternative for verifying leaks in cases where there is a high suspicion.

References

1. Knappe LB. Frontal sinus meningoencephalocele presenting with spontaneous cerebrospinal fluid leak. Otolaryngol Case Rep. 2021;21:100353.
2. Gressot LV, Patel AJ, Kitagawa RS, Goodman JC, Gopinath SP. Frontal sinus encephalocele: Case report and review of literature. Clin Neurol Neurosurg. 2013;115(10):2174-7.
3. Singh AK, Upadhyaya DN. Sincipital encephaloceles. J Craniofac Surg. 2009;20 (Suppl 2):1851-5.
4. Yilmaz C, Gulsen S, Altinors N, Caner H. Rhinorrhoea from a frontal encephalocele after reduction of high intracranial pressure. Acta Neurochir (Wien). 2008;150(12):1307-8.
5. Gumussoy M, Ugur O, Cukurova I, Uluyol S. Recurrent meningitis and frontal encephalocele as delayed complications of craniofacial trauma. J Craniofac Surg. 2014;25(2):529-30.
6. Cullu N, Deveer M, Karakas E, Karakas O, Bozkus F, Celik B. Traumatic Fronto-ethmoidal Encephalocele: a rare case. Eurasian J Med. 2015;47(1):69-71.
7. Sengupta RP, Garvan N. Recurrent fulminating meningitis 20 years after head injury. Case report. J Neurosurg. 1974;41(6):758-61.
8. Mantur M, Łukaszewicz-Zajac M, Mroczko B, Kulłakowska A, Ganslandt O, Kemona H, et al. Cerebrospinal fluid leakage-Reliable diagnostic methods. Clin Chim Acta. 2011;412(11-12):837-40.
9. Severson M, Schaurich CG, Strecker-McGraw MK. Cerebrospinal Fluid Leak. Treasure Island (FL): StatPearls Publishing. 2023.
10. Jones V, Virgin F, Riley K, Woodworth BA. Changing paradigms in frontal sinus cerebrospinal fluid leak repair. Int Forum Allergy Rhinol. 2012;2(3):227-32.
11. Illing EA, Woodworth BA. Management of Frontal Sinus Cerebrospinal Fluid Leaks and Encephaloceles. Otolaryngol Clin North Am. 2016;49(4):1035-50.