World Journal of Clinical Case Reports and Case Series

Case Report

Full Endoscopic Debridement and Drainage for Multilevel Spinal Epidural Abscess: A Case Report and Literature Review

*Lu YM, Yu CH and Wu HK**

Department of Orthopedic Surgery, TaoYuan General Hospital, Minister of Health and Welfare, Taiwan

Abstract

Background: Multilevel Spinal Epidural Abscess (SEA) is a rare and challenging disease. Delayed diagnosis and inadequate intervention may lead to irreversible paraplegia or even death. However, its insidious presentation and variable progression pattern makes early precise diagnosis challenging.

Purpose: To our knowledge, there is no article regarding to multi-level SEA treated with full endoscopic debridement. The aim of this study is to report our experience on full endoscope debridement and drainage and tried to optimize the diagnosis pattern and operative timing by reviewing relative articles.

Study design/setting: Case report and literature review

Result: We treated this case who suffered from multilevel spinal epidural abscess ranging from cervicothoracic junction to sacrum successfully with Full Endoscopic Debridement and Drainage (FEDD) without any instrumentation.

Conclusion: FEDD provided a management option with minimal tissue destruction, which encouraged earlier surgical intervention, and then possible better outcome.

Keywords: Full endoscopic debridement and drainage; Epidural abscess; Spondylodiscitis; Spine infection; Neurosurgery

Introduction

Spinal Epidural Abscess (SEA) is a potentially devastating infectious disease that delay diagnosis and treatment may lead to paralysis and even death. However, its insidious presentation and variable progression pattern makes early precise diagnosis challenging. It is reported that around 75% of patients who were eventually diagnosed with SEA have significant diagnostic delays, multiple emergency department visits, admissions without definite diagnosis or delayed longer than 24 hours to a definitive diagnostic study [1]. Besides, the incidence of spinal epidural abscess increases to nearly 10 cases per 10,000 hospital admissions at large tertiary referral centers in recent decades, which was reported as 0.2-1.2/10,000 between 1930 to 1975 [1,2].

The timing of intervention has also bothered many clinical physicians for a long time. The destruction of bony and soft tissue stability, reinfection rate with possible instrumented fixation, and other para-operative complications withdraw not only operators but also patients. Recently, endoscopic surgery becomes more popular. The characteristic of minimal invasion minimizes the operative complication and create much possibility.

To our knowledge, there is no article regarding to multi-level SEA treated with full endoscopic debridement. The aim of this study is to report our experience on full endoscope debridement and drainage and tried to optimize the diagnosis pattern and operative timing by reviewing relative articles.

Case Presentation

A 46-year-old male patient with the underlying disease of type two diabetes mellitus came to our clinic with chief complaint of low back pain for one month. In recent 1 week his pain aggravated accompanied with bilateral lower legs weakness. Besides, neck pain with soreness was also noted by patient. He denied any trauma history, intravenous drug use, or HIV infection. Physical examination revealed lower back tenderness, bilateral thigh and calf paresthesia, and bilateral lower limbs decreased muscle power (Table 1). Positive spurling test but negative Hoffman's sign was noted. Laboratory data showed neutrophil-dominant leukocytosis (WBC: 11890/μL, neutrophil: 86.8%), elevated CRP (15.5 mg/dL) and blood culture showed *Streptococcus* spp. Plain x-ray of spine showed mild spurs formation at T2 and T3 level (Figure 1). Chest and abdomen Computed Tomography (CT) with/without contrast showed a hypointense mass surrounded with hyperintense rim over left psoas muscle (Figure 2). With the impression of left psoas abscess, which may be accompanied with spondylodiskitis, we arranged thoracolumbar spine MRI and found posterior epidural abscess ranging from T11 to S1 (Figure 3). We repeat whole spine MRI including upper thoracic and cervical spine to confirm the extent of epidural abscess which reveal epidural abscess involving from cervicothoracic junction to S1 (Figure 4). With the impression of multilevel spinal epidural abscess (T2-S1) with left psoas abscess complicated with bilateral lower limbs

Citation: Lu YM, Yu CH, Wu HK. Full Endoscopic Debridement and Drainage for Multilevel Spinal Epidural Abscess: A Case Report and Literature Review. World J Clin Case Rep Case Ser. 2022;2(1):1006.

Publisher Name: Medtext Publications LLC

Manuscript compiled: Jul 21st, 2022

***Corresponding author:** Hung-Kang Wu, Department of Orthopedic Surgery, TaoYuan General Hospital, Minister of Health and Welfare, No.1492, Zhongshan Rd, Taoyuan Dist, Taoyuan City 330, Taiwan, Tel: +886-3-3699721; Ext: 8511; E-mail: wuhungkang@gmail.com

Table 1: Manual Muscle Test (MMT) of lower limbs and DTR.

	Right	Left
Hip flexion	4	3
Knee extension	4	4
Ankle dorsiflexion	4	4
Big toe dorsiflexion	4	4
Ankle plantar flexion	4	4
DTR (knee)	++	++
DTR (Ankle)	+	+

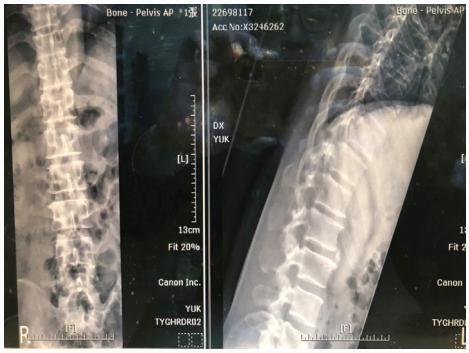

Figure 1: Plain T-L spine AP and lateral view.

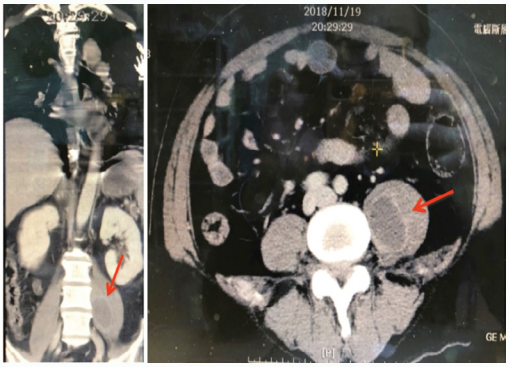

Figure 2: Chest and abdomen CT with contrast; around 5 cm × 3 cm abscess at left psoas muscle (red arrow).

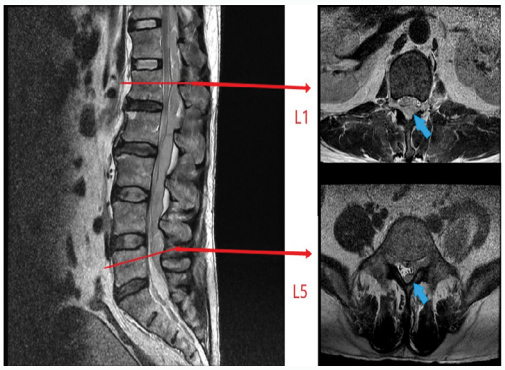

Figure 3: TL spine MRI: on the left hand is the T2W sagittal view and on the right hand is the T2W axial view, which showed posterior epidural abscess with spinal cord compression (blue arrow).

Figure 4: Whole spine MRI T2W image.

Figure 5: The skin markings for portals.

motor weakness, we arranged Full-Endoscopic Debridement and Drainage (FEDD) with three-portals strategies: first interlaminar portal from L1/2 and second interlaminar portal from L4/5 were made for epidural abscess, and the third transforaminal portal from left side of L2/3 for psoas abscess (Figures 5 and 6). The FEDD was performed smoothly within 150 mins. Two 1/8 inches Hemovac drainage tubes were inserted *via* two interlaminar portals and one 1/4 inches Hemovac drainage tube was inserted *via*. L2/3 transforaminal portal (Figure 7). Two weeks after operation, patient regain full lower limbs muscle power. However, patient still complained of back pain and the CRP partially decreased (CRP: 15.54 mg/dL to >9.9 mg/dL) so that we arranged follow-up whole spine MRI which

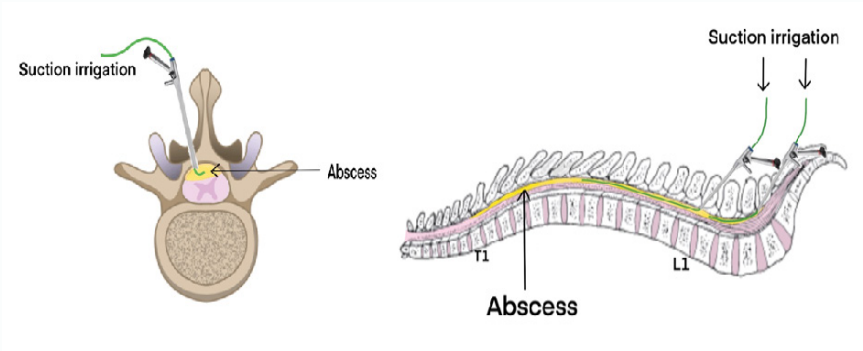

Figure 6: Interlaminar portals of FEDD. The upper diagram explained the axial view of interlaminar portal in single level of FEDD; the lower diagram explained the sagittal view of interlaminar portals of FEDD in our case.

Figure 7: Post-OP picture with three hemovac drainage tube.

Figure 8: Whole spine MRI image two weeks after operation (PO 2 weeks). Still some remaining psoas abscess and new developing spondylodiscitis over L3/4 were noted.

revealed little psoas abscess remaining and newly developing L3/4 spondylodiskitis (Figure 8). We arranged a second operation 3 weeks after first operation. Transforaminal percutaneous endoscopic lumbar debridement and drainage from left L3/4 with psoas abscess drainage was performed within 40 min this time (Figure 9). After second operation, patient's back pain improved much. With rehabilitation program, he could sit and ambulate with walker and be discharged 2 weeks after second operation (PO 2 weeks). Another 2 weeks later (PO 4 weeks) he freely walked back to our clinic without walker. CRP test at clinic on PO 4 weeks was 1.2 mg/dL.

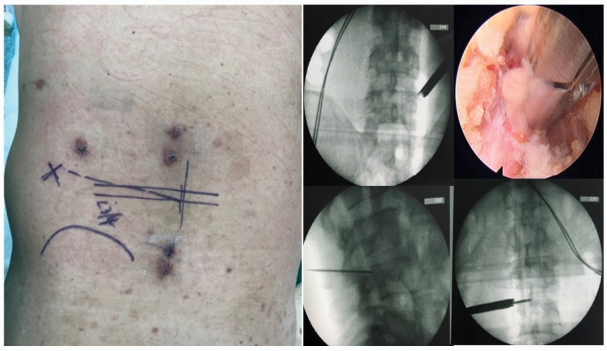

Figure 9: Skin marking and OP picture for second operation.

Discussion

Risk factors

An incidence of SEA has two main predisposing dimensions: the high potential to developing bacteriemia and locus minoris resistentiae for bacteria seeding (Table 2). The high potential to developing bacteremia, which can be considered as systemic risk factors included old age, obesity, diabetes mellitus, end stage renal disease, malignancy, injection drug use, alcoholism, long-time venous catheter placement (e.g., hemodialysis, chemotherapy, intravenous nutrition), or pre-existing infection focus (e.g., diabetic foot ulcers) [1-3]. Locus minoris resistentiae, referred to a body region more vulnerable than others, can be considered as local spinal risk factors. Degenerated disc spaces, large osteophytes, chronically hypertrophied facet joints, and recent spinal instrument were reported as targets of hematogenous bacterial seeding [3]. Therefore, those patients with underlying degenerative spine changes and systemic comorbidities by which predispose them to transient bacteremia were vulnerable to SEA [1].

Clinical manifestation

An established four-stage theory well outlined the progression of disease: Stage 1, focal pain at the level of the affected spine. Back pain at the affected level is the most common and early symptom, which was presented in 70% to 75% of the patients with SEA [1,2,4,5]. Based on the involved levels, the pattern of pain may vary from focal pain with tenderness to diffuse back pain. Fever and local tenderness may also be noted during this stage [6]. Stage 2, nerve-root pain radiating from the involved spinal area. As the SEA progression, symptoms caused by nerve root compression may present subsequently.

Table 2: Risk factors for developing Spinal Epidural Abscess (SEA).

Risk factors for bacteremia	Local spinal risk factors
Old age	Degenerated disc spaces
Obesity	Large osteophytes
Diabetes mellitus	Hypertrophied facet joints
End stage renal disease	Recent spinal instrument
Malignancy	
Injection Drug Use (IDU)	
Alcoholism	
Venous catheter placement (hemodialysis, chemotherapy, IV nutrition)	
Pre-existing infection focus (diabetic foot ulcers)	

Patients with cervical or lumbar abscess usually suffered from neck pain radiating to arms or back pain radiating to legs, respectively. Those patients with thoracic abscess may even present the chest or abdomen discomfort as chief complaint, which sometimes confused the physicians and caused misdiagnosis. Stage 3, neurologic deficit, in this stage, sensory deficit, motor weakness, and bladder and bowel dysfunction may present. It was hypothesized that lumbar epidural abscess below the conus was less vulnerable to spinal cord injury due to relatively abundant epidural space. In contrast, the less abundant epidural space in the cervical and thoracic spine may cause these areas more vulnerable to spinal cord injury, resulting neurologic deficit [2]. Stage 4, paralysis, mostly paraplegia.

The classical triad of fever, back pain, and neurologic deficit might give clinical physicians a hint to suspect SEA. However, the classic triads only present in a minority of patient, around 10% to 30 % on initial presentation, and it correlated with advanced stage of SEA progression.

Though the data from different articles are highly variable, the progression between these stages is generally rapid. Based on Dr. Houston's review in 2019, it takes about 3 days from stage 1 to stage 2 (local pain to nerve root pain), around 4.5 days from stage 2 to stage 3 (nerve root pain to motor weakness), and approximately 24 hours from stage 3 to stage 4. After 24-36 hours of paraplegia (stage 4), the probability of recovery is very low. Therefore, neurologic deficit is a significant "red flag" for physicians to make a timely diagnosis and appropriate management [6-8].

Diagnosis

The diagnosis of spinal epidural abscess is suspected with clinical presentation in high-risk patients, supported with correlative laboratory data and image findings, and confirmed by drainage [5].

Lab

Though laboratory data such as leukocytosis and elevated inflammatory markers, C-Reactive Protein (CRP) and Erythrocyte Sediment Rate (ESR), may be predictive values in disease severity in established SEA, they are not specific for diagnosis [2]. The value of CSF examination is also limited. High level of protein and pleocytosis in CSF analysis can only stand for para-meningeal infection or inflammation but not specific for epidural infection. CSF gram stain are usually negative and CSF cultures are positive in less than 25% samples [2,5]. Furthermore, lumbar puncture may spread the pathogen to subdural or subarachnoid space *via* the needle, causing subdural infection or meningitis. Because of the scanty information provided by CSF and the potential risk, we suggested that lumbar puncture should not be done routinely. Fortunately, blood culture revealed the pathogen in almost all patients whose CSF culture showed positive; further decrease the necessity of lumbar puncture. The most common pathogen obtained by CSF or blood culture in SEA patients is *Staphylococcus aureus*, around 60% [5]. The presence of *S. aureus* cannot help us to establish the infection focus because it is also the common pathogen in other infectious condition such as osteomyelitis, diskitis, cellulitis, and endocarditis.

Image

Gadolinium-enhanced MRI is the best image tool for SEA with a sensitivity and specificity greater than 90% [1,2,5]. Though CT myelography has the similar sensitivity to MRI, it is more invasive so that it has the risk of spreading the pathogen to subdural or subarachnoid space [2]. The abscess revealed iso-intensity or hypo-intensity to the spinal cord on T1-weighted MRI images and hyper-intensity to spinal cord on T2-weighted MRI images. The gadolinium contrast helps us to distinguish SEA from an epidural phlegmon. Diffuse enhanced signal is more likely seen in phlegmonous inflammation due to lacking a purulent necrotic center. In contrast, an abscess is more likely appeared a rim enhancing hypointense collection on the T1-weighted images, which represents the necrotic center of the abscess. Generally, intervertebral disc space infections because ventral SEA and infections arise from facet joint cause dorsal SEA. However, the longitudinal extension of the abscess circumferentially around the cord can obliterate the above categorization [1].

Management

Surgical decompression and evacuation have long been considered as the primary management of SEA, especially in the setting of neurologic deficit. However, the risk of spinal surgery in patients with old age or poor medical condition sometimes hang our backs. Hence, though still controversial, conservative treatment still had the role play in selected patients.

Conservative treatment with systemic antibiotics with or without image-guided drainage could be considered in patients with intact neurologic status and spinal instability, multiple comorbidities, pan-spinal involvement, or paralysis more than 72 hours [2,9]. The outcome varies a lot between literatures [2,9-12]. Physician should pay more attention to patients who received conservative treatment. Clinical deterioration such as worsen lab data, the appearance of neurologic deficit, or even paraplegia means failure of non-operative treatment and sometimes cause poor recovery ability to motor status [11]. Besides, conservative treatment failure may also lead to sepsis, bone loss, and possible bacterial resistance owing to protracted antibiotics use.

The choice of surgical management depends on the location of the abscess, the extent of involvement of the vertebral body, and the characteristic of abscess content [1,2,4,5,10,11,13]. Laminotomy or hemilaminectomy is preferred for the setting of liquid abscess with free-flow pus situated posterior to the thecal sac. This approach preserved the paraspinal musculature and interspinous ligaments which provided much spinal stability. Laminectomy with or without instrumented fusion is considered for solid phlegmatic component and multilevel involvement. Instrumented fusion provided better spinal stability after decompression, lower risk of post-operative kyphosis, and early mobilization, but associated with higher rates of blood transfusion and the susceptibility of continued infection. Diskectomy or corpectomy with possible implant fixation may be required when anterior elements are affected. A combined anterior and posterior approach may be needed for large extent procedure, which suffered patients and operators a lot.

Full-Endoscopic Debridement and Drainage (FEDD)

In recent years, early intervention with Full Endoscopic Debridement and Drainage (FEDD) is gaining more popularity treating spinal infection [14]. Minimal invasive approach with endoscope provided less destruction of bony and soft tissue damage, leading to much better post-operative spinal stability and lower approach-related complication. Markedly reduced surgical wound pain compared to open surgery significantly reduces post-operative analgesic consumption and encourages early ambulation. Compared with CT-guided biopsy, FEDD surgery could collect more specimens, including the abscess, disc materials, and necrotic tissue, under direct vision, leading to higher culture rate and biopsy successful rate [14,15].

In multi-level spinal epidural abscess, just like our case in this article, we could consider multi-portal FEDD instead of conventional open debridement. Less invasive destruction, lower complication rate, less instrument fixation needed, and higher culture rate encourage earlier intervention timing than we used to be. Even if the debridement failed, earlier culture result still helps a lot. Besides, this patient also suffered from concomitant spondylodiskitis and psoas abscess. If we treated this patient with traditional anterior open approach, multiple incisions, large extent soft tissue damage, the need of changing position, and long operation time may make things much more complicated. With endoscopic surgery, we could approach epidural space, intervertebral disk, and psoas muscle in the same prone position *via* two main approach transforaminal approach and interlaminar approach based on the lesion site and operator's preference [14].

Limitation

Though several articles have shown much advantage of FEDD, we still need further studies in large randomized controlled trials comparing the short-term and long-term outcome between conservative treatment, FEDD, and open surgical intervention.

Conclusion

Spinal epidural abscess is a rare but devastating disease. Delayed diagnosis and late timing of adequate intervention may cause life-time paralysis or even death. The timing and approach for multi-level SEA is even more challenging for operator. FEDD provided a management option with minimal tissue destruction, which encouraged earlier surgical intervention, and then possible better outcome.

References

1. Babic M, Simpfendorfer CS, Berbari EF. Update on spinal epidural abscess. Curr Opin Infect Dis. 2019;32(3):265-71.
2. Schwab JH, Shah AA. Spinal Epidural Abscess: Diagnosis, Management, and Outcomes. J Am Acad Orthop Surg. 2020;28(21):e929-38.
3. Vakili M, Crum-Cianflone NF. Spinal Epidural Abscess: A Series of 101 Cases. Am J Med. 2017;130(12):1458-63.
4. Chow F. Brain and Spinal Epidural Abscess. Continuum (Minneap Minn). 2018;24(5, Neuroinfectious Disease):1327-48.
5. Darouiche RO. Spinal Epidural Abscess. N Engl J Med. 2006;355(19):2012-20.
6. Spennato P, Renedo D, Cascone D, Mirone G, Imperato A, Martino GD, et al. Spinal epidural abscess in children: a case-based review. Childs Nerv Syst. 2020;36(7):1385-92.
7. Houston R, Gagliardo C, Vassallo S, Wynne PJ, Mazzola CA. Spinal Epidural Abscess in Children: Case Report and Review of the Literature. World Neurosurg. 2019;126:453-60.
8. Mohanty CB, Fieggen G, Deopujari CE. Pediatric spinal infections-a review of non-tuberculous infections. Childs Nerv Syst. 2018;34(10):1947-56.
9. Arko Lt, Quach E, Nguyen V, Chang D, Sukul V, Kim BS. Medical and surgical management of spinal epidural abscess: a systematic review. Neurosurg Focus. 2014;37(2):E4.
10. Curry WT, Hoh BL, Amin-Hanjani S, Eskandar EN. Spinal epidural abscess: clinical presentation, management, and outcome. Surg Neurol. 2005;63(4):364-71; discussion 371.
11. Patel AR, Alton TB, Bransford RJ, Lee MJ, Bellabarba CB, Chapman JR. Spinal epidural abscesses: risk factors, medical versus surgical management, a retrospective review of 128 cases. Spine J. 2014;14(2):326-30.
12. Tuchman A, Pham M, Hsieh PC. The indications and timing for operative management of spinal epidural abscess: literature review and treatment algorithm. Neurosurg Focus. 2014;37(2):E8.
13. Desai V, Gonda D, Ryan SL, Briceno V, Lam SK, Luerssen LG, et al. The effect of weekend and after-hours surgery on morbidity and mortality rates in pediatric neurosurgery patients. J Neurosurg Pediatr. 2015;16(6):726-31.
14. Yu CH. Full-endoscopic debridement and drainage treating spine infection and psoas muscle abscess. J Spine Surg. 2020;6(2):415-23.
15. Yang SC, Fu TS, Chen LH, Chen WJ, Tu YK. Identifying pathogens of spondylodiscitis: percutaneous endoscopy or CT-guided biopsy. Clin Orthop Relat Res. 2008;466(12):3086-92.