The Clinical Ophthalmologist Journal

ISSN: 2692-7985

Research Article

Functional Recovery of Vision in Retinitis Pigmentosa by Omental Transplant

VK Agarwal[1], Harry S Goldsmith[2], Jyoti Bindal[3], Sujata Bhargava[4] and Swati Bhargava[5]*

[1]*MGM Medical College, India*

[2]*Department of General Surgery, University of California, USA*

[3]*Sri Aurobindo University, India*

[4]*SAIMS Medical College, India*

[5]*M.G.M Medical College, India*

Abstract

Background: Direct vascular bypass surgery is not possible in avascular diseases of retina including Retinitis Pigmentosa (RP) and macular degeneration. We describe a new technique of omental transplantation to the eye in patients of Retinitis Pigmentosa. Omentum is known for its Angiogenic property having CD34+ and Ly-1+B stem cells which migrate and promote angiogenesis. We have previously described a safe technique to lengthen omentum in continuity for limb salvage (Agarwal technique). Goldsmith H.S et al. have reported in an experimental study that intact transplanted omentum refills the retinal choroidal blood vessels.

Study design: A modification of Agarwal technique was used to transplant pedicled omentum to the eyes in 127 consecutive cases of RP presenting in 2009 to 2019. Omentum was mobilized on a gastro colic artery. This pedicled omentum via subcutaneous tunnel in the chest, neck, behind the ear and to the forehead, was inserted sub conjunctively in the posterior half of the eye ball. Out of 127 patients, 120 patients were available for regular follow up for one year and were included in the study.

Results: Results were dependent on pre-operative Visual Acuity (V/A). In patients with 20/120, 20/80 and 20/60 the majority of improvement occurred after 6 months and no further significant improvement beyond 6 months. Majority of the cases having 20/200 took one year to improve to 20/120. Patients with pre op vision of 20/40, 50% achieved full restoration at the end of 1 year and the rest have improvement to 20/30. All the patients presenting with 20/30 pre op vision had full vision restored (20/20) by the end of 1 year. Field of vision improved by 90°. Patients having vision less than finger counting (FC)2 did not improve however in this group no further loss of vision was observed in 66% cases.

ICG angiogram showed increased perfusion in the choroidal vessels. There was no change seen in florescence angiogram, color Doppler and ERG.

Conclusion: 127 RP patients underwent omental transplantation to the eye of which, 120 patients were followed for a period of 1year. Visual acuity, field of vision, night blindness and color vision improved in cases having more than 20/200 V/A preoperatively. No further deterioration was noted in all patients with a pre op vision of more than FC 2'.

Keywords: Retinitis pigmentosa; Macular degeneration; Optic atrophy; Night blindness; Low vision; Pedicle omentopexy

Introduction

Anatomically the eye consists of two chambers - anterior and posterior. The anterior chamber consists of cornea and lens. The treatment of corneal and lens pathology is well established. In relation to the posterior chamber, the retinal ischemic disease for example Retinitis Pigmentosa (RP) leads to degeneration of retinal epithelium, converting rods and cones in the retina to bony corpuscles.

Citation: Agarwal VK, Goldsmith HS, Bindal J, Bhargava S, Bhargava S. Functional Recovery of Vision in Retinitis Pigmentosa by Omental Transplant Clin Ophthalmol J. 2021;2(1):1020.

Publisher Name: Medtext Publications LLC

Manuscript compiled: Sep 03rd, 2021

***Corresponding author:** VK Agarwal, Sanjeevani Nursing Home 1, Phadnis Colony, AB Road, Indore, 452009, India, Tel: +91-731-2542020; E-mail: dr_vkagarwal@rediffmail.com

In literature various treatments have been described to increase the vascularity of the retina in conditions like Age Related Macular Degeneration (ARMD), Optic Atrophy etc. These include medical and surgical treatments. Medical treatments include drugs like antioxidants, ribonucleic acid, hydrocortisone, and placental extracts.

Surgical procedures including Facial translocation, macular Buckle, implant radiotherapy, transpupillary thermo therapy, photodynamic therapy, artificial vision prosthesis [1], are not widely accepted due to technical difficulties, complications and poor long-term results. Heckenlively and Janet [2] conclude that treatments for ocular-only forms of RP are currently unavailable. As currently there is no proven available medical or surgical treatment of these diseases, clinicians helplessly see patients lose the vision and become blind.

Research to develop methods to revascularize retina has been going on in several countries, but without any success. One of the reasons for the failure is lack of appreciation of unique anatomy and physiology of the retina. Retina is composed of several layers. The outer surface of the retina is formed by pigment cells, and the inner layer is composed of rods and cones, which is attached to the choroid

by loose tissue lamina cribrosa (Figure 1).

Retinitis Pigmentosa is a hereditary disorder affecting choriocapillaris in lamina cribrosa (nourishing rods and cones) which are either reduced in number, absent or abnormal [3].

The central retinal artery makes no contribution to the blood supply of optic nerve and the region of the lamina cribrosa which is served by choroid capillaries which are fine branches of the posterior ciliary arteries lying outside the sclera [4] (Figure 2), which needs to be bypassed in order to reestablish the blood supply of attenuated capillaries. The direct reconstructive surgery is not feasible even at the level of posterior short ciliary artery. Hence alternative techniques need to be developed.

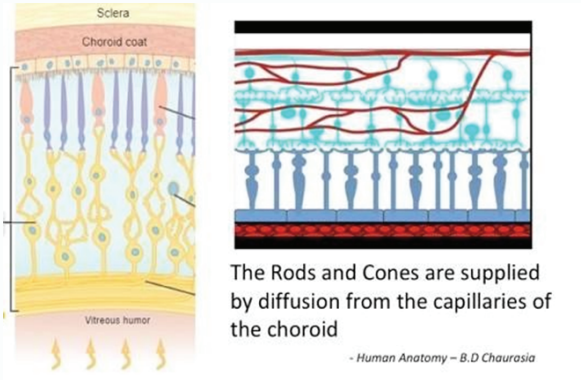

Figure 1: Nutrition to Rods and Cones.

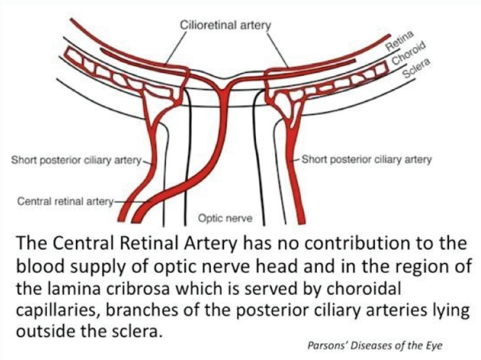

Figure 2: Blood Supply.

From the time of Hippocrates, the greater omentum is known for its angiogenic properties, as [5] demonstrated in the revascularization of the intestine and the other abdominal organs. Weinberg experiment has shown that omental graft forms biological anastomosis with host vessels in ischaemic tissue by throwing capillaries in 3 to 8 days. Subsequent studies have shown omentum is full of omnipotent stem cells having power to migrate. Garcia-Gomez et al. [6,7], reported human omental, CD+34 stem cells could be responsible for the clinical benefit of omental transplantation by promoting angiogenesis and synthesizing angiogenic growth factor facilitating revascularization of injured tissues. Solvoson N, Kearney JF7 found fetal omentum to be an important site of B-cell generation in humans.

With the knowledge of this unique angiogenic property of omentum, we have used the omentum to revascularise ischaemic tissues outside abdomen by developing a lengthening technique (Agarwal Technique) [8]. In end stage ischaemic diseases of the limbs, for e.g. in Buerger's disease or diabetic gangrene, where direct revascularization surgery is not feasible, the only option remains amputation. We have been able to salvage limbs in 85% of cases presenting with end stage ischaemic disease (15 years follow up) [8].

As similar situation exists in avascular condition of retina, Goldsmith et al. [9] in an experimental study found that intact omentum can be transplanted into the eye and reported development of vascular connection between omental capillaries and choroid retinal vessels. On the basis of above experimental studies and our clinical experience of omental transplantation, we have carried out omental transplant to the eye, (extending the Agrawal Technique [8]) by transferring a pedicle omental graft into the eye.

Methods

One hundred seven consecutive patients of RP presenting between the years 2009 to 2019 were operated in both the eyes by this procedure. Out of 127 patients, 120 were available for regular follow up of 6 months to 1 year and hence were included in the current study.

The diagnosis of RP is traditionally based on the history and clinical examination. Patients aged between 14 to 55 years presented with history of night blindness, loss of visual field, acuity and symptoms of pigment retinopathy. Positive family history was felt to be conclusive. Ophthalmoscopic examination revealed sub retinal clumps of pigment deposition, and bony spicules. A tangents visual field examination confirmed the diagnosis and was used as a modality to follow the patient.

Observation

The mean age was 33.53 years (range 14 to 55 years), 88 patients (73.33%) were male and 32 patients (26.66%) female. While all patients presented with complaints of night blindness, 72 patients (60%) also noticed dimness of vision & color, 36 patients (30%) complained of narrowing of visual field and only 12 patients (10%) have noticed light flashes (Table 1).

Pre-Operative Visual Acuity

Visual Acuity (V/A) examination revealed vision less than Counting Finger 2 feet (<CF2') in 16 eyes and >CF2' in 8 eyes. 20/200 in 48 eyes, 20/120 in 12 eyes, 20/80 in 48 eyes, 20/60 in 72 eyes. Visual acuity 20/40 and 20/30 were noted in 8 eyes and 28 eyes respectively (Table 2).

Clinical Signs

Ophthalmic examination showed bony corpuscles pigmentation in 188 (78.33%) eyes while atrophic maculopathy and waxy pale disc was noted in 32 (13.33%) and 16 (6.66%) eyes respectively (Table 3).

Field of Vision

Pre-operative visual field examination was done on static automatic field analyzer which revealed a field of vision of 20 degree in 80 (33.33%) eyes while 96 (40%) eyes had the field of only 10-degree. In 40 (16.66%) eyes visual field was much narrowed only central 5° while in 24 (10%) it was not recordable (Table 4).

Investigations Performed

- Color Doppler study

  Color Doppler study showed well appreciable retrobulbar vascularity and arterial flow in all the cases (Table 5).

Table 1: Symptoms.

Presenting symptoms	No. of patients
Night blindness	120 (100%)
Dimness of vision	72 (60%)
Narrowing of visual field	36 (30%)
Light flashes	12 (10%)

Table 2: Pre-operative visual acuity.

V/A	<CF2'	CF2'	20/200	20/120	20/80	18-Jun	20/40	20/30
No. of eyes	16	8	48	12	48	72	8	28

Table 3: Clinical signs - Ophthalmic findings.

Fundus finding	No. of eyes
Bony corpuscles pigmentation	**188**
Waxy pale disc	**16**
Atrophic maculopathy	**32**

Table 4: Field of vision.

Field of vision	No. of eyes
20 degree	80 (33.33%)
10 degree	96 (40%)
5 degree	40 (16.66%)
Not recordable	24 (10%)

Table 5: Investigations.

Type of investigations	No. of patients
Color Doppler	120
Fluorescein angiography	120
ICG angiogram	120
ERG test	120

- Electroretinogram (ERG)

  ERG test showed extinguished rods and cones response in all the patients which is a typical feature of retinitis pigmentosa.

- Fluorescence angiogram

  Fluorescence angiograph showed narrowed retinal arterioles, bright hyper fluorescence of the choroids indicating diffuse Retinal Pigment Epithelium (RPE) damage. There was no leakage or staining noted in all the patients.

- Indo-Cyanine Green (ICG) angiogram

  ICG angiogram gives the correct picture of choroid vessels showing ischemia of central portion, which include optic disk and macula in all cases.

Operative Procedure

The abdomen was opened by upper midline incision, omentum was examined. It was freed from its attachment to the colon and stomach, preserving the gastroepiploic arch, the omentum was lengthening by tailoring the omental arcade. The right gastroepiploic artery was kept intact while left was cut to give sufficient length (Figure 3).

Keeping attached one end to right gastroepiploic artery, the omentum was brought out of the abdomen near the xiphisternum and then the abdomen was closed. Further skin incisions were made on chest, in neck, behind ear and at the mid forehead. Subcutaneous tunnel was made between the incisions and the omentum was brought out at mid forehead in continuation (Figure 4).

In the eye, the conjunctiva was reflected at the medial angle. A subcutaneous tunnel was created extending from the mid forehead incision to the area of reflected conjunctiva. By lifting muscle, a passage was made laterally through which strips of omentum were pulled in to both the eyes (from mid forehead) and were inserted posterior in the eyeball (Figure 5).

No anastomosis was made between eyeball vessels and omentum. This procedure resulted in revascularization of short ciliary and choroid arteries as the omental vessels encouraged development of new capillaries. These capillaries cross anastomosed between omental and posterior short ciliary, which in turn retrogradely filled choroid vessels (Figure 6). Patients were discharged on the 8th post-operative day.

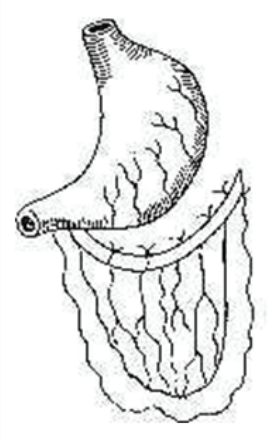

Figure 3: Showing omentum separated from stomach and colon and attached to the stomach by right gastroepiploic artery.

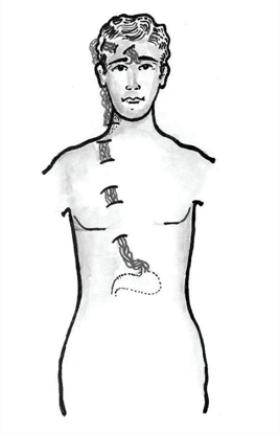

Figure 4: Showing extra abdominal tunnel of omentum to reach eye.

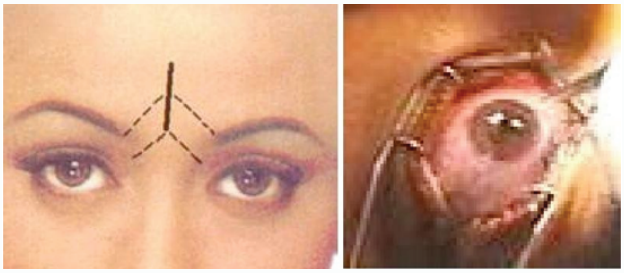

Figure 5: Incision from mid- forehead to conjunctiva, Conjunctiva reflected.

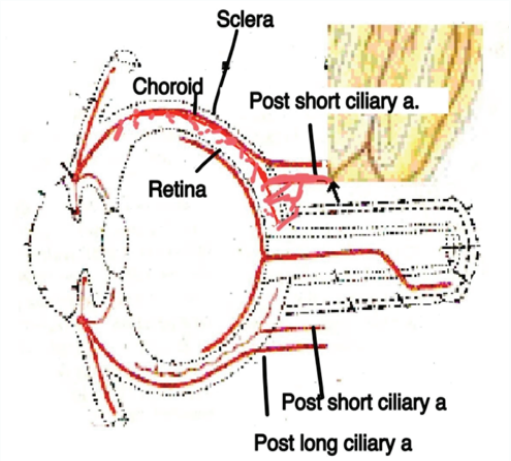

Figure 6: Omentum throwing capillaries which anastomose with posterior short ciliary.

Results

Four main tests which are used for diagnosis management and evaluation of RP are

- Best corrected visual acuity, visual fields,
- Electroretinogram (ERG)
- Fluorescence angiogram
- Indo-Cyanine Green (ICG) angiogram

Visual acuity assessment after 6 months

Post operative assessment of Best-Corrected Visual Acuity (BCVA), was very promising. 114 eyes showed one-line improvement. 60 eyes showed 2-lines and 14 eyes showed a 3-line improvement. Improvement was proportionate to pre-operative visual acuity-20/120, 20/80 and 20/60 the majority of improvement occurred after 6 months and no further significant improvement beyond 6 months. Cases having pre op vision of 20/200 took 1-year to improve to 20/120. Patients having vision less than finger counting (FC)2 did not improve however in this group no further loss of vision was observed in 66% cases (Table 6).

Visual acuity assessment after 1 year

There was further improvement noted of one line in 44 eyes and 2 lines or more in 4 eyes. Patients having vision <CF2' vision showed no improvement. 32 eyes having preoperative vision 20/200 (who were not improved at 6 months) showed improvement to 20/120 after 1 year follow up. Visual field test showed improvement after 6 months postoperatively. Cases followed after 1 year showed increased sensitivity of few areas when compared from preoperative fields. Color vision improved in 6 months to 1 year in all 72 cases (Table 7).

Colour doppler

As it records extra ocular circulation, expectedly no significant change is noted.

Electroretinogram (ERG)

ERG is measurement of the response evoked by retina. Karpe [10] reported response was proportionate to the severity of disease. ERG in most of patients of RP is absent, as the rods and cones have degenerated. In all bypass surgery like coronary bypass, the tissue, which has completely degenerated, does not revive. Similarly, degenerated rods cones, which had become bony did not revive, as such much change in ERG is not expected. Results also show that earlier patient presentation results in a better outcome.

Fluorescein angiogram

Fluorescein angiogram gives information of retinal vessels and not of the choroidal vessels. It is helpful in looking at sub-retinal and other types of neovascularisation and establishing the presence of retinal oedema.

It's most important role in the postoperative follow up is to exclude changes in the retinal vessels like microaneurysm, small or big hemorrhages, exudates etc. As the retinal vessels do not anastomose, the risk of increasing circulation in retina was remote. No vascular anomalies were found in the pattern of filling time, AV ratio, hemorrhagic pattern, microaneurysm, or oedema (Figure 7).

ICG angiogram

It gives information on the choroidal vessels (Figure 8). Pre-operatively ICG angiogram shows ischemia of central portion, including optic disk and macula. 6 months post-operatively, the angiogram showed increased choroid vasculature at posterior pole suggestive of increased vascularity of choroids.

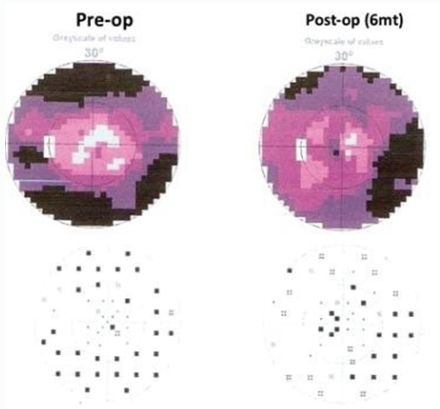

Figure 7: Field of vision.

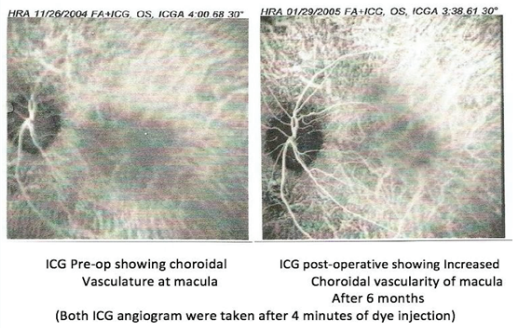

Figure 8: ICG Angiogram.

Table 6: Visual Acuity after 6 Months Postoperatively.

Visual Acuity	Pre-Op	Post-Op no improvement	Further deterioration	Post-Op:1-line improvement	Post-Op:2-line improvement	Post-Op:3- line improvement
<CF 2'	16	16	6 (of the 16)	0		
CF 2'	8			8		
20/200	48	32		16		
20/120	12			6	4	2
20/80	48			28	12	8
20/60	72			24	44	4
20/40	8			8		
20/30	28	4		24		

Table 7: visual acuity after 12 months postoperatively (changes from 6 month follow up).

Visual Acuity	Pre-Op	Further no improvement (from 6-month post op result as in table 6)	Further 1-line improvement (from 6-month post op result as in table 6)	Further 2- line improvement (from 6-month post op result as in table 6)	Note
<CF 2'	16	16	0	0	No eyes noticed any improvement post op
CF 2'	8	4	4	0	4 eyes had an overall 2 line and 4 eyes had 1-line improvement compared to pre op
20/200	48	16	32	0	All eyes had 1- line improvement at 12-month mark compared to pre op vision
20/120	12	12	0	0	No significant change after 12 months over and above changes at 6 months
20/80	48	47	0	1	No significant change after 12 months over and above changes at 6 months
20/60	72	69	0	3	No significant change after 12 months over and above changes at 6 months
20/40	8	4	4	0	4 eyes achieved 20/20 vision at the end of 12 months and 4 eyes achieved a 20/30 vision
20/30	28	24	4	0	All eyes achieved 20/20 vision at the end of 12 months

Complications

All the patients were reviewed by regular follow up for any retinal vascular complication. No vascular anomalies were found in the pattern of filling time i.e. circulation- appearance of dye, AV ratio increase or decrease, any hemorrhagic pattern, microaneurysm. Incision hernia was noted in one case and double vision in three cases, which were corrected by surgery after 6 months.

Discussion

The blood vessels of retina are end-arteries and hence susceptible to diseases like, ARMD, in optic atrophy, choroid sclerosis etc. A reduced vasculature leads to degenerative changes in retinal epithelium and periepithelial pigmentation.

It's always been a challenge for the ophthalmologist to treat deterioration in vision in patients with RP. Historically various treatments including medical and surgical procedures have been tried to increase the vascularity of retina with very limited or no success. Heckenlively [2] concludes that treatments for ocular-only forms of RP are currently unavailable.

Research in this area of medicine has been futile so far. One of the reasons for the failure is that all the attempts were directed towards increasing vascularity of retina either by drugs or by surgical procedures. The basic fact is that rods and cones are nourished by choroidal capillaries in lamina cribrosa. As the central retinal artery makes no contribution to the blood supply in the region of lamina cribrosa and it is supplied only by choroidal capillaries (Parsons Textbook of Diseases of Eye) [4] which are fine branches of posterior short ciliary artery which should be aimed to be bypassed. As direct surgery of the posterior ciliary vessels is not feasible, omental transplantation was performed in this population. It acted as a bypass procedure and resulted in retrograde filling of the choroidal capillaries.

Since ancient times the greater omentum has been attributed with purposeful function and its angiogenic properties. Vineberg AM et al. [5] have shown omental graft throws capillaries which anastomose with the host capillaries in 3 days and form arteriolar anastomosis in 8 days, resulting in retrograde filling.

In a recent study Goldsmith et al. [6] reported presence of CD+34 stem cells obtained in human omentum and concluded, these CD+34 cell population of human omentum could be responsible for the clinical benefit of omental transplantation by promoting angiogenesis and synthesizing angiogenic growth factor to facilitate revascularization of injured tissues. Another study Solvoson and Kearney [7], demonstrated fetal omentum to be an important site of B-cell generation and found that cells simply migrate from one location to other.

With the knowledge of the angiogenic properties of omentum, we have used it to revascularise ischaemic tissues outside abdomen by developing a technique of lengthening it (Agarwal technique [8]), especially where direct revascularization surgery not feasible. In end stage Burgers disease, we have been able to salvage ischemic limbs in 85% cases, in 15-years follow up [8] (Over 800 limbs saved).

Almost similar situation exists in avascular disease of RP where

direct revascularization surgery is not feasible. We have been encouraged by experimental work of Harry Goldsmith [9] who has shown that intact omentum can be safely transposed in eyes. He has demonstrated connections between omental and choroidal and retinal vessels and suggested its clinical application in situation of decreased blood flow in eye by intact omentopexy in eyes. We have employed a modified Agarwal technique for transplanting pedicled (intact) omentum in eye. The omentum was mobilised by Agarwal technique and was transplanted sub-conjunctively in the eyeball. In the omentum due to presence of artery vein and lymphatics, it results in improved drainage in cases of acute or chronic venous and lymphatic obstruction.

Mechanism of Action

The omental strips which are full of arteries and veins, develops new capillaries in the ischemic tissue. These make biological anastomosis with short ciliary vessels and fill choroid vessels in a retrograde fashion nourishing rods and cones. The rods and cones which have not turned into bony spicules are revived following revascularisation. In the first 6 months after the procedure, the maximum benefit is achieved as all the rods and cones which were not previously completely degenerated revive. This results in improved visual acuity and field of vision and most importantly prevents further deterioration of blood supply and thereby loss of vision. As the omentum carries veins it also helps in the drainage of blood.

Conclusion

In cases of RP, vascularity leads to loss of vision. The pedicle omentopexy (Agarwal technique) provides a method of bypass surgery by developing new capillaries8 and arteriolar anastomosis with posterior short ciliary vessels outside sclera which fills choroidal capillaries retrogradely, thereby nourishing rods and cones. The angiogenic property of omentum is due to the presence of the stem cells that have power to migrate. This phenomenon has also been proved clinically in 15-years follow up study in ischemic limbs [8]. 127 consecutive cases of RP underwent pedicle omental transplantation, 120 patients who were followed for a period of one year and were included in the current study. No further deterioration in vision was observed in any patient except for 8 patients who had V/A <CF 2' pre-operatively. Increase in the visual acuity was proportionate to the state of pre-operative vision. Visual acuity, field of vision, night blindness and color vision improved in all cases having a pre-operative vision more than 20/200. There was no improvement in cases with V/A less than CF2'. The field of vision increased after 6 months. Cases followed for over a year showed 90-degree improvement.

It is believed that RP is a genetic condition. Most of the genetic hereditary diseases are managed by treating the effect produced by the genes, either medically or by surgical procedures. We have developed a successful surgical technique for restoring vision in RP without gene therapy.

The described technique does not require intra ocular intervention as the strips of omentum are placed on the eyeball in the sub conjunctival plane on the sclera. This checks any further loss of vision and improves visual acuity and the field of vision. The result is especially more significant as currently there is no effective treatment available to check the deterioration of vision and thereby leading to blindness.

References

1. Peyman GA, Meffert SA, Conway M. Vitreoretinal surgical techniques, London UK, Martin Dunitz Ltd, CRC Press. 2001.
2. John R. Heckenlively, Janet S. Management and treatment of retinitis pigmentosa. JB Lippincott Company. 1998:92.
3. Rayborn ME, Moorhead LC, Hollyfield. A dominantly inherited chorioretinal degeneration resembling sectored Retinitis Pigmentosa. Ophthalmology. 1982;89(12):1441-54.
4. Blood Supply of Eye, Embryology and Anatomy; Parsons diseases of the eye. 19th Ed.
5. Vineberg A, Lwin MM. Fostering a natural artery bybass for disseminated coronary artery disease by perioronary omental strips. Surg Gynec Obstet. 1973;137(4):565-78.
6. Garcia-Gomez I, Goldsmith HS, Angulo A, Prados A, López-Hervás P, Cuevas B, et al. Angiogenic capacity of human omental cells. Neurol Res. 2005;27(8):807-11.
7. Solvason N, Kearney JF. The human fetal omentum: a site of B cell generation. J Exp Med. 1992;175(2):397-404.
8. Agarwal VK. Long term results of omental transplantation in chronic occlusive arterial disease (Buerger's disease) and retinal avascular diseases (retinitis pigmentosa). Int Surg . 2007;92(3):174-83.
9. Goldsmith HS, Chen WF, Palena PV. Intact omentum for ocular vascularisation, Investigative ophthalmology. 1975;14(2):163-5.
10. Karpe G. The basis of clinical electroretinography. Acta Opthal. 1945;23(suppl):1-118.