American Journal of Surgery Case Reports

Clinical Image

Iatrogenic Complete Ureteral Dissection after Retrograde Stenting: Imaging Features

Antonio Vizzuso[1], Sara Piciucchi[1], Giorgia Musacchia[1], Umberto Salomone[2], Roberta Gunelli[2] and Emanuela Giampalma[1,3]*

[1]Department of Radiology, Morgagni-Pierantoni Hospital, Italy

[2]Department of Urology, Forlì-Cesena Hospitals, Italy

[3]Department of Radiology, M. Bufalini Hospital, Italy

Clinical Image

Ureteral stenting represents a widespread procedure aimed to relief the benign or malignant obstructions, to manage urine leakages, and/or to support stone therapy. Complications related to its placement are not so rare, even in presence of modern devices and correct protocol of proceeding [1,2]. Here, we report the imaging findings of a malpositioning with the subsequent management, to our knowledge not yet reported in literature.

A 60-years-old man with history of rectal carcinoma treated with surgery and pelvic radiotherapy developed a left fibrotic ureteral stenosis which was treated with periodical stent replacements. The stent was regularly changed for a ten years period until the last time in which the patient was lost at the follow-up for three years. This lapse was caused by the pandemic outbreak which upset all the waiting lists. So, the patient came to our attention with fever and left flank pain likely induced by the stent obstruction. He underwent a fluoroscopy-guided retrograde double-J stent replacement with a following pyelography showing an apparent correct positioning of the proximal loop in the pelvis with also diffuse irregularity of the parietal wall interpreted as the renal collecting system, ureter and bladder reaction to the chronic presence of the foreign body (Figure 1). One day later, the patient presented with intense flank pain and hydronephrosis at Ultrasound (US) examination. So, he underwent abdominal contrast-enhanced Computed Tomography (CT) scan which confirmed the left hydronephrosis. Moreover, the left stent completely run into the ureteral wall thickness thus, a ureteral dissection was supposed (Figure 2). After a multidisciplinary briefing, the indication to percutaneous nephrostomy catheter placement was given. Access into the renal collecting system was gained with US and fluoroscopic guidance and anterograde pyelography relived the stent "outside" the opacified ureteral lumen confirming the malposition (Figure 3). Then, the stent was removed by cystoscopy and a new double-j stent was placed *via* the anterograde percutaneous access.

Citation: Vizzuso A, Piciucchi S, Musacchia G, Salomone U, Gunelli R, Giampalma E. Iatrogenic Complete Ureteral Dissection after Retrograde Stenting: Imaging Features. Am J Surg Case Rep. 2023;4(1):1054.

Publisher Name: Medtext Publications LLC

Manuscript compiled: Feb 02nd, 2023

***Corresponding author:** Antonio Vizzuso, Radiology Unit, Morgagni-Pierantoni Hospital, Forlì, AUSL Romagna, Italy, Tel: +39-0543-735862; E-mail: antonio.vizzuso26@gmail.com

This case demonstrates how the incidence of periprocedural complications increases as longer the stent remains in place. A prolonged indwelling stent times, in fact increases the risk of urinary tract infection, encrustation with obstruction, stent fracture, ureteral erosion or fistulation and malposition after exchange as in our case [1,2]. The ureteral dissection is a rare condition that, at the urography CT scan or anterograde pyelography, could show imaging findings of double lumen and/or contrast extravasation if the injured mucosa advance towards the full-thickness ureteral wall rupture [3]. In our case, the tear of the inner ureteral layer was probably at the distal end of the ureter and the false lumen was observed only when contrast was injected retrograde or inside it. To our knowledge, it is the first time that a complete ureteral dissection is documented with the particular feature at pyelography of a snake-like catheter twisted around the ureteral lumen and that we labelled as "Asclepius' rod sign".

References

1. Tomer N, Garden E, Small A, Palese M. Ureteral Stent Encrustation: Epidemiology, Pathophysiology, Management and Current Technology. J Urol. 2021;205(1):68-77.
2. Dyer RB, Chen MY, Zagoria RJ, Regan JD, Hood CG, Kavanagh PV. Complications of ureteral stent placement. Radiographics. 2002;22(5):1005-22.
3. Potenta SE, D'Agostino R, Sternberg KM, Tatsumi K, Perusse K. CT Urography for Evaluation of the Ureter. Radiographics. 2015;35(3):709-26.

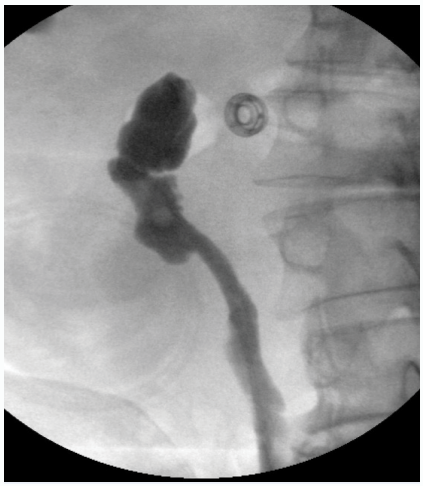

Figure 1: The retrograde pyelogram after stent placement showed a cavity with irregular parietal wall consistent with the false lumen creation along pelvis and ureter. Note the absente visualization of the collecting system as further suspicion feature of ureteral dissection. Patient is in prone position.

Figure 2: Axial venous contrast-enhanced CT scans at the pelvis (A), upper (B) and middle ureter (C) showed the stent (red circle in A and red arrows in B-C) not in the lumen. In A note the atrophic left kidney probably due to chronic obstruction hydronephrosis.

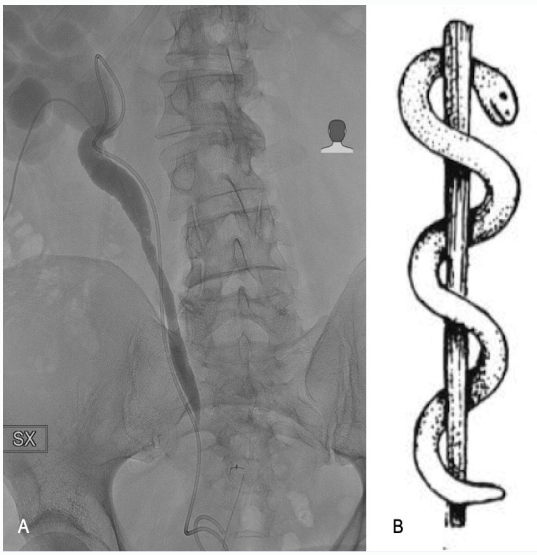

Figure 3: (A). The anterograde pyelogram after percutaneous nephrostomy allowed to opacified correctly the excretory system and to confirm that the stent was located externally the lumen. Patient is in prone position. (B). Rod of Asclepius symbol consisting of a serpent coiled around a rob.