American Journal of Surgery Case Reports

Case Report

Inter-Clavicular Stabilization with A Titanium Sternal Fixation System After Radical Manubriectomy

Danny TA Nguyen[6], Kathryn Rodriguez[6], Christian Sobky[7], Lori M. Brown[4], Joseph R Garrett[1], Christy Y Chai[4], Carla C Moodie[1], Rajendra S Bhati[4], Gerard C Mosiello[2,3,4], Jonathan S Zager[2,4,5] and Eric M Toloza[1,4,5]*

[1]Department of Thoracic Oncology, Moffitt Cancer Center, USA

[2]Cutaneous Oncology, Moffitt Cancer Center, USA

[3]Plastic Surgery Service, Moffitt Cancer Center, USA

[4]Department of Surgery, University of South Florida Health, USA

[5]Department of Oncologic Sciences, University of South Florida Health, USA

[6]Morsani College of Medicine, USA

[7]Meharry Medical College Nashville, USA

Abstract

Introduction: Radical manubriectomy for manubrial tumors often destabilizes one or both upper extremities, but current reconstructive techniques prevent lateral but not medial clavicular displacement.

Case Presentation: Patient #1 is a 44-year-old man with manubrial plasmacytoma. Patient #2 is a 41-year-old man with upper chest basal cell carcinoma involving the manubrium. Patient #3 is a 64-year-old woman who is 14 months status post radical manubriectomy for metastatic thyroid cancer and whose clavicles were initially stabilized with daisy-chained loops of sternal wires, which broke while closing a car door. The three patients had mean age 49.7 year +7.2 year, mean BSA 2.2 m2+0.18 m2, mean BMI 39.3 kg/m2+5.8 kg/m2, and mean smoking history 15.0 +7.6 pk-yr. After radical manubriectomy in the 1st two patients and removal of the broken sternal wires in the 3rd patient, each patient underwent interclavicular stabilization using angled titanium plates from the Depuy Synthes Titanium Sternal Fixation System. Pt#2 also had bilateral pectoralis muscle flaps. Mean operative (skin-to-skin) time was 153 min +23.3 min; mean intra operative estimated blood loss was 273 mL+153 mL. Patient #2 was returned to OR on Postoperative Day (POD) #3 for right chest hematoma, and Patient #3 was returned to OR on POD#4 for left clavicular titanium sternal plate refixation. Additional perioperative complications occurred in Patient #2 (hypoxia from pneumonia) and in Patient #3 (hemorrhoids from loose stools). Mean hospital length of stay was 5.7 days +1.3 days. Follow-up of the 3 patients at 3 years, 3 months, and 2 years, respectively, (mean 668 days +292 days) revealed no sternal plate dehiscence, despite Patient #1's routinely unloading and reloading his airboat onto its trailer and his learning to SCUBA.

Discussion: Interclavicular stabilization with angled titanium sternal plates prevents lateral or medial displacement of the shoulders for optimum position of the upper extremities to maximize range of motion and function. The Synthes sternal titanium plate also has a midline release pin in case of need for emergent sternal entry.

Conclusion: Interclavicular titanium sternal plates effectively prevent both lateral and medial clavicular displacement after radical manubriectomy.

Keywords: Interclavicular; Sternal fixation; Manubriectomy; Titanium plates

Introduction

Sternal tumors, both primary and metastatic, in the manubrium are often treated surgically by radical manubriectomy when radiation therapy and chemotherapy are not viable options. Besides resection of the manubrium, this procedure often requires resection of one or both of the clavicular heads, rather than just bilateral sternoclavicular disarticulation, as well as resection of the 1st and 2nd costal cartilages bilaterally. Resection of the clavicular heads involves division of the sternocleidomastoid muscles, the interclavicular ligaments, and the costoclavicular ligaments. Thus, radical manubriectomy usually leaves the one or both of the clavicles and, therefore, one or both of the upper limbs destabilized. The remaining lateral portion of the clavicles are then displaced downward by the weight of the upper limbs and may result in compression of the brachial plexus, subclavian artery, and subclavian vein causing pain along the side of the neck or along the anterior chest. The destabilized clavicles may also be displaced laterally when the scapulae are retracted or when outward forces are applied on the upper limbs. Alternatively, the destabilized clavicles may be displaced medially when the scapulae are protracted or when inward forces are applied to the upper limbs.

However, destabilization of one or both upper extremities remains a concern, and there is no gold standard for reconstructive

Citation: Nguyen DTA, Rodriguez K, Sobky C, Brown LM, Garrett JR, Chai CY, et al. Inter-Clavicular Stabilization with A Titanium Sternal Fixation System After Radical Manubriectomy. Am J Surg Case Rep. 2021;2(2):1014.

Publisher Name: Medtext Publications LLC

Manuscript compiled: Jun 19th, 2021

***Corresponding author:** Eric M Toloza, Department of Thoracic Oncology, Surgery and oncologic Sciences, Moffitt Cancer Center, University of South Florida Health, 12902 USF Magnolia Drive, Suite CSB-6 (ThorProg), Tampa, FL 33612, USA, Tel: +1-813-745-7282; Fax: +1-813-449-8446; E-mail: eric.toloza@moffitt.org

techniques after radical manubriectomy [1]. Attempts to limit the lateral displacement of the clavicles after radical manubriectomy have been somewhat successful by "reconstructing" the manubrium with a nonabsorbable synthetic mesh, such as polypropylene mesh, polypropylene-polyethylene mesh, or Polytetrafluorethylene (PTFE), with mesh-methyl-methacrylate "Sandwiches" (MMS), or by reattaching the clavicles to each other with sternal wire loops chain-linked to each other.

Current manubrial reconstructive techniques prevent lateral clavicular displacement. However, except for MMS, none of these techniques prevents medial displacement of the clavicles after radical manubriectomy. In addition, polypropylene-polyethylene mesh can fragment, and the sternal wire loops may fracture, both of which would result in loss of interclavicular stability. The MMS also have the disadvantages of being difficult to handle and mold into the correct shape, being excessively rigid, with subsequent limitation of chest wall movements and danger of erosion of adjacent structures, being more prone to infection, being less radiolucent during future radiographic imaging studies, and being difficult to divide or remove during reoperation. Thus, resumption of normal range of function of the shoulders still remains a concern for thoracic surgeons after manubrial resection.

We present three cases of radical manubriectomy in which the clavicles are stabilized to each other using a titanium plate from the Titanium Sternal Fixation System (Depuy-Synthes, West Chester, PA). This interclavicular stabilization technique allows maintenance of the upper limbs laterally away from the body to maximize their range of motion and functional efficiency, minimizes lateral as well as medial displacement of the clavicles, and helps support the weight of the upper limbs to maintain their properly alignment.

Case Presentation

Patient #1 is a 44-year-old man with manubrial plasmacytoma. Patient #2 is a 41-year-old man with upper chest basal cell carcinoma involving the manubrium. Patient #3 is a 64-year-old woman who is 14 months status post radical manubriectomy for metastatic thyroid cancer and whose clavicles were initially stabilized with daisy-chained loops of sternal wires, which broke while closing a car door. The three patients had mean age 49.7 year +7.2 year, mean BSA 2.2 m^2 +0.18 m^2, mean BMI 39.3 kg/m^2 +5.8 kg/m^2, and mean smoking history 15.0+7.6 pack-yr.

After radical manubriectomy in the 1st two patients and removal of the broken sternal wires in the 3rd patient, each patient underwent interclavicular stabilization using angled titanium plates from the Titanium Sternal Fixation System. Patient #2 also had bilateral pectoralis muscle flaps. Mean operative (skin-to-skin) time was 153 min +23 min; mean intraoperative estimated blood loss was 273 mL+153 mL. Patient #2 was returned to OR on postoperative day (POD)#3 for right chest hematoma, and Patient #3 was returned to OR on POD#4 for left clavicular titanium sternal plate refixation. Additional perioperative complications occurred in Patient #2 (hypoxia from pneumonia) and in Patient #3 (hemorrhoids from loose stools). Mean hospital length of stay was 5.7 days +1.3 days. Follow-up of the 3 patients at 3 years, 3 months, and 2 years, respectively, (mean 668 days +292 days) revealed no sternal plate dehiscence, despite Patient #1's routinely unloading and reloading his airboat onto its trailer and his learning to SCUBA dive (Figure 1-3).

Figure 1: Pre-operative photo of Patient #2 showing the upper chest ulceration due to the patient's manubrial tumor.

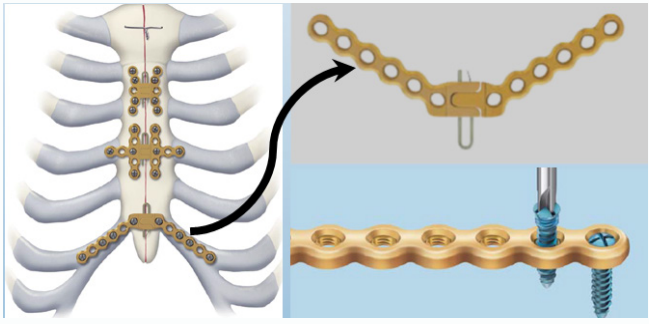

Figure 2: Use of a titanium sternal plate for interclavicular fixation. The angled titanium sternal plate, typically used to re-approximate the lower sternum and bilateral costal margins (lowest plate shown in left panel), is inverted (upper right panel) and affixed to the medial ends of the bilateral clavicles using titanium screws (lower right panel). Adapted from figures within the Depuy Synthes Titanium Sternal Fixations System Brochure.

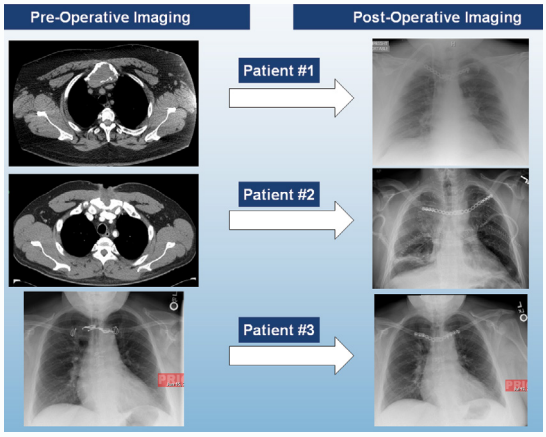

Figure 3: Comparison of pre-operative imaging (left panels) and post-operative imaging (right panels) for each of the 3 patients. The left panels for Patients #1 and #2 are axial images from their pre-operative computerized tomography scans showing the manubrial tumors, while the left panel for Patient #3 is a pre-operative posterior-anterior chest radiograph showing the daisy-chained loops of sternal wire, with the broken loop attached to the patient's left clavicle. Right panels for all 3 patients are post-operative chest radiographs showing the interclavicular titanium plates.

Discussion

The clavicles are stabilized to each other *via* their respective sternoclavicular joints with the manubrium as well as *via* the interclavicular ligament. With the lateral end of the clavicle forming part of the acromioclavicular joint, the sternoclavicular joint at the medial end of the clavicle serves as the only bony link between the upper limb and the axial skeleton. The medial 1/3 of the clavicle is also attached to the 1st costal cartilage via the costoclavicular ligament. The clavicle acts as a strut to maintain the upper limb laterally away from the body. By being laterally away from the body, the range of motion and the functional efficiency of the upper limb increases greatly. This mobility of the upper limb at the shoulder is necessary for placement of the hand to maximize manipulation. The clavicle also provides static stability to and bears part of the weight of the upper limb (the remaining is borne by the scapula), thereby reducing the need to use muscle energy to keep the upper limb in its proper alignment. The clavicle also transmits forces from the upper limb to the trunk.

Malignant thoracic wall tumors of the manubrium that have infiltrated crucial anatomic structures with varying pathologies, both primary and metastatic, are often surgically resected when radiation and chemotherapy is ineffective [1]. However, reconstruction of the thoracic wall after manubriectomy remains a challenge for surgeons and there is no consensus regarding the best method in the literature. Ideal reconstruction after total manubrial resection must restore normal respiratory movements, prevent paradoxical respirations, optimize thoracic cage rigidity, and return normal function to the shoulders by stabilizing the clavicles. Eskola et al. [2] documented 12 cases of sternoclavicular resections in patients who either had simple resection *vs.* those who had resection followed by a tendon or fascia graft to the medial clavicular head. In cases of patients who underwent simple resection, there was notable painful restriction of shoulder movement and abduction.

The use of prosthetics in chest reconstruction is a popular avenue for surgeons after complete manubrial resection. Past case reports have described using different reconstruction techniques, such as titanium bars and clips, PTFE or polypropylene/polyethylene mesh, the latter often used to sandwich methyl-methacrylate cement in between two layers of mesh [3-5]. Recent reports have also described the use of autogenous rib grafts in order to reduce the risk of infection, immune response, and greater osteointegration during healing. The rib graft harvest was connected to the clavicles bilaterally and to the sternum using rib nails and stainless steel wires [6,7]. Crucial to all of these techniques lie in recreating a stable sternoclavicular joint, with the prosthesis mimicking the semi-rigid construct of the costoclavicular and infraclavicular ligaments. However, each method of reconstruction comes with its advantages and drawbacks.

Use of a MMS is a popular method for sternal reconstruction after radical resection for various malignant sternal tumors, such as chondrosarcoma and osteosarcoma. Following implanting the MMS, the clavicles are sutured to the mesh using non-absorbable sutures in order to recreate the sternoclavicular joint [3,4,8]. The drawback to a MMS is that it is difficult for the MMS to be incorporated by the patient's chest wall soft tissue due to the rigid and solid nature of the methyl-methacrylate, but there is a possibility of medial displacement of the clavicles as well as of paradoxical chest wall movement with respiration if polypropylene/polyethylene mesh is used without methyl-methacrylate. Additionally, the MMS technique is at risk of wound complications, infection, and, in particular, dislocation and fracture of the MMS if it is not properly fixed [4].

On the other hand, there are reports of using the STRATOS system (Strasbourg Thoracic Osteosyntheses System, Strasbourg, Germany) consisting of titanium bars and rib clips to recreate the sternoclavicular junction after complete sternal resection in various ways. There are only 2 case reports in the literature using STRATOS after radical manubrial resection. The first did not address the clavicle stability or the sternoclavicular joint, opting to focus instead on the 2nd through 5th ribs and covering the implant with the pectoris major muscle flap [9]. The other report used STRATOS system after radical resection for malignant thyroid tumor by connecting the clavicles at 45° angles to the 2nd ribs bilaterally in an "X-shaped" configuration over a mesh [5].

In this case report, we described a new method of sternal reconstruction after radical manubriectomy using the Titanium Sternal Fixation System to stabilize the clavicles on 3 patients who all recovered successfully post-operation. The original purpose of the Synthes Sternal Fixation System uses titanium plates, titanium unilock screws, and an emergency release pin to close a sternotomy. There are no previous reports using the Synthes system in an interclavicular fashion for stabilization during reconstruction after complete manubrial resection. With this technique, both lateral and medial displacement of the clavicles is avoided.

Conclusion

We describe a new method of sternoclavicular reconstruction using the Titanium Sternal Fixation System to stabilize both clavicles after radical manubriectomy. Advantages over the previously used techniques are that these titanium plates stabilize not only lateral deviations but also medial deviations of the clavicles as well as provide solid support of bilateral shoulders in the anatomical position for these patients, allowing for full range of motion. We believe this technique is safe and optimizes patient outcomes by addressing the past issues of medial as well as lateral displacement of the bilateral shoulders and resultant periclavicular pain and shoulder weakness after radical manubriectomy.

Acknowledgment

This study was previously presented as a poster at the Chest World Congress in Madrid, Spain, in March 21-24, 2014.

Funding

This study was supported in part by a 2011 Summer Intern Scholarship to C.S. from the American Association of Thoracic Surgeons and by a 2013 Summer Scholarly Award to K.L.R. and a 2016 Summer Scholarly Award to D.T.N. from the Scholarly Concentrations Program at the University of South Florida (USF) Health Morsani College of Medicine.

D.T.-A.N. (now an MD) is currently a general surgery resident at the Los Angeles County-University of Southern California Medical Center in Los Angeles, CA, USA. K.R. (now K. Lupez, MD) is currently Associate Professor of Emergency Medicine and Associate Director of Emergency Ultrasound at Tufts Medical Center in Boston, MA, USA. C.S. (now an MD) is currently a physician in the Department of Emergency Medicine at Advent Health Tampa in Tampa, FL, USA. L.M.B. is currently an emergency physician with the Washington Parish Emergency Physician Group in Bogalusa, LA, USA. C.Y.C. is currently Chief, Section of General Surgery & Surgical Oncology at

the Michael E. Debakey Veterans Affairs Medical Center and Baylor College of Medicine in Houston, TX, USA. R.S.B. is currently a surgical oncologist at the Marietta Memorial Hospital in Marietta, OH, USA.

Conflict-of-Interest (COI) Disclosures

E.M.T. has had a financial relationship with DePuy-Synthes, a medical device company with Johnson & Johnson, in the form of consultation honoraria. No other authors have any COI to disclose.

Informed Consent

Permission was obtained from the patient for publication of this case report and any accompanying images for education purposes as part of our institutional surgical informed consent. A copy of the written consent is available for review by the Editor-in-Chief of this journal.

References

1. Harati K, Kolbenschlag J, Behr B, Goertz O, Hirsch T, Kapalschinski N, et al. Thoracic wall reconstruction after tumor resection. Front Oncol. 2015;5:247.
2. Eskola A, Vainionpaa S, Vastamaki M, Slatis P, Rokkanen P. Operation for old sternoclavicular dislocation. Results in 12 cases. J Bone Joint Surg Br. 1989;71(1):63-5.
3. Kużdżał J, Warmus J, Grochowski Z, Gądek A. Reconstruction of the sternal manubrium. J Thorac Cardiovasc Surg. 2014;147(6):1986-8.
4. Chaudhry LU, Alhajji Z, Aldulaijan F, Mutairi H, Amr SS. Manubrioclavicular and Manubriosternal Reconstruction After Radical Resection for Chondrosarcoma of Manubriosternum: A Modified Surgical Technique. Ann Thorac Surg. 2015;99(6):e137-9.
5. Hajjar WM, Alnassar S, Abu-Daff SN, Al-Dhahri SF. A novel technique for the reconstruction of resected sternoclavicular joints: A case report with a review of the literature. Ann Thorac Med. 2013;8(1):60-3.
6. Zhang G, Liang C, Shen G, Li W, Huang L, Pan S, et al. Autogenous rib grafts for reconstruction of the manubrium after resection: Technical refinements and outcomes. J Thorac Cardiovasc Surg. 2014;148(6):2667-72.
7. Ye C, Zhang G, Chai Y. A rare desmoid tumor arising from the manubrium. J Cardiothorac Surg. 2015;10:33.
8. Collaud S, Pfofe D, Decurtins M, Gelpke H. Mesh-bone cement sandwich for sternal and sternoclavicular joint reconstruction. Eur J Cardiothorac Surg. 2013;43(3):643-5.
9. Gonfiotti A, Santini PF, Campanacci D, Innocenti M, Ferrarello S, Janni A. Use of moldable titanium bars and rib clips for total sternal replacement: A new composite technique. J Thorac Cardiovasc Surg. 2009;138(5):1248-50.