American Journal of Surgery Case Reports

Case Report

Intrapleural Migration of a Breast Prosthesis after Redo Thoracotomy for Recurrent Lung Cancer

Gregory Fishberger[4], Jobelle JAR Baldonado[1,2,3], Joseph R. Garrett[1], Carla C Moodie[1] and Eric M.Toloza[1,2,3]*

[1]Department of Thoracic Oncology, Moffitt Cancer Center, Tampa, FL, USA

[2]Department of Surgery, University of South Florida Health Morsani College of Medicine, Tampa, FL, USA

[3]Department of Oncologic Sciences, University of South Florida Health Morsani College of Medicine, Tampa, FL, USA

[4]Morsani College of Medicine, University of South Florida Health, Tampa, FL, USA

Abstract

Introduction: Breast prostheses have the potential to migrate into the intrapleural cavity and occasionally rupture during thoracic surgery, particularly when the fibrous capsule around the prosthesis is disrupted. Here, we present a case of breast prosthesis intrapleural migration after re-do thoracotomy for lung cancer.

Case: A 60-year-old woman presented with history of left thoracotomy and left upper lobectomy for stage-1 adenocarcinoma 9 years previously and who underwent re-do left thoracotomy, pleurolysis, and Left Lower Lobar (LLL) superior segmentectomy for metachronous stage-1 adenocarcinoma 7 months prior to presentation, both at an outside facility. Her second thoracotomy was complicated by hypoxia refractory to steroids and antibiotics for a right upper lobar infiltrate noted on chest X-ray on postoperative day (POD)#3. Computerized Tomography (CT)-angiogram on POD#5 revealed no pulmonary embolus and showed her bilateral breast prostheses to be intact, but the left pleural chest tube was noted to pass through the left breast prosthesis capsule, with an adjacent Intercostal Space (ICS) defect. Her left chest tube was removed on POD#7, and she was discharged to home on POD#11. Four months after the 2nd thoracotomy, she reported falling in the shower, which resulted in 10% compression fracture of the T12 vertebra. She was instructed to wear a Thoracic-Lumbar-Sacral Orthosis (TLSO) brace with bed rest until she underwent T11 and T12 kyphoplasty. Subsequent lung cancer surveillance CT scan revealed that the left breast prosthesis had ruptured and migrated into the left hemithorax. She underwent left Video-Assisted Thoracoscopic (VATS) surgery using a port incision along the left 8th ICS at the posterior axillary line and another along the left 6th ICS at the anterior axillary line. The intrapleurally displaced left breast prosthesis was retrieved from within a fibrous capsule between the LLL basilar segments and the left diaphragm. Skin-to-skin operative time was 51 min, and intraoperative estimated blood loss was <10 mL. There were no intraoperative or postoperative complications. Her left pleural chest tube was removed on POD#1, and she was discharged to home on POD#2.

Discussion: Subpectorally implanted breast prostheses are at risk of being injured and of migrating into the pleural cavity through ICS defects created during thoracotomy, especially with a disrupted prosthetic capsule and with a ruptured prosthesis. Migration through an ICS defect may be promoted by extrinsic compression, such as that experienced with a TLSO brace.

Conclusion: Thoracotomies in patients with breast prostheses require care to avoid injury to the prosthesis or its fibrous capsule in order to avoid migration of the breast prosthesis into the pleural cavity.

Keywords: Intrapleural; Migration; Breast prosthesis; Thoracotomy; Thoracoscopy; Lung cancer

Introduction

Breast prosthesis have the potential to migrate into the intrapleural cavity and occasionally rupture during thoracic surgery, particularly when the fibrous capsule that forms around the prosthesis is disrupted [1]. Capsule disruption may occur during thoracotomy, thoracoscopy, or even chest tube placement. We present a case of a breast prosthesis migrating into the pleural cavity following redo thoracotomy for lung cancer.

Citation: Fishberger G, Baldonado JJAR, Garrett JR, Moodie CC, Toloza EM. Intrapleural Migration of a Breast Prosthesis after Redo Thoracotomy for Recurrent Lung Cancer. Am J Surg Case Rep. 2021;2(3):1016.

Publisher Name: Medtext Publications LLC

Manuscript compiled: Jul 28th, 2021

***Corresponding author:** Eric M Toloza, Department of Thoracic Oncology, Moffitt Cancer Center, 12902 USF Magnolia Drive, Suite CSB-6 (ThorProg), Tampa, FL 33612, USA, Tel: +1-813-745-7282; E-mail: eric.toloza@moffitt.org

Case Presentation

The patient is a 60-year-old woman with history of left thoracotomy and left upper lobectomy for a 1.5 cm stage-1 (T1aN0M0) adenocarcinoma 9 years previously. One year prior to this presentation, a Computerized Tomography (CT) scan revealed a 7 mm Left Lower Lobar (LLL) lung nodule that was noted to have grown to 1.2 cm in size and to be hypermetabolic, with maximum standardized uptake value (maxSUV) of 2.75, on positron-emission tomography (PET)-CT scan two months later. Subsequent needle biopsy by CT-guidance revealed non-small cell carcinoma. An enlarging left pleural effusion prompted thoracentesis of 250 mL of serous pleural fluid that was negative for malignancy on cytopathology. One month later (7 months prior to this presentation), she underwent re-do left thoracotomy, pleurolysis, and Left Lower Lobar (LLL) superior segmentectomy for clinical stage-1 biopsy-proven Non-Small Cell Lung Cancer (NSCLC). Both of these thoracotomies were performed at an outside facility (Figure 1).

Her second thoracotomy was complicated by episodes of

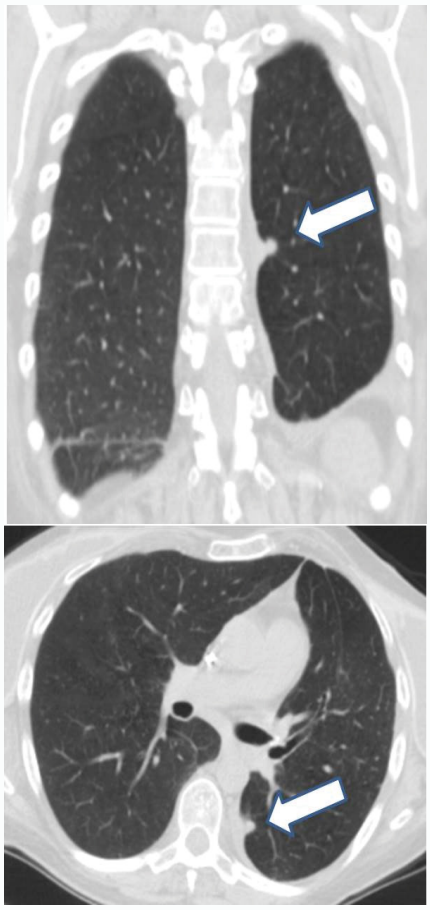

Figure 1: Coronal (top panel) and axial (bottom panel) images from Computerized Tomography (CT) scan taken 4 months prior to the re-do left thoracotomy and showing a 1 cm paravertebral left lung nodule (arrows) that is suggestive of recurrent left lung cancer.

desaturation and hypoxia, which required Intensive Care Unit (ICU) admission, but which were refractory to steroids and antibiotics for suspected aspiration pneumonia based on Right Upper Lobar (RUL) infiltrate noted on chest x-ray on postoperative day (POD)#3. Modified barium swallow study was performed, and her diet was modified; however, she continued to have difficulty.

Computerized Tomography (CT)-angiogram on POD#5 revealed no evidence of pulmonary embolus, but did reveal pulmonary edema, which responded to furosemide diuresis. Although the patient reports noting that her left breast prosthesis felt absent on the evening immediately after her second thoracotomy, the CT-angiogram revealed bilateral breast prostheses to be intact. The CT-angiogram did describe the left pleural chest tube as passing through the left breast prosthesis capsule, without puncturing the left breast prosthesis, and also noted a defect in the Intercostal Space (ICS) extending anteriorly from the left pleural chest tube and that allowed direct continuity between the left pleural cavity and the left breast prosthesis capsule.

Her left pleural chest tube was able to be removed on POD#7, after which she was able to be weaned from oxygen supplementation via nasal cannula to room air and eventually transferred out of the ICU to a regular hospital ward. Her furosemide was converted from intravenous to oral dosing, and she was discharged to home on POD#11 with home-health nursing care.

Final pathology revealed a 1.5 cm moderately-differentiated adenocarcinoma, with visceral pleural invasion, but with uninvolved resection margins and uninvolved level 10 L (hilar) and 11 L (interlobar) Lymph Nodes (LNs) (pT2N0M0). One month after the second thoracotomy, a recurrent left pleural effusion prompted a repeat left thoracentesis of 250 mL of serous pleural fluid that was again negative for malignancy on cytology.

Four months after the 2nd thoracotomy (3 months prior to this presentation), she reported slipping and falling onto her buttock while leaving the shower, which resulted in a 10% compression fracture of the T12 vertebra noted on Magnetic Resonance Imaging (MRI). She was then instructed to wear a Thoracic-Lumbar-Sacral Orthosis (TLSO) brace with bed rest for the next 3 months. During the following 3 weeks, she complained that the TLSO brace pressed against her central venous catheter port on her left anterior chest and that she experienced disuse weakness of her muscles, which prompted her subsequently undergoing T11 and T12 kyphoplasty, which incidentally resulted in pulmonary cement embolization.

Lung cancer surveillance with CT scan 2 months after the kyphoplasty (one month prior to this presentation) noted intact subpectoral right breast prosthesis, but revealed that the left breast prosthesis had ruptured and was now displaced into the inferior left hemithorax just superior to the left hemidiaphragm, which was confirmed by MRI of the thorax.

She was referred by her local medical oncologist to our thoracic surgery clinic for evaluation. She underwent fiberoptic bronchoscopy and left Video-Assisted Thoracoscopic (VATS) surgery through a 3 cm port incision along the left 8th ICS at the posterior axillary line and another 3 cm port incision along the left 6th ICS at the anterior axillary line. She then underwent left VATS lysis of pleural adhesions between the LLL basilar segments and the left hemidiaphragm and between the LLL basilar segments and the pericardium.

The intrapleurally-displaced left breast prosthesis was identified encapsulated beneath the left 8th ICS port incision between the LLL basilar segments and the left hemidiaphragm and was grasped and retrieved with a ring clamp, after the fibrous capsule was incised with cautery. Left VATS pulmonary decortication was then performed to dissect the fibrous capsule free from the LLL visceral pleura and from the left hemidiaphragm, with no evidence of diaphragmatic hernia and with subsequent insertion of 32-French angled left pleural chest tube along the lateral costophrenic recess.

Total skin-to-skin operative time was 51 min, and the total intraoperative Estimated Blood Loss (EBL) was <10 mL. There were no intraoperative complications and no postoperative complications. Her left pleural chest tube was able to be removed on POD#1, and she was discharged to home on POD#2. Final pathology revealed that the intrapleural fibrous capsule and associated pleural debris were negative for malignancy. After her postoperative clinic evaluation 2 weeks postoperatively, she was referred to a plastic surgeon for potential placement of a new left breast prosthesis 4 weeks later and also referred back to her local medical oncologist for lung cancer surveillance with a CT scan in 6 months.

Approximately 14 months postoperatively, surveillance PET-CT scan revealed a non-hypermetabolic 1.6 cm LLL lung nodule, with left basilar pleural thickening as well as increased metabolic activity along the left paraspinal musculature and along the left 3rd rib. A CT-guided needle biopsy 5 months later indicated no evidence of malignancy.

Over the past year, she developed worsening back pain. Over the past 4 months, she also developed a psoriatic flare throughout her extremities, which was treated with prednisone and methotrexate. Serial chest CT scans and subsequent thoracic and lumbar MRI revealed abnormal enhancement in the paraspinous soft tissue extending from T7 through T12 and abutting the lateral surfaces of multiple vertebral bodies, but without abnormal signal within the vertebrae. The MRI also demonstrated a chronic 25% loss of height of the anterior T12 vertebra that appeared unchanged compared to imaging studies over the preceding 2-1/2 years.

Neurosurgical consultation was obtained and CT-guided needle biopsy of the left paraspinous muscle abnormality and the LLL lung nodule each revealed adenocarcinoma. She was subsequently treated with 70-Gray External-beam Radiation Therapy (XRT) in 35 fractions to the LLL lung cancer and the left paraspinal metastatic Adenocarcinoma (Figure 2 and 3).

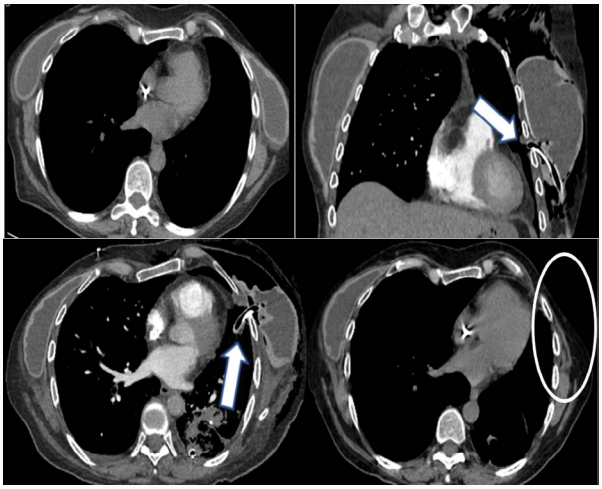

Figure 2: Axial image from Computerized Tomography (CT) scan taken 4 months prior to re-do thoracotomy for recurrent left lung cancer and showing presence of bilateral breast prostheses (upper left panel); coronal (upper right panel) and axial (bottom left panel) images from another CT scan taken 5 days after the re-do thoracotomy showing continued presence of bilateral breast prostheses and the left pleural chest tube passing through left breast prosthesis fibrous capsule and into the left pleural cavity through an underlying chest wall defect along the left 4th intercostal space (arrows); and axial image from new CT scan taken 6 months after the re-do thoracotomy now showing the absence of the left breast prosthesis (white oval).

Discussion

The primary techniques of breast prosthesis implantation include subglandular and subpectoral, and both methods may be utilized for cosmetic breast augmentation [2]. Subglandular placement involves implantation within the retromammary space between breast tissue and the pectoralis major muscle [3]. Subpectoral implantation involves placing the breast prosthesis below the pectoralis major muscle following the dissection and release of the inferior muscular attachments [2,4]. The upper pole is located in the submuscular plane, while the lower pole is located in the subglandular plane [5].

Following implantation of the prosthesis, a collagen scar tissue capsule forms around the implant, thus isolating the implant [6]. The integrity of this fibrous capsule ultimately proves beneficial in instances in which the chest wall is traversed for intrathoracic

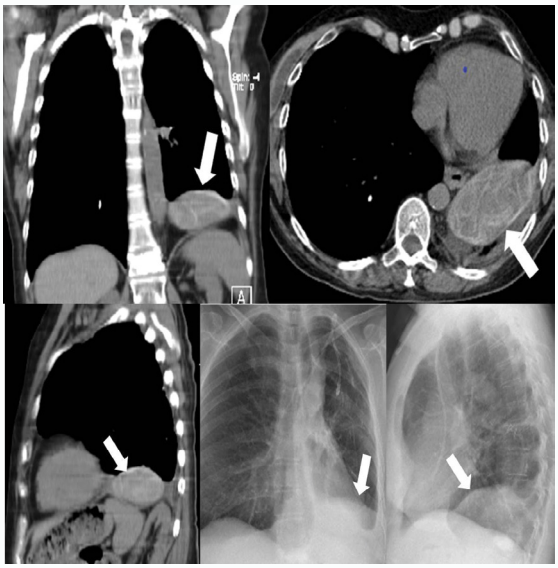

Figure 3: Coronal (upper left panel), axial (upper right panel), and sagittal (lower left panel) from Computerized Tomography (CT) scan taken 6 months after re-do thoracotomy for recurrent lung cancer and showing the left breast prosthesis (arrows) now located within the lower left hemithorax just above the left hemidiaphragm; and chest radiograph Posterior-Anterior (PA; lower middle panel) and lateral (lower right panel) views taken 5 days prior to Video-Assisted Thoracoscopic (VATS) retrieval of the intrapleurally-migrated left breast prosthesis (arrows).

surgical intervention [7]. Excess thickening of the capsule and capsular contracture can lead to compression of the breast implant, producing a visible deformation of the breast or prosthesis rupture [8]. Subpectoral placement results in reduced risk of capsule contracture, even though this method produces more discomfort after surgery [9,10]. Treatment following rupture of saline breast implants is fairly uncomplicated, in that the saline is absorbed by the body, and the implant is then explanted [11]. Rupture of silicone prosthetics requires removal of the silicone at the rupture site and explantation of the remaining prosthetic [12]. If silicone thorax occurs, the silicone must be removed from the pleural cavity [13].

Intrathoracic migration of breast prosthesis is an exceedingly rare event. Instances of such migration typically occur after access to the thoracic cavity has been required and a chest wall defect has been created [1]. Other risk factors involve intraoperative laceration of the pleura or accidental needle puncture [14]. Migration risk is likely impacted by the prothesis placement. Subglandular placement carries the benefit of protection posteriorly by the pectoralis major muscle [2]. Subpectoral placement leaves the implant in contact with the chest wall and intercostal muscles that are then traversed by chest tubes or during minimally invasive VATS and thoracotomy interventions [15]. Subpectorally-implanted breast prostheses are, thus, at risk of being injured and of migrating into the pleural cavity through defects in the intercostal muscles created during thoracotomy, especially if the prosthetic fibrous capsule has been disrupted and if the prosthesis has ruptured [16]. Therefore, the fibrous capsule plays an essential role in maintaining the position of the implant, particularly after the aforementioned intrathoracic interventions when subpectoral prosthesis placement has been utilized. Migration through an ICS defect may be further promoted by extrathoracic pressure, such as that experienced with a TLSO brace [17].

Previous case reports have described intrathoracic migration of a breast prosthesis following relatively similar clinical courses to that in our case: 1) A breast prosthesis is placed for cosmetic purposes or for reconstruction post-mastectomy; 2) The prosthetic fibrous capsule is disrupted during chest tube placement [13], VATS surgery [18-20], minimally invasive cardiac surgery [7,21], or thoracotomy [1]; 3) A communication remains between the implant capsule and pleural space that facilitates the migration of the prosthesis through a defect in the chest wall into the pleural space.

Mehta et al. [1] described the first reported case of intrathoracic migration of breast prosthesis post-thoracotomy (Table 1). In that case, a 52-year-old woman, with history of breast augmentation 14 years previously, underwent right thoracotomy for lobectomy and mediastinal LN dissection for NSCLC, during which the posterior aspect of the prosthetic capsule had been partially opened. On POD#12, she complained of progressive dyspnea and breast volume asymmetry. Chest CT scan revealed intrathoracic migration of the right silicone breast prosthesis through a defect in the right thoracic wall, and re-do thoracotomy was performed to extract the intact prosthesis from above the right hemidiaphragm.

Intrathoracic migration of breast prosthesis has been reported to occur in cases of multiple revision surgeries for breast augmentation. Kim et al. [14] reported the case of a 34-year-old woman with history of two revisions over three years (Table 1). Dissection of dense adhesions between the prosthesis and the chest wall during the second revision surgery resulted in a chest wall defect along the 4th ICS, which allowed migration of the prosthesis through the defect into the pleural cavity when the patient massaged her breasts after the second revision.

Sykes et al. [18] described the first reported case of intrathoracic breast prosthesis migration following VATS surgery (Table 1). The authors report the case of a 72-year-old woman, with history of bilateral mastectomy for ductal carcinoma, followed by silicone breast prosthesis 23 years previously. Five months prior to presentation, the patient underwent VATS right middle lobectomy with mediastinal LN dissection, during which a defect was created in the anterior chest wall between the right 3rd and 4th ribs. At presentation, the patient complained of being unable to feel her right breast implant. During implant retrieval, the posterior aspect of the implant capsule was found to have been disrupted, and a pool of free silicone was found within the pleural space, indicating implant rupture.

Intrathoracic migration of a breast prosthesis has also been described after minimally invasive cardiac surgery for mitral valve repair [7,21]. During the procedure, the fibrous capsule was disrupted, and the breast implant was explanted during surgery [7]. At the end of the operation, the implant was placed back into the implant pocket. However, the disruption of the prosthesis capsule provided the opportunity for subsequent intrathoracic migration.

Herein we report a case of a 60-year-old woman with a cosmetic implant and history of left thoracotomy and left upper lobectomy 9 years previously. Seven months prior to the patient's presentation, she underwent repeat left thoracotomy and LLL superior segmentectomy. On POD#5 of the second thoracotomy, a CT angiogram revealed the left pleural chest tube was passing through the left breast prosthesis capsule, although the prosthesis appeared intact and not punctured, thus creating a communication between the prosthesis capsule and the left pleural cavity. Four months after the second thoracotomy, the patient slipped in the shower and required a TLSO brace for three months. Two months after subsequent kyphoplasty, a lung cancer surveillance CT scan revealed that the left breast prosthesis was ruptured and was now located within the inferior left hemithorax just above the left hemidiaphragm. The breast prosthesis was found encapsulated between the LLL visceral pleural and the left hemidiaphragm. The left breast prosthesis and fibrous capsule were

Table 1: Case Reports of Intrathoracic Migration of a Breast Prosthesis.

Case Report	Patient Age	Reason for Initial Breast Prosthesis	Implant Type	Implant Laterality	Implant Position	Most Recent Surgery Completed Prior to Implant Migration	Most Recent Surgical Approach Prior to Implant Migration	Time from Initial Implant Placement to Migration	Time from Most Recent Surgery to Migration
Chen et al. [16]	29	Cosmetic	Silicone	Left	Unknown	Breast augmentation	N/A	2 months	2 months
Mehta et al. [1]	52	Cosmetic	Silicone	Right	Subpectoral	Lobectomy; mediastinal LN dissection	Thoracotomy	14 years	12 days
Kim et al. [14]	34	Cosmetic	N/A	Right	Subpectoral	Breast augmentation revision	N/A	3 years	1 month
Sykes and Rosella [18]	72	Reconstructive	Silicone	Right	Subpectoral	Lobectomy; mediastinal LN dissection	VATS	23 years	7 months
Lehoux et al. [19]	71	Reconstructive	Silicone	Right	Subpectoral	Lobectomy	VATS	22 years	6 months
Roussel et al. [20]	72	Reconstructive	Silicone	Right	Subpectoral	Lobectomy; mediastinal LN dissection	VATS	24 years	5 months
Fong and Hoffman [21]	59	Reconstructive	N/A	Right	Subpectoral	Mitral valve repair	MIS	N/A	N/A
Songcharoen et al. [7]	61	Reconstructive	Saline	Right	Subpectoral	Mitral valvuloplasty	MIS	5 years	5 months
Our Case	60	Cosmetic	N/A	Left	Subpectoral	Re-do lobectomy	Thoracotomy	N/A	6 months

N/A: Not Available; VATS: Video-Assisted Thoracoscopy; LN: Lymph Node; MIS: Minimally Invasive Surgery

removed by VATS without complications.

Several factors likely contributed to intrathoracic migration of the left breast prosthesis. The patient had undergone two left thoracotomies, each requiring the division of the intercostal musculature and which disrupted the muscular integrity of the chest wall. Further, the left chest tube placed during the second thoracotomy had passed through the left breast prosthesis capsule. While the prosthesis had not yet migrated, the risk of intrathoracic migration was greatly increased due to the formation of the chest wall defect. Prior case reports note that the strong negative pressure differential between the pleural cavity and the prosthesis capsule during inspiration draws the breast prosthesis through the chest wall defect into the pleural cavity [14,18,20]. In our case, the pressure differential was exacerbated by the TLSO brace. The TLSO brace compressed the patient's anterior chest and resulted in persistently elevated external pressure on the chest, which likely promoted gradual migration of the left breast prosthesis into the pleural cavity while the patient was wearing the brace.

Compared to minimally invasive VATS surgery, thoracotomy involves more substantial division of the intercostal musculature to access the intrapleural space [22]. In this context, there would be greater risk of a post-surgical chest wall defect facilitating communication between the implant capsule and the intrapleural cavity. Interestingly, a literature search of '"intrathoracic"& "thoracotomy" & "migration" & "breast"' on PubMed reveals the case by Mehta et al. [1] as the only report of a breast prosthesis undergoing intrathoracic migration after thoracotomy. The remaining case reports occurred in the context of breast revision surgery, VATS surgery, or minimally invasive cardiac surgery, which suggests that disruption of the prosthesis fibrous capsule more directly impacts the likelihood of prosthesis intrathoracic migration rather than the surgical approach.

While intrathoracic migration of breast prosthesis is an uncommon occurrence, measures can be taken to minimize the risk of this postoperative complication. The fibrous capsule that forms around the breast prosthesis isolates and keeps the implant in place [2]. By ensuring that the fibrous capsule is avoided and kept intact during thoracic procedures, the breast prosthesis will remain isolated from any defect in the chest wall created during chest tube placement, minimally invasive approaches, or thoracotomy. In order to avoid impacting the breast prosthesis capsule, image-guided chest tube placement could prove highly beneficial. For procedures involving thoracotomies or VATS, preoperative imaging of patients with existing breast protheses would aid in surgical planning to avoid the capsule if possible. Furthermore, the breast prosthesis should not be explanted unless necessary. If the prosthesis capsule must be disrupted, the capsule should be prophylactically sutured closed or reinforced, and the chest wall defect meticulously repaired.

Conclusion

Breast prostheses, especially those implanted subpectorally, are at risk of being injured and of migrating into the pleural cavity through defects in the intercostal muscles created during thoracic surgery, particularly if the prosthesis fibrous capsule has been disrupted and if the prosthesis has ruptured [16]. We report a case of breast prosthesis migration into the pleura cavity after re-do thoracotomy for recurrent lung cancer, in which both the intercostal muscles and the prosthesis capsule were disrupted. Migration through an ICS defect may be facilitated by extrathoracic pressure, such as what might be experienced with a TLSO brace [17]. Thus, thoracic procedures in patients with existing breast prostheses, especially subpectorally-implanted breast prostheses, require care to avoid injury to the prosthesis and to avoid disrupting the prosthetic fibrous capsule in order to minimize the risk of migration of the breast prosthesis into the pleural cavity.

Acknowledgements

Funding

This report was supported in part by a 2021 Summer Scholarly Award presented to G.F. from the Office of Research, Innovation, and Scholarly Endeavors (RISE) at the University of South Florida (USF) Health, Morsani College of Medicine in Tampa, FL, USA. None of the other authors had any funding source to report.

Informed consent

Permission was obtained from the patient for publication of this case report and any accompanying images for education purposes as part of our institutional surgical informed consent. A copy of the written consent is available for review by the Editor-in-Chief of this journal.

References

1. Mehta AM, Bard MP, van Straten A, van Beijeren I, Rijna H. Intrathoracic migration of a breast prosthesis after thoracotomy. J Thorac Cardiovasc Surg. 2008;135(1):206-7, 207.e1.
2. Coombs DM, Grover R, Prassinos A, Gurunluoglu R. Breast augmentation surgery: Clinical considerations. Cleve Clin J Med. 2019;86(2):111-22.
3. Adams WP, Mallucci P. Breast augmentation. Plast Reconstr Surg. 2012;130(4):597e-611e.
4. Spear SL, Jespersen MR. Breast implants: saline or silicone? Aesthet Surg J. 2010;30(4):557-70.
5. Tebbetts JB. A system for breast implant selection based on patient tissue characteristics and implant-soft tissue dynamics. Plast Reconstr Surg. 2002;109(4):1396-409;discussion 1410-5.
6. Bucky LP, Ehrlich HP, Sohoni S, May JW Jr. The capsule quality of saline-filled smooth silicone, textured silicone, and polyurethane implants in rabbits: a long-term study. Plast Reconstr Surg. 1994;93(6):1123-31; discussion 1132-3.
7. Songcharoen SJ, McClure M, Aru RG, Songcharoen S. Intrathoracic migration of a breast implant after minimally invasive cardiac surgery. Ann Plast Surg. 2015;74(3):274-6.
8. Hillard C, Fowler JD, Barta R, Cunningham B. Silicone breast implant rupture: a review. Gland Surg. 2017;6(2):163-8.
9. Henriksen TF, Fryzek JP, Holmich LR, McLaughlin JK, Kjoller K, Hoyer AP, et al. Surgical intervention and capsular contracture after breast augmentation: a prospective study of risk factors. Ann Plast Surg. 2005;54(4):343-51.
10. Stevens WG, Nahabedian MY, Calobrace MB, Harrington JL, Capizzi PJ, Cohen R, et al. Risk factor analysis for capsular contracture: a 5-year Sientra study analysis using round, smooth, and textured implants for breast augmentation. Plast Reconstr Surg. 2013;132(5):1115-23.
11. Swezey E, Shikhman R, Moufarrege R. Breast Implant Rupture. StatPearls. 2021.
12. Seiler SJ, Sharma PB, Hayes JC, Ganti R, Mootz AR, Eads ED, et al. Multimodality Imaging-based Evaluation of Single-Lumen Silicone Breast Implants for Rupture. Radiographics. 2017;37(2):366-82.
13. Rice DC, Agasthian T, Clay RP, Deschamps C. Silicone thorax: a complication of tube thoracostomy in the presence of mammary implants. Ann Thorac Surg. 1995;60(5):1417-9.
14. Kim H, Heo C, Baek R, Minn K, Kim S, Chun S. Breast implant migration into pleural

cavity. J Plast Reconstr Aesthet Surg. 2009;62(5):e89-90.

15. Lesavoy MA, Trussler AP, Dickinson BP. Difficulties with subpectoral augmentation mammaplasty and its correction: the role of subglandular site change in revision aesthetic breast surgery. Plast Reconstr Surg. 2010;125(1):363-71.

16. Chen ZY, Wang ZG, Kuang RX, Wang BT, Su YP. Implant found in thoracic cavity after breast augmentation. Plast Reconstr Surg. 2005;116(6):1826-7.

17. Pham VM, Houilliez A, Schill A, Carpentier A, Herbaux B, Thevenon A. Study of the pressures applied by a Cheneau brace for correction of adolescent idiopathic scoliosis. Prosthet Orthot Int. 2008;32(3):345-55.

18. Sykes JB, Rosella PA. Intrathoracic migration of a silicone breast implant 5 months after video-assisted thoracoscopic surgery. J Comput Assist Tomogr. 2012;36(3):306-7.

19. Lehoux JM, Tchantchaleishvili V, Jones CE. Intrathoracic migration of a silicone breast implant after video-assisted thoracoscopic surgery. Ann Thorac Surg. 2013;96(1):326.

20. Roussel LO, Koltz PF, Langstein HN. Intrathoracic Breast Implant Migration following Video-Assisted Thorascopic Surgery. Plast Reconstr Surg. 2015;135(6):1075e-6e.

21. Fong TC, Hoffmann B. Images in clinical medicine. Disappearance of a breast prosthesis during Pilates. N Engl J Med. 2011;365(24):2305.

22. Kirby TJ, Mack MJ, Landreneau RJ, Rice TW. Lobectomy--video-assisted thoracic surgery versus muscle-sparing thoracotomy. A randomized trial. J Thorac Cardiovasc Surg. 1995;109(5):997-1001; discussion 1001-2.