

Case Report

Isolated Adrenal Gland Hemorrhage: A Case of Car Accident

Hossein Abdolrahimzadeh Fard¹, Soheil Bolandi¹ and Zahra Mohammadi^{2*}

¹Trauma Research Center, Shahid Rajaei Hospital, Shiraz University of Medical Science, Iran

²Shiraz University of Medical Sciences, Iran

Abstract

Introduction: Due to the specific features of the adrenal glands, traumatic adrenal injury is an infrequent phenomenon. A major number of this rare type of trauma are induced by blunt force injuries and rarely caused by penetrating mechanisms. In such a condition, the whole body computed tomography scan plays a key role in early diagnosis.

Case presentation: This paper describes an uncommon case of adrenal hematoma and contusion followed by blunt abdominal trauma. A 35-year-old woman admitted to the emergency department after a high-speed vehicle-pedestrian collision. She presented with decreasing level of consciousness and left flank hematoma, revealed by thoracoabdominal CT.

Discussion: Adrenal Gland Injury is an atypical detection among blunt traumas. Our case demonstrates several uncommon features of adrenal trauma. Generally, conservative therapy is a prior choice for treatment; however, it is greatly related to the patient's status.

Conclusion: Diagnosis is based on clinical symptoms, particularly in isolated patients, usually misdiagnosed.

Keywords: Adrenal gland injury; Trauma; Adrenal hematoma

Abbreviations

CT: Computed Tomography; AGI: Adrenal Gland Injury; IVC: Inferior Vena Cava; LOC: Level of Consciousness; GCS: Glasgow Coma Scale; AFAST: Abdominal-Focused Assessment Sonography for Trauma; CE-CT: Contrast-Enhanced Computed Tomography Scan; ICU: Intensive Care Unit; DAI: Diffused Axonal Injury; CBC: Complete Blood Count; BUN: Blood Urea Nitrogen; Cr: Creatinine; VBG: Venous Blood Gas; AH: Adrenal Hematoma; MRI: Magnetic Resonance Imaging

Introduction

Adrenal Gland Injury (AGI) is known as an intermittent and largely coincidental finding, likely to happen in high or low blunt torso trauma. This fatal type of trauma is not usually diagnosed properly, especially if isolated [1]. Isolated AGIs occurs in approximately 1.5% to 4% of all adrenal trauma cases [2]. Prior to the invention of CT, AGIs were almost exclusively identified on postmortem examinations and were mostly associated with severe injuries [3]. Adrenal Hematoma (AH), accounts for 1.9% of trauma patients who underwent CT, or 0.8% of all patients enter the trauma registry [4]. Adrenals are paired retroperitoneal ductless glands located at the superomedial of kidneys on the level of the 11th ribs. Despite their small size, averaging less than 5 cm in length and roughly 4 g in weight, adrenal veins may

present a multitude of anatomical variants, which surgeons must be aware of during performing adrenalectomies. Clinically, the most common anatomical variants are those with one central vein draining each adrenal gland. Inferior phrenic vein and the left renal vein are the first and second destination of the long left adrenal vein, while the short right adrenal vein runs straightly into the Inferior Vena Cava (IVC) [5,6]. There are no specific signs or symptoms related to blunt adrenal gland trauma; it is an asymptomatic injury that is simply left undiagnosed, thought blunt adrenal gland trauma may lead to persistent hemorrhage, retroperitoneal hematoma, abscesses, and lethal adrenal crisis [7]. This study describes an uncommon case of isolated AGI due to blunt abdominal trauma in Iran.

Case Presentation

A 35-year-old Caucasian woman was admitted to the Emergency Department after a high-speed vehicle-pedestrian collision with decreasing in Level of Consciousness (LOC). Initially, the patient's vital signs were as followed: Blood pressure: 96 mmHg /91 mmHg, heart rate: 96 bpm, peripheral oxygen saturation (SpO₂): 97%, Temperature 36.8°C with Glasgow Coma Scale (GCS): 3/15 without any sort of sedative therapy. In regard to low LOC, she was intubated by emergency medical technicians at the accident scene without evidence of external bleeding, impaired breathing, ecchymosis, and lacerations on her chest or abdomen. Only some superficial abrasions visible on her left elbow and her left lower abdominal quadrant.

Laboratory and radiography results

There was no abnormal result on her blood analysis, metabolic or coagulation panel. Urinalysis showed no microscopic hematuria. Other modalities including chest, spine, and pelvis plain radiographs were obtained and found to be normal. A clinical radiologist performed Abdominal-Focused Assessment Sonography for Trauma (AFAST) in the Emergency Department and detected no evidence of contours or fluid. Due to the persistent hypotension, high force trauma, and decreased in the LOC, an abdominal Contrast-Enhanced

Citation: Fard HA, Bolandi S, Mohammadi Z. Isolated Adrenal Gland Hemorrhage: A Case of Car Accident. *J Surg Surgic Case Rep.* 2023;4(1):1033.

Copyright: © 2023 Hossein Abdolrahimzadeh Fard

Publisher Name: Medtext Publications LLC

Manuscript compiled: Apr 17th, 2023

***Corresponding author:** Zahra Mohammadi, Student Research Committee, Shiraz University of Medical Sciences, Shiraz, Iran, Tel: +98-9165271984; E-mail: Z_mohammadi@icloud.com

Computed Tomography Scan (CE-CT) with the suspension of AGI was performed. The CT showed round shape enlargement of the left adrenal (51 mm × 68 mm) and linear shape lesion (58 mm × 61mm) with increased density (60HU-70HU), and left diaphragmatic crus thickening with extravasation of the intravascular contrast in the portal phase from the left superior adrenal vein. No injuries to any other organs were spotted, specifically solid organs, and a brain CT scan showed no abnormalities or any structural deformities. The diagnosis of an isolated Adrenal Hematoma (AH) was made (Figure 1).

As a result, she received a bag of pure packed cells and one liter crystalloid; subsequently she was admitted in the Intensive Care Unit (ICU) for preservative treatment and further monitoring. Her vital signs were stable during the first six hours of ICU admission. Afterward, her status gradually deteriorated with hypotension and tachycardia. Therefore, she was transferred to the operation room and after resuscitation, *via* mid-line incision, the abdomen was explored and a nonexpanding hematoma in the left retroperitoneal zone was detected. Left medial visceral rotation hematoma was explored, then the injured left suprarenal vein (left adrenal vein) was ligated, hemostasis and irrigation were done, the abdomen was closed layer by layer and the patient was transferred to ICU with stable vital signs. The patient was hospitalized in ICU for one week. In the course of ICU admission, her LOC slowly increased. Brain CT revealed no abnormalities such as epidural and subdural hematoma. As a result, according to our neurologist consultant, a decrease in her level of consciousness was justified by undetectable Diffused Axonal Injury (DAI) on brain CT. She was discharged on oral antibiotics and analgesia.

The patient did not present new symptoms and the laboratory data such as CBC, BUN, Cr, urinalysis, VBG, and Adrenocorticotropic Hormone (ACTH) stimulation test were all normal.

Discussion

Adrenal glands weigh 4 g-5 g each in a standard healthy adult, located just below the crura of the diaphragm capping the superomedial pole of each kidney. The adrenal glands are highly vascular, although small with an estimated flow rate of about 5 ml per minute. Three critical arteries and up to fifty arterial branches supply each adrenal gland. These three main arteries include the superior, middle, and inferior suprarenal arteries. Blood is channeled into the adrenal cortex and drains into the adrenal medulla before entering the IVC *via* the central vein to the right adrenal [8,9].

The right adrenal, located in front of the 12th rib from in the lateral retroperitoneal view, which is a pyramid shape and more posteriorly than the left, is related to the IVC and right lobe of the liver. The left adrenal positioned in front of the 11th and 12th ribs is crescent in shape and surrounded by the pancreas and the spleen. Disregarding the various sizes and depths of adipose subcutaneous tissue, the adrenals are located in the middle of the abdominal cavity [10,11].

The venous plexus inside of the left adrenal gland is drained into the left adrenal vein (30 mm), which passes through downward, inferior, medial, and posterior to the body of the pancreas, then joins the inferior phrenic vein before entering the left renal vein 2 cm-5 cm from the IVC [12]. On the right side, vascular control of the adrenal vein is more complex. The shorter length of the right adrenal vein (6 mm) before emptying directly into the posterior part of the IVC, poses a high risk for injury of the vena cava with disastrous contusion and edema [10]. Hence, most studies have shown that the right adrenal is more likely to be involved with adrenal trauma.

Our case of AGI demonstrates several uncommon features of adrenal trauma. With respect to the fact that most AGIs are often related to specific traumatic events-for example, a car accident-and are usually associated with severe life-threatening injuries, our patient had no other thoracoabdominal injuries except an AH [13,14]. Results of laboratory, radiology, or other diagnostic tests revealed no other findings except isolated unilateral adrenal injury. Based on many studies, cases of isolated traumatic unilateral AGI are extremely rare [13].

Another unusual aspect of this case in comparison to previous studies is the injury of the left side adrenal gland. It is claimed that due to the anatomic and physiologic characteristics of the right adrenal, it is more susceptible to traumas [15].

Traumatic adrenal hematomas often have particular clinical presentations: the most repeated clinical picture is acute abdominal pain specifically in the right upper quadrant of the abdomen; other clinical symptoms are flank pain, fever, nausea, vomiting, hypotension, hypertension, palpable flank mass, agitation, sudden asthenia, and altered mental status [15,16]. Whereas due to the decrease in LOC of the current patient it was not possible to report pain or any other clinical symptoms.

Additionally, similar to the majority of patients with one side AGIs, our patient has normal lab parameters. Other notable results like leukocytosis and anemia might be present. Unilateral adrenal hemorrhage is biochemically silent. On the other hand, bilateral

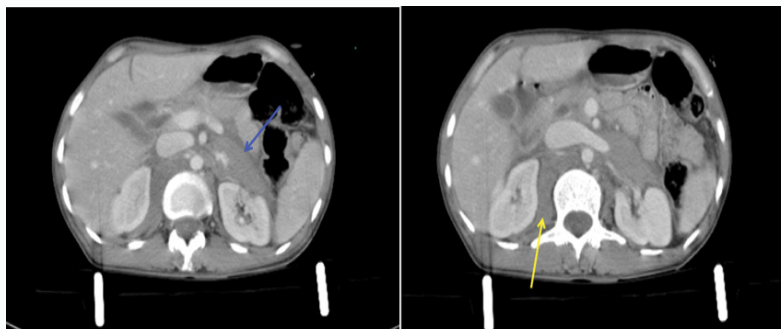


Figure 1: Round shape, well-defined lesion (51 mm × 68 mm) with high density (blue arrow) at the left anterior para renal space and a linear shape lesion (58 mm × 61mm) located at the right posterior perirenal space (yellow arrow), indicative of acute hematoma which is attributed to devascularization of left superior adrenal vein. No periadrenal fat stranding is noticed.

AGIs may also be detected with biochemical markers of adrenal insufficiency such as hyponatremia, hyperkalemia, hypoglycemia, and microscopic hematuria [17].

FAST is the most preferable tool by surgeons and radiologists for the diagnosis of AGI while searching in view of Morison's pouch or the splenorenal recess. However, similar to current patients, most of the cases are identified with abdominal CT by radiologists as it remains the most reliable modality which makes it possible to recognize many lesions that could not be evaluated by FAST [18]. Adrenal hemorrhage on CT scan appears as a round to ovoid lesion, may be contributed to peri-adrenal fat stranding and the bleeding which may extend into the perinephric space [19]. In our case, an unenhanced CT scan demonstrated a 60 HU-70 HU, hyper dense solid lesion with periadrenal fat stranding, which is suggesting adrenal hemorrhage.

Ultrasound sonography can detect clinically significant AGI, but can also fail due to the small size of the glands and the expert dependency of the examiner. Ultrasonography is the modality of choice in infants due to their small body size and relatively large adrenal size [11,20]. In our patient, the diagnosis was based on high clinical suspicion due to hypotension persistence and decreased LOC, and was confirmed by CT scan.

Magnetic Resonance Imaging (MRI) is an uncommon, yet the best accurate diagnostic modality. Management of AGIs or hemorrhage significantly grounds on the severity of the injury, the status of contralateral AG, hemodynamic stability. Adrenal hematoma by itself is typically a self-limited and benign lesion that does not require intensive care monitoring or operative intervention. However, AH should not be considered an incidental finding because of the possibility of significant hemorrhage requiring transfusion. Operative exploration is indicated when active bleeding along with unstable hemodynamic is evident [7,21,22]. As a result of unstable presentation in our case adrenalectomy was performed for her.

In adult patients in Iran, to our best of knowledge, there are no former described cases of isolated adrenal blunt injury.

Conclusion

Blunt adrenal injury is a rare phenomenon and frequently accompanied with multiorgan damage resulting from severe life-threatening accidents. Diagnosis based on clinical symptoms needs a high level of clinical suspicion and usually misdiagnosed in an emergency setting, particularly in isolated cases. Treatment is remarkably depending on the patient's status.

References

1. Stawicki SP, Hoey BA, Grossman MD, Anderson HL 3rd, Reed JF 3rd. Adrenal gland trauma is associated with high injury severity and mortality. *Curr Surg.* 2003;60(4):431-6.
2. Lehrberg A, Kharbutli B. Isolated unilateral adrenal gland hemorrhage following motor vehicle collision: a case report and review of the literature. *J Med Case Rep.* 2017;11(1):358.
3. DiGiacomo JC, Angus LD, Coffield E. Adrenal Injuries: Historical Facts and Modern Truths. *World J Surg.* 2017;41(4):975-9.
4. Rana AI, Kenney PJ, Lockhart ME, McGwin G Jr, Morgan DE, Windham ST 3rd, et al. Adrenal gland hematomas in trauma patients. *Radiology.* 2004;230(3):669-75.
5. Cesmebasi A, Du Plessis M, Iannatuono M, Shah S, Tubbs RS, Loukas M. A review of the anatomy and clinical significance of adrenal veins. *Clin Anat.* 2014;27(8):1253-63.
6. Angara V, Digiacoimo JC. Adrenal gland injury due to gunshot. *Chin J Traumatol.* 2020;23(3):149-51.
7. Liao CH, Ouyang CH, Fu CY, Wang SY, Lin KJ, Kuo IM, et al. The current status and management of blunt adrenal gland trauma. *Surgery.* 2015;157(2):338-43.
8. Yeoh P. Anatomy and Physiology of the Adrenal Gland. *Advanced Practice in Endocrinology Nursing.* 2019:645-55.
9. Willenberg H, Bornstein S. Adrenal cortex; development, anatomy, physiology. *Endotext.* 2017.
10. Avisse C, Marcus C, Patey M, Ladam-Marcus V, Delattre JF, Flament JB. Surgical anatomy and embryology of the adrenal glands. *Surg Clin North Am.* 2000;80(1):403-15.
11. Papadopoulos KS, Strigklis K, Kordeni K, Xaplanteri P, Zacharis G. Adrenal gland injury after blunt abdominal trauma: Two case series and review of the literature. *Int J Surg Case Rep.* 2020;67:34-8.
12. Siebert M, Robert Y, Didier R, Minster A, M'Sallaoui W, Bellier A, et al. Anatomical Variations of the Venous Drainage from the Left Adrenal Gland: An Anatomical Study. *World J Surg.* 2017;41(4):991-6.
13. Addeo G, Cozzi D, Danti G, Bertelli E, Ferrari R, Pradella S, et al. Multi-detector computed tomography in the diagnosis and characterization of adrenal gland traumatic injuries. *Gland Surg.* 2019;8(2):164-73.
14. DiGiacomo JC, Gerber N, Angus LDG, Munnangi S, Cardozo-Stolberg S. Blunt Adrenal Injury: Results of a State Trauma Registry Review. *Am Surg.* 2019;85(4):390-6.
15. Ortu M, Vaccarezza M, Trovati S, Galli M, Gervasoni C, Vella A. A martial arts injury: karate induced unilateral haematoma of the adrenal gland. *Br J Sports Med.* 2006;40(8):730-1; discussion 731.
16. Lin YH, Wu T. Isolated adrenal hemorrhage after blunt trauma: case report and literature review. *Urological Science.* 2013;24(1):27-9.
17. Mehrazin R, Derweesh IH, Kincade MC, Thomas AC, Gold R, Wake RW. Adrenal trauma: ELVIS Presley Memorial trauma center experience. *Urology.* 2007;70(5):851-5.
18. Matsushima K. Traumatic Adrenal Gland Hematoma: FAST Is an Effective Tool to Screen. *J Trauma.* 2009;67(3):676.
19. Sacerdote MG, Johnson PT, Fishman EK. CT of the adrenal gland: the many faces of adrenal hemorrhage. *Emerg Radiol.* 2012;19(1):53-60.
20. Kawashima A, Sandler CM, Ernst RD, Takahashi N, Roubidoux MA, Goldman SM, et al. Imaging of nontraumatic hemorrhage of the adrenal gland. *Radiographics.* 1999;19(4):949-63.
21. Roupakias S, Papoutsakis M, Tsikopoulos G. Adrenal injuries following blunt abdominal trauma in children: report of two cases. *Ulus Travma Acil Cerrahi Derg.* 2012;18(2):171-4.
22. Chen KT, Lin TY, Foo NP, Lin HJ, Guo HR. Traumatic adrenal haematoma: a condition rarely recognised in the emergency department. *Injury.* 2007;38(5):584-7.