

## Case Report

# Isolated Chest Wall Tuberculosis Presenting as an Abscess

Maalouf H<sup>\*</sup>, Ghattas S, Saber T and Malek A

Department of General Surgery, University of Balamand, Lebanon

## Abstract

Lebanon is a relatively low Tuberculosis burden country but has a high proportion of extrapulmonary tuberculosis. Tuberculosis involving the chest wall is found in around 1% of all skeletal tuberculosis cases. We present the case of an 81-year-old immunocompetent patient who presented with 3 months history of a painful lump in the anterior chest wall. PCR for MTB (mycobacterium tuberculosis) was positive and a diagnosis of the tubercular abscess of the chest wall was made mimicking a pyogenic abscess.

**Keywords:** Tuberculosis; Lump; Lung parenchymal disease; Micro organisms

## Introduction

Lebanon is considered to have a low incidence of Tuberculosis (TB) reaching 12 per 100 000 [1]. Nevertheless, the Mediterranean area compared to other regions has a high percentage of Extra-Pulmonary (EPTB) that can reach 24% [1]. In Lebanon, EPTB reached 37% of TB cases in 2015, more than double the percentage found globally [1].

TB involving the chest wall is found in around 1% of all skeletal TB cases [2]. The only presentation can be limited to a painless cold abscess for an extended period, making it more challenging to make a diagnosis [2,3].

It has been found that the formation of a tuberculous abscess can arise from direct extension of a pleural or lung parenchymal disease, hematogenous spread of a dormant tuberculous focus, or from a direct lymphatics extension of the chest wall [3,4].

The purpose of this report is to highlight the importance of clinical suspicion of an EPTB in a setting of vague symptoms of TB and to demonstrate the appropriate management. So here we present the case of an 81-year-old immunocompetent patient with a tuberculous abscess of the chest wall mimicking a pyogenic abscess.

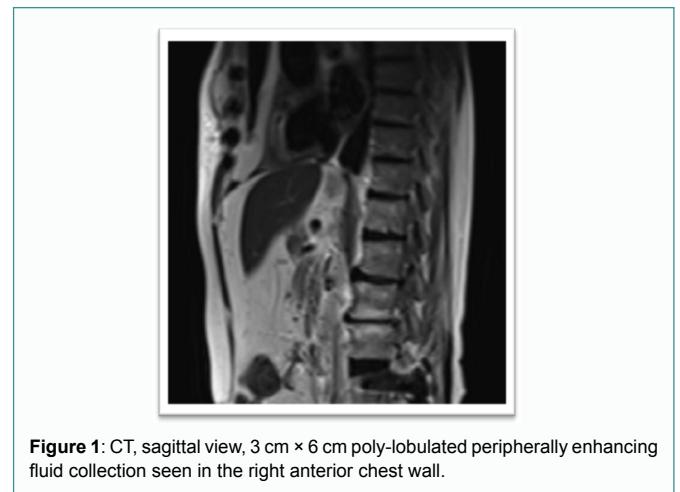
## Case Presentation

An 81-year-old Lebanese male presented with a painful lump over the right anterior chest wall for the past 3 months. The pain was confined and manageable by analgesics. There was no history of fever, cough, weight loss, or any respiratory symptoms. The patient reports that the swelling has increased in size since the presentation. There was no past history, social history, or family history suggestive of TB. On physical exam, the patient was a healthy-

looking male, a febrile with normal blood pressure and pulse. The respiratory system was normal on examination. A solitary lesion 3 cm × 6 cm was found over the sternum on the right side of the chest wall. The lesion was smooth, tender, and mobile with well-defined margins with negative involvement of the regional lymph nodes. His hematologic, liver and renal functions were within normal ranges. Chest X-ray was normal. Contrast-enhanced computed tomography of the thorax showed a 3 cm × 6 cm poly-lobulated peripherally enhancing fluid collection seen in the right anterior chest wall, at the level of 3<sup>rd</sup> and 4<sup>th</sup> ribs, with enhancement in the sternum suggestive of an abscess and suspicion of cortical erosion raising the possibility of osteomyelitis. No lung parenchyma or abdominal abnormalities and no lymphadenopathy were seen (Figures 1 and 2).

Biopsy or aspiration of the lesion was not advised and surgical drainage with debridement of the cavity and curettage of the bone with bone biopsy was done to rule out osteomyelitis. Specimen excised was sent to cytology, pathology, and culture. Closure was done after insertion of a penrose drain.

Culture of fluid showed pus and many neutrophils and no growth of micro-organisms. Cytology showed no abnormal cells. Pathology showed variably sized and confluent epithelioid and multinucleated giant cell granulomas centered by necrosis. PAS stain was negative for



**Figure 1:** CT, sagittal view, 3 cm × 6 cm poly-lobulated peripherally enhancing fluid collection seen in the right anterior chest wall.

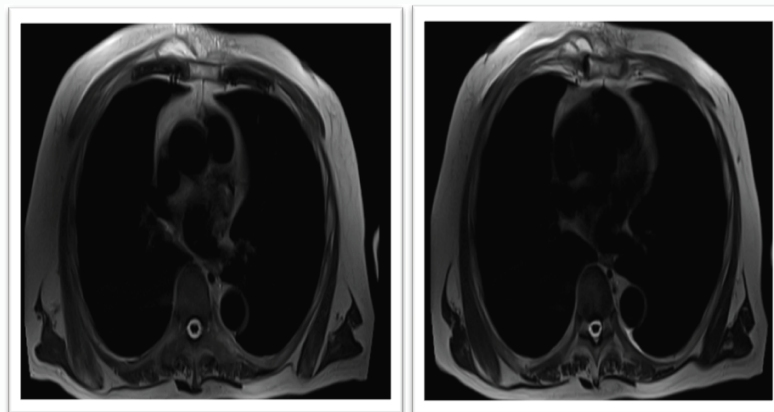
**Citation:** Maalouf H, Ghattas S, Saber T, Malek A. Isolated Chest Wall Tuberculosis Presenting as an Abscess. *Surg Clin J.* 2022; 3(1): 1046.

**Copyright:** © 2022 Hani Maalouf

**Publisher Name:** Medtext Publications LLC

**Manuscript compiled:** Sep 21<sup>st</sup>, 2022

**\*Corresponding author:** Hani Maalouf, Department of General Surgery, Saint Georges Hospital University Medical Center, University of Balamand, Beirut, Lebanon, E-mail: hani.maalouf3@gmail.com



**Figure 2:** CT, transverse view, 3 cm × 6 cm poly-lobulated peripherally enhancing fluid collection seen in the right anterior chest wall.

fungal organisms. Ziehl Neelson stain failed to reveal mycobacterial organisms. PCR for MTB finally turned out to be positive. A chest scan done to rule out lung involvement or fistula to the lungs was normal. Sputum for acid-fast bacilli was negative. Tuberculin skin test was positive (15 mm in duration) after 48 hours. A diagnosis of a tubercular abscess was made. Patient will be started on anti-TB treatment for 6 months.

## Discussion

Primary chest wall TB is uncommon with ribs involvement reaching 2% while sternum and sternoclavicular joints 1% to 2% of the total cases of musculoskeletal TB [3]. The diagnosis is therefore challenging in most of cases since the lesions simulate pyogenic abscess or tumor [4]. Especially if pulmonary TB is not associated, a high index of suspicion for EPTB should be kept in mind [2].

TB of the chest wall occur as solitary lesions such as a cold abscess and non-healing sinus tract in the chest wall, however, with a lack of history of exposure and presence of active TB in the chest, such isolated involvement of the chest wall can be quite a diagnostic dilemma for the physicians and radiologists [5]. Differential diagnosis of chest wall lesions includes granulomatous diseases such as sarcoidosis, chronic infections including fungal and parasitic infections, and malignancies such as lymphomas and metastasis [2]. It can affect the sternum, ribs shafts, costochondral junctions, costovertebral joints, and the vertebrae [6].

Pyogenic infections of the sternum, unlike TB infection, are more aggressive as they can lead to the destruction of the cartilage due to the release of proteolytic enzymes, thus they frequently present with constitutional symptoms as compared to TB infection that can have an indolent course with vague symptoms as in our case [7].

A preoperative diagnosis of primary chest wall TB is difficult and sometimes elusive. An initial needle aspiration guided by ultrasound can help to rule out other etiologies but alone is not reliable and surgical biopsy is usually required to establish a definite diagnosis [4]. CT scan helps to outline a bony involvement or destruction but a diagnosis of bone involvement or osteomyelitis is only made by bone biopsy [2,3].

Based on what has been said, surgical drainage and debridement were performed for our patient with studies and biopsies taken. What further justify our management are the possible complications of TB infection that include but are not limited to secondary infection, fistula

formation, spontaneous fractures of the sternum or ribs, compression or erosion of the large blood vessels, compression of the trachea, and migration of tubercular abscess into the mediastinum, and pleural cavity or subcutaneous tissues [2]. So surgical debridement and early drainage are crucial for preventing such complications and bone excision should be granted in case of bone involvement. Concomitant antitubercular treatment should be established. WHO recommends antitubercular treatment in cases of surgical or non-surgical treatment for a period of 6 months that can be extended up to 9 to 12 months according to clinical recovery [8].

In our case, no preoperative diagnosis of TB was made but incidentally, TB infection was found. It is reported that most cases of EPTB were diagnosed by postoperative pathology [5]. The culture of the fluid drained was sterile, cytology was negative and only the pathology showed giant cell granulomas that raised the suspicion of TB. What made our diagnosis even more difficult was the Ziehl Neelson stain that was negative for TB and only a PCR showed MTB. So, a high clinical suspicion should always be raised to diagnose EPTB. No consensus up until today is made on the diagnosis of EPTB (methods include Mycobacterial stain and culture, biopsy, body fluid examination, nucleic acid amplification test, Immunological tests,...), and only a combination of biopsy, PCR, and culture was shown to be superior and would further increase the diagnostic accuracy as we did in our case [9, 10].

Treatment of chest wall TB is still controversial and there is no consensus on the optimal treatment and very few studies are published about this matter. Some authors suggest that medical treatment is effective alone; others believe that aggressive debridement with primary closure in addition to medical therapy is required to prevent complications and recurrence [4]. Keum et al. [5] reviewed 68 patients who underwent surgical treatment of tuberculous abscess and concluded that preoperative medical treatment and postoperatively to prevent recurrence should be done along with complete excision of the chest wall abscess and periosteal excision if involvement is found.

## Conclusion

Chest wall TB is rare. Anterior chest wall pain and swelling are early manifestations, which makes the diagnosis difficult as it mimics other etiologies. High clinical suspicion for EPTB should be kept when facing such presentation. Initial needle aspiration may help to rule out other infectious or malignant etiologies but definite treatment is surgical drainage and biopsy to avoid serious complications such as

bone and joint destruction. A combination of biopsy, PCR, and culture raises diagnostic accuracy. Postoperative anti-tubercular treatment is mandatory to prevent recurrence.

## References

1. O'Son L, Hulland E, Cookson ST, Castro KG, Yaacoub H. Epidemiology and risk factors for extrapulmonary tuberculosis in Lebanon. *Int J Tuberc Lung Dis*. 2020;24(4):414-9.
2. Anand P, Sarin N. Isolated sternal tuberculosis presenting as a chest wall abscess: a case report. *Iran J Med Sci*. 2018;43(3):440-3.
3. Boruah DK, Sanyal S, Sharma BK, Prakash A, Dhingani DD, Bora K. Role of Cross Sectional Imaging in Isolated Chest Wall Tuberculosis. *J Clin Diagn Res*. 2017;11(1):TC01-6.
4. Sonhaye L, Amadou A, Gnandi-Piou F, Assih K, Tchaou M, Kolou B, et al. Tuberculous Abscess of the Chest Wall Simulate Pyogenic Abscess. *Case Rep Radiol*. 2015;2015:195412.
5. Keum DY, Kim JB, Park CK. Surgical treatment of a tuberculous abscess of the chest wall. *Korean J Thorac Cardiovasc Surg*. 2012;45(3):177-82.
6. Faure E, Souilamas R, Riquet M, Chehab A, Le Pimpec-Barthes F, Manac'h D, et al. Cold abscess of the chest wall: a surgical entity? *Ann Thorac Surg*. 1998;66(4):1174-8.
7. Khan SA, Varshney MK, Hasan AS, Kumar A, Trikha V. Tuberculosis of the sternum: a clinical study. *J Bone Joint Surg Br*. 2007;89(6):817-20.
8. Raviglione MC, Uplekar MW. WHO's new Stop TB Strategy. *Lancet*. 2006;367(9514):952-5.
9. Lee JY. Diagnosis and treatment of extrapulmonary tuberculosis. *Tuberc Respir Dis (Seoul)*. 2015;78(2):47-55.
10. Papavramidis TS, Papadopoulos VN, Michalopoulos A, Paramythiotis D, Potsi S, Raptou G, et al. Anterior chest wall tuberculous abscess: a case report. *J Med Case Rep*. 2007;1:152.