American Journal of Surgery Case Reports

Case Report

Novel Approaches to Complex Chest Wall Reconstruction Using a Combination of Two Titanium-Based Plating-Systems

Mark A. Splittgerber[3], Wei Wei Zhang[3], Carla C. Moodie[1], Joseph R. Garrett[1], Matthew E. Hiro[2,3], Erin L. Doren[2,3], William J. Moss[2,3], Deniz Dayicioglu[2,3], and Eric M. Toloza[1,3,4]

[1]Department of Thoracic Oncology, Moffitt Cancer Center, Tampa, FL, USA

[2]Department of Plastic Surgery Service, Moffitt Cancer Center, Tampa, FL, USA

[3]Department of Surgery, University of South Florida Health Morsani College of Medicine, Tampa, FL, UISA

[4]Department of Oncologic Sciences, University of South Florida Health Morsani College of Medicine, Tampa, FL, UISA

Abstract

Introduction: Reconstruction of complex chest wall defects is a surgical challenge following large thoracic tumor resections. We report the first known case of combining two titanium plating systems which use different fixation methods (Synthes ® uses screws, and Stratos ® uses clips) to repair chest wall defects that were not reparable with either plating system alone.

Case presentation: A 59-year-old woman, with prior left modified radical mastectomy for breast cancer, had subsequent recurrent breast cancer requiring radical left axillary and en bloc resection of her left clavicle and left 1st to 3rd ribs and reconstruction with titanium plates combined from the Stratos rib plating system and from Synthes mandible and fragmentation plating systems. She was discharged home on Postoperative Day (POD) #10, complicated only by left subclavian vein thrombo-occlusion. After 15 months, she developed left chest wall breast cancer recurrence requiring resection of her mid sternum, underlying pericardium, and medial aspects of left 2nd to 5th ribs, including the anteromedial ends of existing left 1st and 3rd rib titanium plates. The pericardial defect was patched with biologic mesh. The sternum was reconstructed with longitudinally-positioned modified Synthes titanium sternal plates. The left chest wall was reconstructed with a Synthes titanium sternal plate connecting the right 4th rib to existing left 2nd rib Stratos titanium plate, using a left 5th rib segment to bridge the new Synthes and old Stratos rib plates. Two halves of a Synthes titanium mandible plate reconstructed left 5th and 6th rib defects. The left chest wall soft tissue defect was reconstructed with biologic mesh and pedicled vertical rectus abdominus myocutaneous flap. She was discharged home on POD#5, without complications.

Discussion/conclusion: We report a case where we combined two different types of plating-systems as well as novel techniques to reconstruct chest wall defects that were not amenable to reconstruction with either screw-fixation plating system versus clip-fixation plating system alone.

Keywords: Chest wall mass; Chest wall resection; Chest wall reconstruction; Titanium plates

Introduction

Reconstruction of complex chest wall defects is a surgical challenge that one may encounter in a variety of clinical scenarios ranging from trauma to resection of large thoracic tumors. The goals of chest wall reconstruction include establishing protection for the underlying structures, maintenance of acceptable musculoskeletal functionality, providing a rigid framework to allow for adequate respiratory mechanics without paradoxical wall motion, avoidance of infectious and wound complications, and restoration of reasonable cosmetic appearance. Accomplishing these goals can be a daunting task when dealing with large chest wall defects, and to date no single method of reconstruction has proven to be superior in all contexts.

In recent years, a variety of new devices have emerged as options for repair of the thoracic cage and that have been used with success in multiple case reports and small case-series. One strategy that has shown promising early results is the use of titanium prostheses to replace the skeletal framework in large chest wall defects. Two titanium-based plating-systems now available for use in thoracic surgery are the (Stratos®) (MedXpert GmbH, Eschbach, Germany), which Strasbourg Thoracic Osteosyntheses System uses connecting bars with clips, and the Synthes® system (West Chester, PA, USA), which is based on plates with screw fixation. While several authors have demonstrated effective use of these systems individually, they each have their own inherent weaknesses that limit the spectrum of chest wall defects for which they can be used. We present the first known case report of chest wall reconstruction using a combination of both the Stratos and Synthes titanium plating-systems to repair a complex defect that would not have been amenable to repair with either of these systems individually. We also describe novel techniques

Citation: Splittgerber MA, Zhang WW, Moodie CC, Garrett JR, Hiro ME, Doren EL, et al. Novel Approaches to Complex Chest Wall Reconstruction Using a Combination of Two Titanium-Based Plating-Systems. Am J Surg Case Rep. 2021;2(2):1012.

Publisher Name: Medtext Publications LLC

Manuscript compiled: May 21th, 2021

***Corresponding author:** Eric M Toloza, MD, Ph.D, Department of Thoracic Oncology, Moffitt Cancer Center, 12902 USF Magnolia Drive, Suite CSB-6 (ThorProg), Tampa, FL 33612, USA, Tel: +1-813-745-7282; Fax: +1-813-449-8446; E-mail: eric.toloza@moffitt.org

for reconstruction of the chest wall that may broaden the limits of our ability to re-build the thoracic cage.

Comparing the Stratos "Bar-and-Clip" and the Synthes "Plate-and-Screw" Plating Systems. The Stratos system (see Figure 1, top panel) consists of titanium bars of varying lengths with titanium clips that can be attached on either end of the bars and that can be secured around the patient's ribs on either side of a defect using specialized pliers. The bars can be bent to optimally fit the contour of the chest wall, and the clips are available in three different angles that allow the bars to be connected to rib stumps at different angles within various chest wall defects. In addition to the variety of configurations that can be created, the most unique advantage of the Stratos system is provided by the pliable clip attachments, which allow the surgeon to secure the ends on either side of the defect with angled pliers and with minimal dissection of the overlying tissues. This is one advantage over plate-and-screw systems (such as the Synthes system) that require insertion of the screws at a perpendicular angle to the rib, which then necessitates more mobilization of tissues at the periphery of the wound in order to create space to accommodate the drill and the subsequent screwdriver. The tradeoff is that, although less dissection may be required, the Stratos bar-and-clip system can only be attached to intact ribs within a certain size range and, thus, cannot be secured to vertebrae posteriorly, to the sternum anteriorly, or to ribs that are particularly large or particularly small.

The Synthes system (see Figure 1, bottom panel) also makes use of titanium plates. However, in contrast to the clips used by the Stratos system, the Synthes plates are secured to adjacent bony structures with titanium screws. The Synthes rib plates come pre-contoured to the average rib shape and are available in a variety of sizes with holes along the length of the bars to permit screw placement at a variety of locations, which allows for some degree of customizability with this system as well. The Synthes sternal plates come with a U-shaped pin at their midpoints which allow disconnection of the two sternal plate halves in case of need for emergency re-entry after recent closure of the sternum with these sternal plates. An advantage of the Synthes system is that, since the plates are attached with screw-fixation, they can potentially be secured to any bony structure of adequate size and stability (not just ribs within a limited size range). Furthermore, Synthes plating systems are available for many other skeletal structures, such as mandible, clavicle, and fragmentation plates, and, therefore, a multitude of plates of various sizes and shapes are available for various applications. However, the space required to screw the plates into place requires that the space overlying the attachment site be exposed to a greater degree and, thus, may require more extensive tissue mobilization, which may be a task that may be problematic with defects that involve anatomically challenging locations, such as under the scapula.

In the reconstructive procedure we present in this case report, we have taken advantage of the strengths of both these plating systems and applied them, in combination, to the reconstruction of a complex axillary chest wall defect and subsequently a similarly complex anterolateral chest wall defect that would not have been easily amenable to reconstruction with either system alone.

Case Presentation

We present the case of a 59-year-old woman with history of left breast cancer and previous left modified radical mastectomy and who 16 months later had a recurrence in the left axilla requiring a radical left axillary mass resection with en bloc chest wall resection,

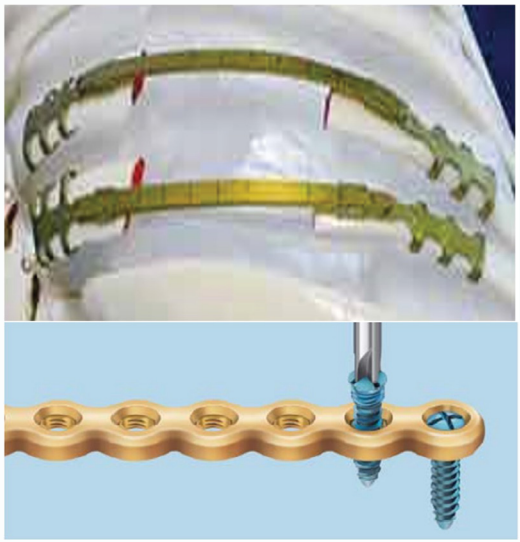

Figure 1: Illustration of Stratos "bar-and-clip" rib-plating system (top panel) and of Synthes "plate-and-screw" rib-plating system (bottom panel).

followed by complex chest wall reconstruction with titanium plates. Unfortunately, she had yet another recurrence 15 months subsequently with a large and painful left parasternal chest wall tumor involving portions of her previous reconstruction.

During the previous operation to treat her left axillary recurrence, the patient had portions of the left clavicle and of her left 1st, 2nd and 3rd ribs resected as part of the left axillary chest wall resection. The resulting defect had been reconstructed with two Stratos titanium rib plates, which bridged the defect by attaching to the left 2nd and 3rd rib stumps posteriorly and to the left 3rd costal cartilage stump and left 4th rib, respectively, anteriorly (Figure 2, white arrows). A Synthes unilateral mandible plate was used to reattach the left 1st rib to the left hemi manubrium (Figure 2, yellow arrow), and a Synthes fragmentation plate was used to reconstruct the left clavicle (Figure 2, orange arrow). An absorbable mesh had then been placed to recreate the chest wall soft tissue over the frame created by the titanium rib plates.

Her new left parasternal chest wall tumor recurrence (Figure 3) was involving not only the mid sternum, including the inferior end of the existing left 1st costosternal Synthes plate, but also the anteromedial clip of the existing Stratos plate connecting the posterior left 2nd rib stump to the left 3rd costal cartilage, the anteromedial left 4th rib, and the underlying pericardium. In order to adequately resect the tumor with clear margins, a substantial en bloc resection was required, which was roughly circular at the skin level, with diameter measuring 15 cm (Figure 4, top panels). Medially, the involved sternum was resected from approximately the 1st to the 5th intercostal spaces (Figure 4, bottom panel, white brackets), including division of the inferior end of the involved left 1st costosternal Synthes plate, with a portion of manubrium remaining superiorly and only a small segment of inferior sternum intact between the bilateral costal margins. Laterally, the left 5th rib was divided lateral to the tumor as was the left 4th rib (Figure 4, bottom panel, white arrows), although the existing Stratos plate that bridged the posterior left 3rd rib to the anterolateral left 4th rib was uninvolved by tumor and was kept intact. The other existing Stratos rib plate that bridged the posterior left 2nd rib stump to left 3rd costal cartilage was divided lateral to the tumor margin with a plate cutter

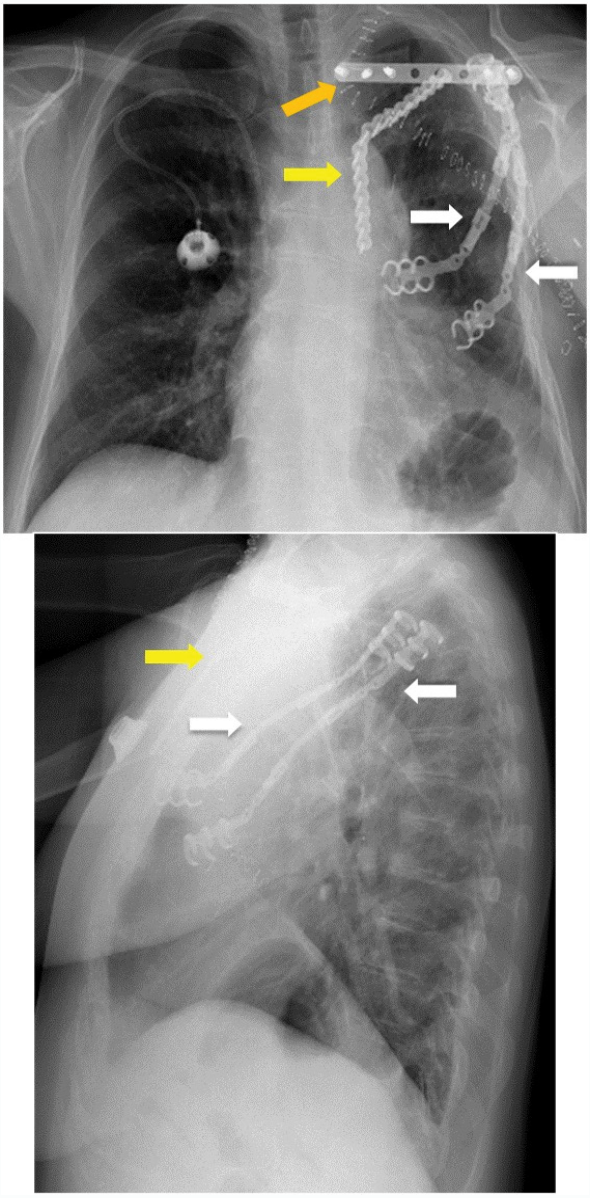

Figure 2: After radical left axillary and en-bloc resection of left clavicle and left 1st to 3rd ribs for recurrent left breast cancer, chest radiograph Posterior-Anterior (PA; top panel) and lateral (bottom panel) views show reconstruction performed with titanium plates combined from the Stratos rib plating system to reconstruct the left 2nd and 3rd ribs (white arrows) and from Synthes mandible and fragmentation plating systems to reconstruct the left 1st rib (yellow arrow) and left clavicle (orange arrow), respectively.

(Figure 4, bottom panel, lateral black arrow). Finally, the tumor was found to be densely adherent to the underlying pericardium, which required en bloc resection of a 6-cm x 8-cm area of pericardium (Figure 4, bottom panel, dashed black circle). The radical resection specimen was then removed en bloc, leaving a large anterolateral chest wall defect that involved significant amounts of skin and left pectoralis muscle, the majority of the sternum, the anterolateral aspects of left ribs 2 to 5, and pericardium.

The pericardial defect was patched with a piece of biologic mesh (Figure 5, black arrow). Attention was then turned to the chest wall reconstruction, which was simplified by separately considering the two distinct challenges: reconstruction of the large sternal defect, and

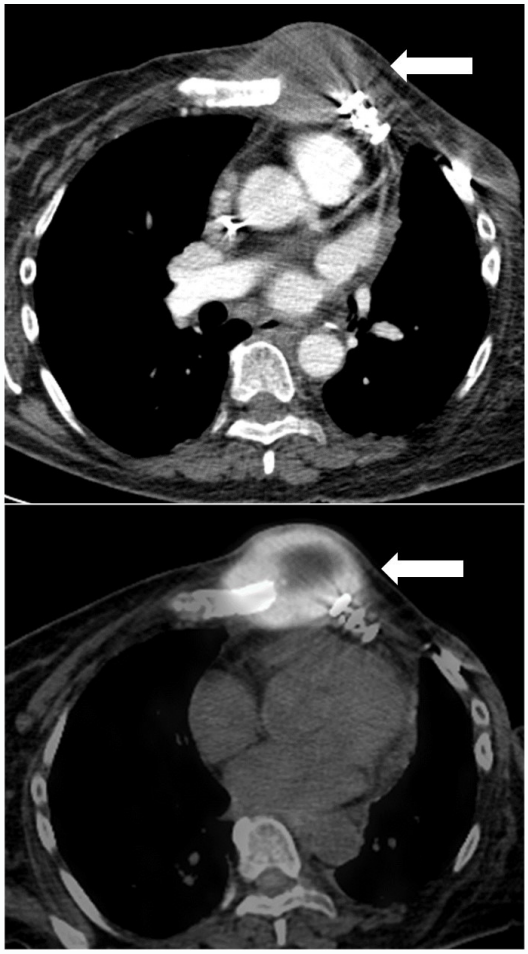

Figure 3: Axial image from Computerized Tomography (CT) scan (top panel) and fused axial images from positron-emission tomography (PET)-CT scan (bottom panel) showing the left parasternal chest wall recurrent breast cancer involving the sternum and medial end of the Stratos titanium rib plate attached to the left 3rd costal cartilage (arrows).

then reconstruction of the left anterolateral chest wall defect.

The sternal defect was the first challenge to be addressed in the reconstruction of the chest wall framework. Only the manubrium remained superiorly, along with a small amount of inferior sternum located below the level of the 5th intercostal spaces and connecting the bilateral costal margins. A long straight Synthes sternal plate was then brought onto the field and separated into two halves by removing the midline connecting clip. An angled Synthes sternal plate was then brought onto the field and separated into two halves in the same fashion. One of the straight plate halves was then connected to one of the angled plate halves by reinserting the connecting clip, producing a hockey-stick-shaped plate. This was repeated with the other straight and angled plate halves to create another mirror-image hockey-stick-shaped plate, and these two de novo plates were then placed longitudinally to bridge the defect between the manubrium superiorly and the remaining sternum inferiorly, one de novo plate on the left side and the other on the right. The plates were then screwed to the manubrium superiorly and to the medial right and left costal margins inferiorly, creating a neo-sternum made of two parallel Synthes plates (Figure 5, white arrows).

The next challenge was reconstructing the left anterolateral chest

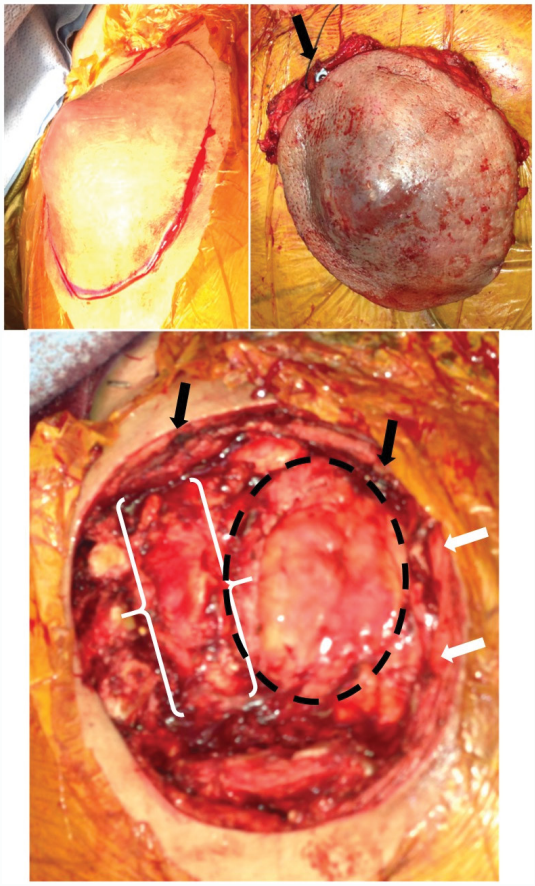

Figure 4: Photos showing left anterior oblique (top left) and anterior (top right) views of radical resection of the left parasternal chest wall breast cancer recurrence that required resection (bottom panel) of the mid sternum (white brackets), underlying pericardium (dashed black circle), the medial aspects of left 4th to 5th ribs (white arrows), and the anteromedial ends of existing left 1st and 2nd rib titanium plates (black arrows).

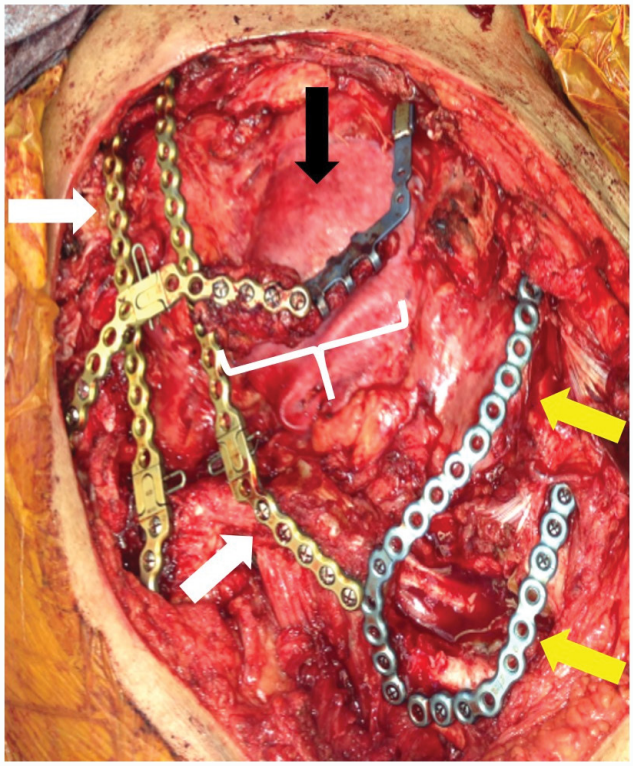

Figure 5: Photo showing the pericardial defect patched with biologic mesh (black arrow);the sternum reconstructed with longitudinally-positioned modified Synthes titanium sternal plates (white arrows);the left parasternal chest wall reconstructed with a Synthes titanium sternal plate connecting the right 4th rib to the existing left 2nd rib Stratos titanium plate using a left 6th rib segment (yellow arrow) to bridge the new Synthes plate and a new rib clip attached to the old Stratos rib plate; and the left 5th and 6th rib defects reconstructed with two halves of a Synthes titanium mandible plate (yellow arrows).

wall. Recall that the left 2nd rib had been resected during prior radical resection of the left axillary chest wall recurrence, and now the left 4th and 5th ribs as well as the Stratos plate, which was connecting the left 2nd rib posterior stump and the left 3rd costal cartilage, had been divided lateral to the tumor margin. The posterolateral end of the now divided Stratos plate remained clipped to the posterolateral left 2nd rib stump. While a new Stratos rib clip was able to be attached to the divided Stratos plate that remained attached to the posterolateral left 2nd rib stump, the current challenge was that anteriorly there was no suitable rib stump to re-attach the existing left 2nd rib Stratos plate, as the anterior left 3rd through 5th ribs had been resected en bloc with the sternal resection and the anterior left 2nd rib had been resected with the prior left axillary tumor recurrence.

Another angled Synthes sternal plate was, thus, brought onto the field and placed across the neo-sternum, and its right end was screwed onto the medial end of the right 4th rib (Figure 5). As there was no established method for connecting the two different plating systems to each other, a 6-cm portion of the left 6th rib was then harvested and used as an interposition rib graft to which both plating systems could be attached. The left end of the angled Synthes plate that was now crossing the neo-sternum was then secured to the medial end of this interposition rib graft. The new clip on the existing left 2nd rib Stratos plate was then clipped to the lateral end of this interposition rib graft. However, the first attempt to attach the Synthes and Stratos plates the interposition rib graft resulted in crushing of one end of the graft. This initial interposition rib graft previously harvested from the left 6th rib was removed, and another 6-cm rib segment was harvested from the left 5th rib, which then allowed successful attachment of the angled Synthes plate from the right 4th rib stump to the Stratos plate attached to the left 2nd rib stump posteriorly (Figure 5, white bracket). Lastly, a Synthes bilateral mandible plate was cut in half, and each of the two halves of the divided mandible plate was then used to reconstruct the left 5th and 6th ribs defects resulting from the interposition rib graft harvests, which completed reconstruction of the left chest wall framework (Figure 5, yellow arrows).

The end result was creation of a new sternum with Synthes plates, reconstruction of the bony left anterolateral chest wall using a Synthes sternal plate from a medial right rib to a repaired existing left Stratos titanium rib plate using an interposition rib graft, and repairing of two smaller rib defects with Synthes mandible plate segments. The anterolateral chest wall soft tissue defect was reconstructed by first placing a 15-cm x 20-cm oval piece of biologic mesh to cover the titanium plate framework, followed by native tissue coverage with a pedicled vertical rectus abdominus myocutaneous (V-RAM) flap (Figure 6).

The patient tolerated the operation well and was ultimately able to be discharged from the hospital on postoperative day #5, without

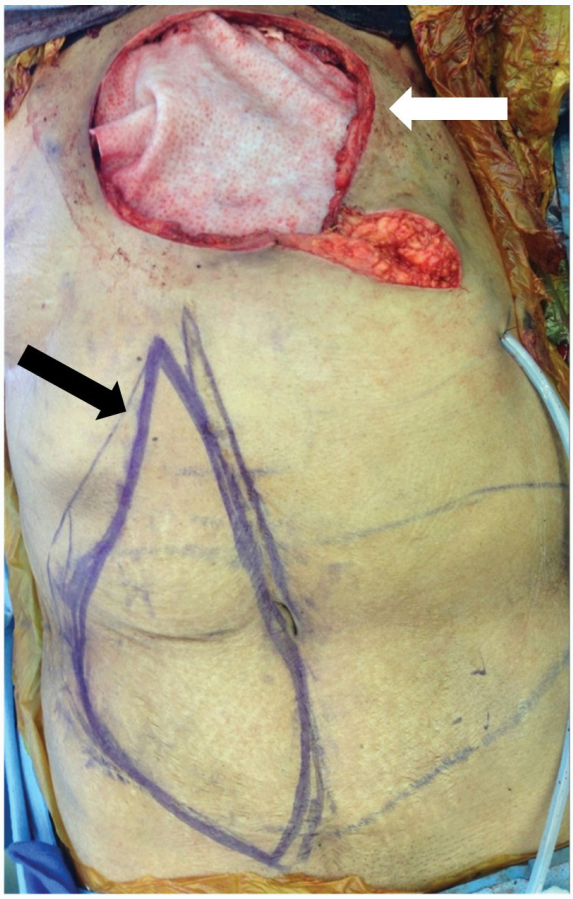

Figure 6: Photo of the left chest wall soft tissue defect reconstructed with a biologic mesh (white arrow) and of the outlined and soon-to-be harvested pedicled right vertical rectus abdominus myocutaneous flap (black arrow).

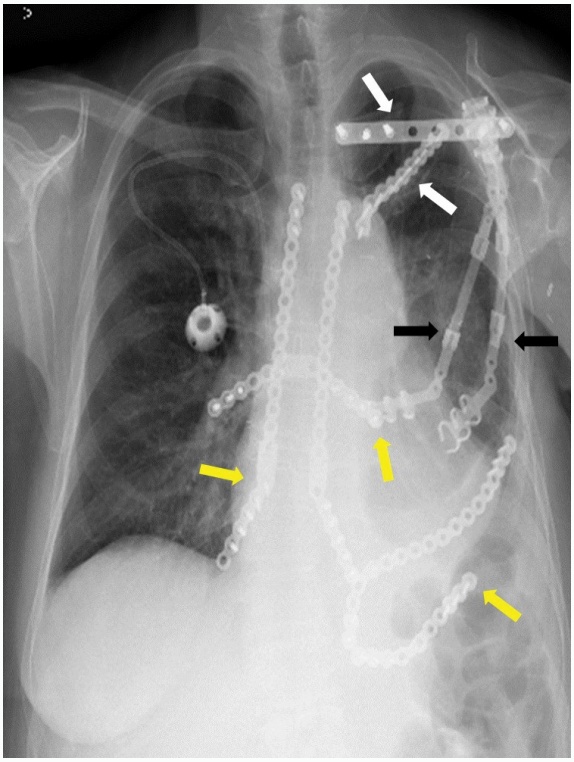

Figure 7: Chest radiograph showing combined use of two different types of plating-systems - screw-fixation plating system (white arrows) and clip-fixation plating system (black arrows)-to reconstruct the radical resection of the left axillary chest wall first recurrence of breast cancer and showing 3 novel uses of screw-fixation plates (white brackets) to reconstruct the radical resection of the left parasternal chest wall second recurrence of breast cancer.

complications. She survived for another 8 months after the radical resection of the second recurrence on her left parasternal chest wall and immediate chest wall reconstruction.

Discussion

The goals of chest wall reconstruction include establishing protection for the underlying structures, maintenance of acceptable musculoskeletal functionality, providing a rigid framework to allow for adequate respiratory mechanics without paradoxical wall motion, avoidance of infectious and wound complications, and restoration of reasonable cosmetic appearance. When chest wall defects are large or involving critical skeletal fixation points, these goals may be difficult to achieve, and reconstruction of large chest wall defects has been previously shown to result in overall complications rates of 24% to 46% [1-3], the most common of which are respiratory complications, which occur in 14% to 25% of all patients [1,2] following repair of such defects. Other potential complications include development of seromas and wound infections, as well as long-term concerns that are more difficult to quantify and include maintaining adequate tissue coverage, musculoskeletal function, and cosmetic results.

As with most surgical outcomes, the incidence of these complications appears to be dependent on a variety of patient, operative, and perioperative factors. One retrospective study of 262 patients who underwent chest wall resection at Memorial Sloan Kettering Cancer Center found that increasing patient age, size of chest wall defect, and performance of simultaneous anatomical lung resection were independent predictors of post-op complications [2]. However, patient comorbidities, extent of chest wall defect, and magnitude of the operation are not the only factors that need to be considered. Another crucial element in determining the success of a repair of a large chest wall defect is the strategy for reconstruction, of which there are now many options that can be implemented alone or in combination. These options include, but are not limited to, primary repair, complex autogenous coverage with native tissues (including advancement, rotational, and free tissue flaps), prosthetic coverage with either non-rigid mesh or rigid prosthetic implants, and now a variety of partially customizable plating-systems. The key to successful surgical reconstruction begins with choosing the right strategy for each individual defect, and as the size and complexity of chest wall defects can exhibit tremendous variability, the surgeon must have an equally diverse armamentarium of reconstruction strategies.

The purpose of this case report is not to suggest that our technique of combining plating-systems is superior to any other repair technique for all chest wall defects, but to demonstrate new techniques that may prove advantageous in specific clinical scenarios and may be copied or modified by future surgeons as these scenarios arise. In this report, we presented a case in which the anterior portion of our defect had limited fixation points and was only amenable to plate attachment with screws, while placing screws in the posterior portion would have required significant additional dissection and patient repositioning; making plate attachment with clips a more advantageous option. The option to combine both plating systems allowed us to re-create the

framework for nearly an entire hemithorax from anterior to posterior with secure attachments on both sides, limited posterior dissection, and no need for intra-operative patient re-positioning.

In addition, we describe the ability to separate the halves of Synthes sternal plates and then to connect these halves in various combinations using the original U-clip used to keep the halves together. We also describe the ability to use an interposition rib graft to be able to connect a Synthes plate to a Stratos plate. Finally, we describe the ability to use Synthes plates intended for a particular skeletal site at other skeletal sites, such as use of Synthes mandible plates to reconstruct ribs and Synthes fragmentation plates to reconstruct the clavicle as described in this case report.

If a similar chest wall defect is encountered in the future, these techniques may be valuable options for the treating surgeon to consider. More important than reproducing this exact repair, however, is making note of the technical aspects that allowed these novel approaches to be both advantageous to the patient and technically feasible for the surgeon, as the greatest benefit that our repair technique offers is the ability to be flexible and creative in performing chest wall repair. We hope that this report will serve to introduce yet other options in the surgeon's armamentarium that will permit more effective and more patient-specific repairs of complex chest wall defects.

Conclusion

We report a case where we combined two different types of plating systems as well as novel techniques to reconstruct chest wall defects that were not amenable to reconstruction with either screw-fixation plating system versus clip-fixation plating system alone.

Acknowledgements

This case report was presented in part at the 22nd European Conference on General Thoracic Surgery of the European Society of Thoracic Surgery (ESTS) in Copenhagen, Denmark in June 15th to 18th, 2014.

M.A.S. is currently a general surgeon with the Aurora General Surgery & Vascular Surgery group at Aurora St. Luke's Medical Center and at Aurora Sinai Medical Center, both in Milwaukee, WI, USA. W.W.Z is currently a trauma surgeon at the Rutgers New Jersey Medical School, Newark, NJ, USA. M.E.H. is currently a plastic surgeon at Bay Pines Veterans Affairs Medical Center, Bay Pines, FL, USA. E.L.D. is currently a plastic surgeon at the Medical College of Wisconsin, Wauwatosa, WI, USA. W.J.M. is currently an otolaryngologist at the University of California San Diego Medical Center, San Diego, CA, USA.

Informed consent

Permission was obtained from the patient for publication of this case report and any accompanying images for education purposes as part of our institutional surgical informed consent. A copy of the written consent is available for review by the Editor-in-Chief of this journal.

Conflict-of-Interest (COI) Disclosures

E.M.T. has had a financial relationship with DePuy-Synthes, a medical device company with Johnson & Johnson, in the form of consultation fees. No other authors have any COI to disclose.

References

1. Mansour KA, Thourani VH, Losken A, Reeves JG, Miller Jr JI, Carlson GW, et al. Chest wall resection and reconstruction: a 25-year experience. Ann Thorac Surg. 2002;73(6):1720-5.
2. Weyant MJ, Bains MS, Venkatraman E, Downey RJ, Park BJ, Flores RM, et al. Results of chest wall resection and reconstruction with and without rigid prosthesis. Ann Thorac Surg. 2006;81(1):279-85.
3. Deschamps C, Tirnaksiz BM, Darbandi R, Trastek VF, Allen MS, Miller DL, et al. Early and long-term results of prosthetic chest wall reconstruction. J Thorac Cardiovasc Surg. 1999;117(3):588-91; discussion 591-2.
4. Gonfiotti A, Santini PF, Campanacci D, Innocenti M, Ferrarello S, Caldarella A, et al. Malignant primary chest-wall tumours: techniques of reconstruction and survival. Eur J Cardiothorac Surg. 2010;38(1):39-45.
5. Fabre D, El Batti S, Singhal S, Mercier O, Mussot S, Fadel E, et al. A paradigm shift for sternal reconstruction using a novel titanium rib bridge system following oncological resection. Eur J Cardiothoracic Surg. 2012;42(6):965-70.
6. Berthet JP, Canaud L, D'Annoville T, Alric P, Marty-Ane CH. Titanium Plates and Dualmesh: A Modern Combination for Reconstructing Very Large Chest Wall Defects. Ann Thorac Surg. 2011;91(6):1709-16.
7. Bille A, Okiror L, Karenovics W, Routledge T. Experience with titanium devices for rib fixation and coverage of chest wall defects. Interact Cardiovasc Thorac Surg. 2012;15(4):588-95.
8. Aghajanzadeh M, Alavy A, Taskindost M, Pourrasouly Z, Aghajanzadeh G, Massahnia S. Results of chest wall resection and reconstruction in 162 patients with benign and malignant chest wall disease. J Thorac Dis. 2010;2(2):81-5.