American Journal of Surgical Techniques and Case Reports

ISSN: 2694-4901

Case Report

Osteochondral Fracture-Dislocation of the Humeral Head in Adolescent Patient: Open Reduction and Internal Fixation with Low Profile Compression Screws

David A Quinzi, Jason Lipof and John T Gorczyca*

Department of Orthopedic Surgery, University of Rochester Medical Center, New York, USA

Abstract

This case report describes an unusual injury in a 15-year-old female who sustained a glenohumeral fracture dislocation with osteochondral shear injury of the humeral head after being struck by a truck. The patient was treated emergently with a closed manipulation, after which radiographs depicted a large osteochondral humeral head fragment which was rotated 180° in the axial plane. She was treated with open reduction and internal fixation using low profile compression screws countersunk in the subchondral bone. She had excellent functional outcome at her 18-month follow-up visit.

Keywords: Trauma; Upper Extremity; Pediatrics; Orthopedics

Introduction

A 15-year-old right hand dominant female presented to our level one trauma center after being a pedestrian struck by a pickup truck traveling an estimated 30 mph. She was ambulatory and stable at the scene and was transported by EMS providers prior to presentation at our institution. In the trauma bay of the emergency room she was evaluated and treated according to advanced trauma life support guidelines. On secondary survey, she had significant left shoulder pain with deformity and inability to perform active motion of the left shoulder. The chest radiograph obtained in the trauma bay and a scout radiograph of the left shoulder demonstrated a fracture-dislocation of the left glenohumeral joint (Figure 1A-B). The orthopedic team noted that the patient was hemodynamically stable, communicated well, and had a deformed right shoulder. She was neurovascularly intact with appropriate hand and elbow function. She had a visible sulcus sign.

A closed reduction of the left shoulder under conscious sedation was performed using traction and internal rotation. A palpable clunk was appreciated, after which the patient remained neurovascularly intact and was able to contract her deltoid muscle. Post-reduction imaging demonstrated a non concentric reduction with a large entrapped osteochondral fragment within the glenohumeral joint (Figure 2A and B). A Computed Tomography (CT) scan was obtained for further characterization of the injury (Figure 3). After a discussion of the treatment options, risks, and benefits, the patient and her family wished to proceed with open reduction and internal fixation of the fracture.

Citation: Quinzi DA, Lipof J, Gorczyca JT. Osteochondral Fracture-Dislocation of the Humeral Head in Adolescent Patient: Open Reduction and Internal Fixation with Low Profile Compression Screws. Am J Surg Tech Case Rep. 2020;1(2):1008.

Publisher Name: Medtext Publications LLC

Manuscript compiled: Aug 28th, 2020

***Corresponding author:** David A Quinzi, Department of Orthopedic Surgery, University of Rochester Medical Center, 601 Elmwood Ave, Rochester, New York, 14642, USA, Tel: 5857374556; E-mail: David_Quinzi@urmc.rocehster.edu

Case Presentation

Surgical intervention

The patient was placed supine on a radiolucent trauma table which had been rotated 180° so that the pillar was at the feet to allow for

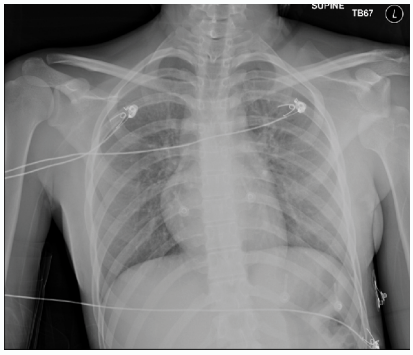

Figure 1A: AP Chest radiograph upon arrival to Trauma Bay reveals left glenohumeral dislocation with defect in humeral head.

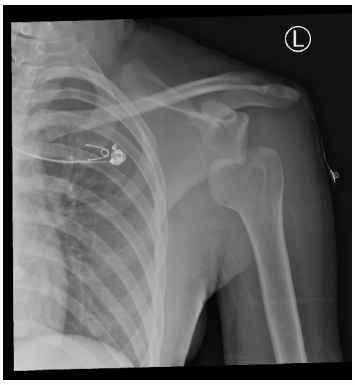

Figure 1B: AP radiograph of the left shoulder prior to manipulation.

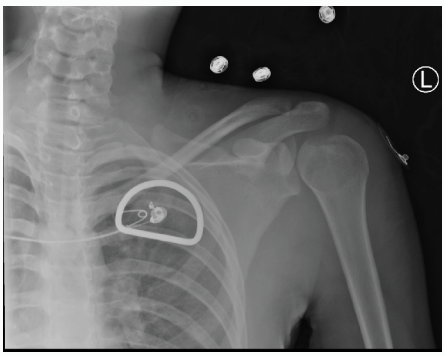

Figure 2A: AP radiograph of left shoulder after reduction attempt depicts entrapped intraarticular osteochondral fragment.

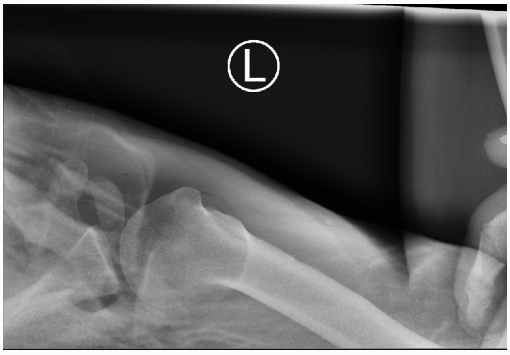

Figure 2B: Axillary Lateral View radiograph after reduction attempt reveals intraarticular osteochondral fragment.

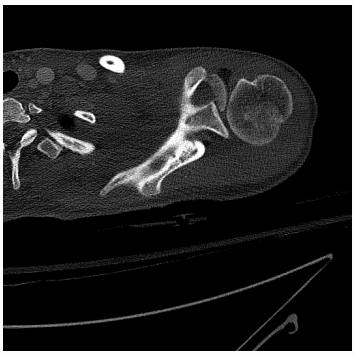

Figure 3A: Axial cut of CT scan left shoulder with entrapped osteochondral fragment.

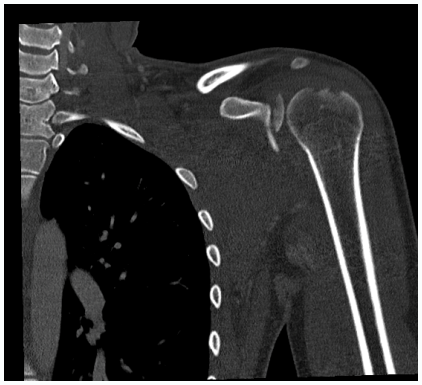

Figure 3B: Coronal reconstruction of CT scan Left shoulder shows osteochondral fragment that appears to be rotated 180° in the axial plane.

Figure 3C: Sagittal CT reconstruction depicts defect in the superior humeral head articular surface.

unobstructed intraoperative fluoroscopic evaluation. The operative extremity and shoulder were prepped and draped freely in normal sterile fashion. The arm was supported by a padded Mayo stand to assist in positioning of the arm intraoperatively. Preoperative Ancef was administered and a surgical pause performed in accordance with institutional policy. Following this a standard deltopectoral approach was utilized with an 8 cm incision from the tip of the coracoid aimed towards the midpoint of the elbow flexion crease. The skin and subcutaneous tissues were incised and the subcutaneous tissues were dissected to identify the cephalic vein, which was retracted medially. Blunt dissection was used to develop the deltopectoral interval and expose the clavipectoral fascia which was incised longitudinally lateral to the conjoint tendon. The biceps sheath was incised. Next, the inferior subscapularis tendon was incised near its insertion on the lesser tuberosity. There was a traumatic capsulotomy which provided visualization into the joint. Upon further examination, it was felt that more exposure would be required to adequately visualize the fracture and to facilitate manipulation and reduction of the displaced osteochondral fragment. The remainder of the subscapularis tendon was then sharply incised, elevated from the capsule, and tagged for later repair. The fragment was visualized and gently retrieved from the joint using a freer elevator and pituitary forceps with care to protect the articular surface during retrieval.

The majority of the humeral head appeared unscathed except for the fracture fragment and a small area of impaction. On the back table, the impacted subchondral bone on the free piece was carefully elevated with tamp and Freer elevator until appropriately reduced. Attention was then turned to the fracture site which was thoroughly irrigated with normal saline and cleared of hematoma and fracture debris with a curette. The fracture fragment was then anatomically reduced into position and a provisional fixation was obtained with 2 diverging Kirschner wires.

After confirming appropriate reduction of the fragment, three 2.4 mm lag screws were inserted and countersunk beneath the articular cartilage into the subchondral bone (Figure 4). These provided excellent compression and an anatomic reduction as confirmed on final intraoperative fluoroscopy (Figure 5). The subscapularis tendon was repaired to its insertion on the lesser tuberosity using #2 non absorbable suture placed through drill holes. The biceps sheath and rotator interval were closed with 1-0 absorbable suture, followed by closure of the deltopectoral interval. 2-0 absorbable suture was utilized for the thin subcutaneous layer and the skin was closed with a 3-0 absorbable monofilament suture in running subcuticular fashion. She was then awakened from anesthesia without complication.

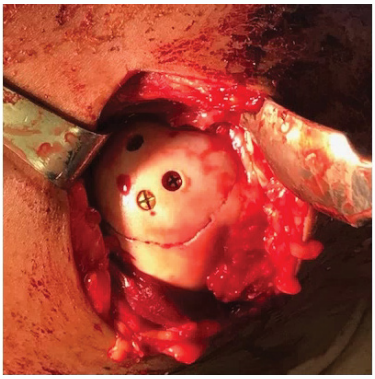

Figure 4: Intraoperative photograph shows final reduction of osteochondral fragment with screws countersunk below articular cartilage of humeral head.

Postoperative care/course

The patient was placed in a shoulder immobilizer immediately post-operatively and was restricted from bearing weight and from performing resistive activities with the extremity. On post-operative day 1 she was stable and comfortable and was discharged from the hospital. She was evaluated in clinic at 2 weeks and noted to be comfortable and compliant with her post-operative restrictions. Her incision was healed and she was instructed to perform a gentle active-assisted range-of motion exercise regimen three-times daily.

At her eight week follow-up, she had near normal active shoulder motion and radiographs showed that the fracture had healed. She was allowed to begin light weight bearing as tolerated and began formal physical therapy for strengthening without restriction. Secondary to the COVID-19 pandemic she did not return for1-year post-operative follow-up, but returned at 18 months and was noted to be comfortable and doing well. She reports being back to her pre-injury activities and work without issue. She reported occasional discomfort in her shoulder after she performed extensive activity, which was relieved by anti-inflammatory medication when needed. On examination, she had 180° forward flexion. With the shoulder in neutral, she had external rotation to 55 degrees (same as contralateral). With the arm abducted at 90 degrees she has a 10-degree deficit of external rotation as compared to the contralateral shoulder. Radiographs demonstrated a healed fracture, a congruent articular surface, good position of the screws, incorporation of the osteochondral fragment, and no evidence of osteonecrosis (Figure 6).

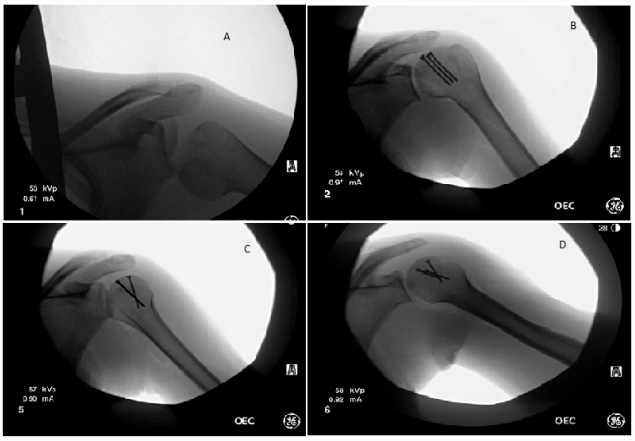

Figure 5: Intraoperative fluoroscopic images detail displaced fragment (a) and anatomic reduction and stabilization with three screws (b-d). Noted hill-sachs defect.

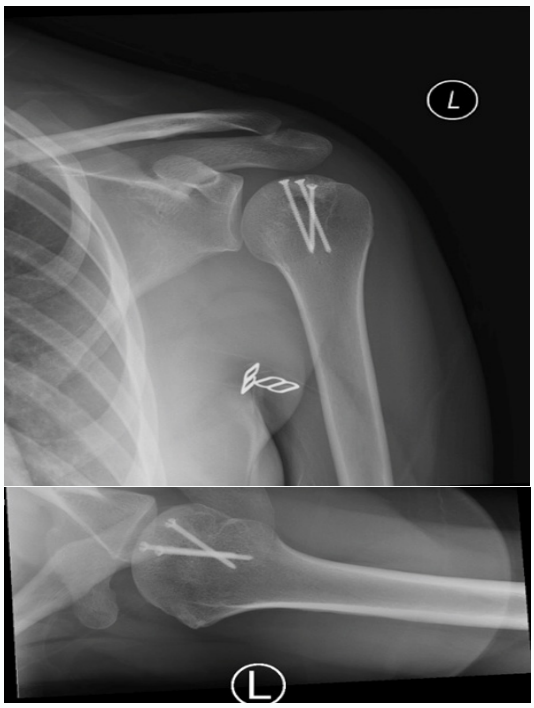

Figure 6: 18 month follow-up AP and axillary lateral radiographs demonstrate healed fracture, congruent articular surface, good incorporation of the osteochondral fragment, and no sign of a vascular.

Discussion

To our knowledge this is the first case of operative treatment of an osteochondral shear injury with entrapment of the osteochondral fragment after anterior shoulder dislocation. Fandridis et al. [1] reported on a single case of an osteochondral shear injury of the humeral head after a posterior shoulder dislocation after a high energy injury where the 26-year-old patient fell from a motorcycle high speed. The patient was managed with ORIF good appropriate results though at one-year follow-up the patient had not yet returned to his pre-injury level of activity. Furthermore, Choi et al. [2] reported on a single case of small minimally displaced osteochondral lesion sustained after an anterior shoulder dislocation in a 12-year-old that spontaneously reduced with closed reduction of the shoulder dislocation. The patient was managed non-operatively and returned to pre-injury function.

Avascular Necrosis (AVN) of the humeral head is a dreaded complication after proximal humerus fracture dislocations which would have long term negative impact on shoulder function, especially in a younger patient. Fracture-dislocation can damage the already tenuous blood supply to the humeral head. With regards to timing, Schentzke et al. [3] performed a retrospective study of 30 patients with proximal humerus fracture dislocations and advocated for performing surgery within 48 hours to minimize the risk of AVN; however their population was much older (mean age 63) and as such it is difficult to extrapolate these results to our setting. In our case the injury was an osteochondral fracture dislocation in an adolescent patient as opposed to the more common proximal humerus fracture dislocation seen in the geriatric patient.

Post-traumatic arthritis can also be a devastating complication which will compromise function and may warrant further intervention with shoulder arthroplasty or biologic resurfacing procedures [4]. Though considered a more rare complication with minimally displaced fractures, post-traumatic arthritis has been reported at a rate of 64% after more complex 3 and 4 part injuries regardless of treatment [5]. It should be noted that these studies focus mainly on geriatric populations and it is difficult to extrapolate these findings to our patient.

Conclusion

To our knowledge this is the first case of an articular shear injury with entrapped osteochondral fragment after anterior shoulder dislocation treated operatively. The patient was successfully treated with open reduction and internal fixation and regained her preoperative level of function without notable complications. We recommend this technique, which follows the principles of fracture surgery and joint preservation, for similar cases.

References

1. Fandridis E, Stavropoulos S, Dimou L, Spyridonos S. Osteochondral humeral head fracture after posterior shoulder subluxation: A case report. Int J Shoulder Surg. 2014;8(2):55-7.

2. Choi YS, Potter HG, Scher DM. A shearing osteochondral fracture of the humeral head following an anterior shoulder dislocation in a child. HSS J. 2005;1(1):100-2.

3. Schnetzke M, Bockmeyer J, Loew M, Studier-Fischer S, Grützner PA, Guehring T. Rate of avascular necrosis after fracture dislocations of the proximal humerus: Timing of surgery. Obere Extrem. 2018;13(4):273-8.

4. Hertel R, Fandridis E. (iii) Post-Traumatic Reconstruction for Sequelae of Fractures of the Proximal Humerus. Curr Orthop. 2007;21(6):422-31.

5. Zyto K, Kronberg M, Broström LA. Shoulder function after displaced fractures of the proximal humerus. J Shoulder Elbow Surg. 1995;4(5):331-6.