International Journal of Pediatric Surgery

ISSN: 2766-5577

Research Article

Plate Fixation for Irreducible Proximal Humeral Fractures in Children and Adolescents - A Single Center Case Series of Six Patients

*Florian Freislederer[1], Susanne Bensler[2], Thomas Specht[1], Olaf Magerkurth[2], Ruth Kubik[2] and Karim Eid[1]**

[1]*Department of Orthopaedics and Traumatology, Kantonsspital Baden, Switzerland*

[2]*Department of Radiology, Kantonsspital Baden, Switzerland*

Abstract

Background: Recommended treatment for severely displaced proximal humeral fractures in children is closed reduction and percutaneous fixation by K-wires or intramedullary nailing.

Methods: From January 2016 to January 2017, 6 of 21children/adolescents (range 8 to 16 years) with proximal humeral fractures were treated surgically for severe displacement. In all patients an unsuccessful attempt of closed reduction was made and open reduction was performed. The humeral head was fixed with a 3.5 mm T-plate without affecting the growth plate. Plate removal was done at a mean interval of 132 days after surgery. Two years after surgery clinical outcome was assessed by the Constant-Murley Score and Quick-Dash Score (including sport/music and work) and tendinous structures around the shoulder joint were evaluated with standardized sonographic examination.

Results: Dorsal displacement of the fracture was not reducible due to interposition of tendinous or osseous structures in all six cases. Intraoperatively, the interposed structures were the long biceps tendon in two, periosteal tissue in two, a bony fragment in one, and the long biceps tendon together with the conjoint tendon in one case. At mean follow-up of 26 months (range 22 months to 29 months) patients showed very good clinical results with excellent mean Constant-Murley score of 97.5 (range 91 to 100) and mean Quick-Dash Score (including sport/music and work) of 5.5 (range 0 to 20.8). X-ray follow-up 6 weeks after surgery demonstrated early consolidation and correct alignment in all patients. Sonographic evaluation at same follow up time point showed intact soft tissues around the shoulder joint in all patients.

Conclusion: If a proximal humeral fracture is not reducible by closed means, a tissue entrapment (most likely biceps tendon) should be considered. Treatment with open reduction and plate fixation yields very good clinical and radiological results and preserves interposed tissues as the biceps and conjoint tendon.

Keywords: Proximal humerus fracture; Proximal humeral fracture; Children; Plate fixation; Biceps tendon; ORIF humerus

Introduction

Proximal humeral fractures in children and adolescents are rare injuries, representing less than 5% of all pediatric fractures with a peek incidence between the age of 11 and 15 years [1-3]. These fractures can be physeal or metaphyseal. Metaphyseal fractures account for about 70% of the cases [4]. The specific muscle attachments of the rotator cuff proximally and the deltoid as well as the pectoralis major distally may cause severe displacement of the fracture fragments.

Usually the displacement occurs in a various direction with the proximal fragment moving medially and posteriorly, whereas the distal fragment moves anteriorly and in adduction (Figure 1).

Another explanation for the anterior displacement of the distal fragment might be the thinner and weaker anterior periosteum [5].

Neer and Horowitz [2] classified proximal humeral fractures in children in 4 grades according to the severity of displacement (I: <5 mm, II: <1/3 shaft width, III: <2/3 shaft width, IV: >2/3 shaft width).

Most fractures of the proximal humerus in the skeletally immature are not or only minimally displaced and can be treated conservatively [4,6,7].

Treatment for severely displaced proximal humeral fractures is still discussed controversially [3]. Displaced proximal humeral fractures (Neer and Horowitz ≥ III) in children are treated mainly by closed reduction and intramedullary nailing or percutaneous fixation by K-wires [2,8,9]. Because of high remodeling potential, moderate malalignement after closed reduction may be acceptable. In addition, as much as 80% of the longitudinal growth of the humerus takes place at the proximal physis and therefore mechanical interference with this area by means of open reduction has not been considered [10,11].

However, there are reports on open treatment which is eventually necessary due to insufficient alignment after closed reduction [4,12,13]. In our institution closed reduction and pin fixation were performed to address displaced pediatric proximal humerus fractures, but secondary displacement was observed. Tissue entrapment has been found to be responsible for failed closed reduction [12,14]. If tissue entrapment occurs, closed reduction of severely displaced fractures is often unsatisfactory and may cause damage to the

Citation: Freislederer F, Bensler S, Specht T, Magerkurth O, Kubik R, Eid K. Plate Fixation for Irreducible Proximal Humeral Fractures in Children and Adolescents - A Single Center Case Series of Six Patients. Int J Pediatr Surg. 2021;2(2):1016.

Publisher Name: Medtext Publications LLC

Manuscript compiled: Apr 26th, 2021

***Corresponding author:** Karim Eid, Department of Orthopaedics and Traumatology, Kantonsspital Baden (KSB), Im Ergel 1, 5404 Baden, Switzerland, E-mail: Karim.Eid@ksb.ch

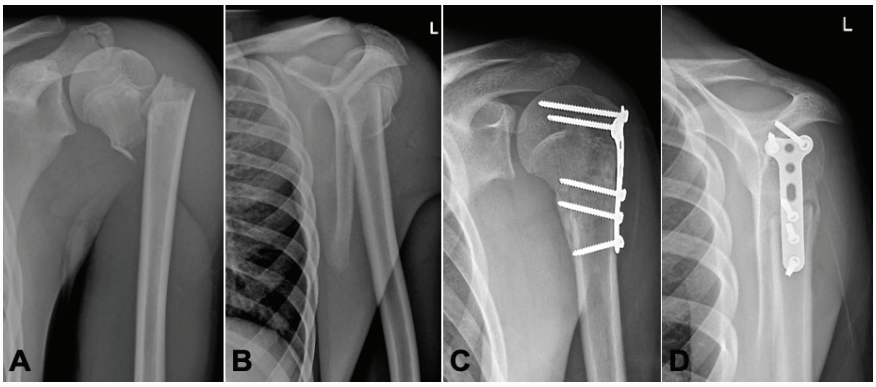

Figure 1: Radiographic Shoulder views, (Patient No. 4) (ap/Neer). A/B) dorsally displaced humeral head. C/D) 6 weeks after open reduction and plate fixation.

entrapped structures, mainly the biceps and the conjoint tendon.

Open reduction and plate fixation for pediatric proximal humeral fractures is rarely performed but has been described by Weber et al [15]. Forty years ago with very good outcome.

The aim of the study was to assess clinical and radiological results after open reduction, plate fixation and plate removal of irreducible displaced proximal humeral fractures in older children and to evaluate the functional integrity of the tissue - mainly the long head of the biceps tendon, interposed in the irreducible fracture.

Materials and Methods

Between January 2016 and January 2017, 21 skeletally immature patients with proximal humeral fractures were treated at the author's institute (level 1 trauma hospital). Six of these patients (29%) were treated operatively. All of these 6 patients were included in the study.

The inclusion criteria were: available standard x-rays in up and Neer view preoperatively and 6 weeks postoperatively, severely displaced humeral fracture (Neer and Horowitz III/IV), not reducible by closed means, open epiphyseal plate and metal removal performed. We prospectively enrolled these patients for a clinical and sonographic 2 years follow-up examination. Informed consent was obtained from the patient's or her/his legal representative. Approval by the Ethical committee Nordwestschweiz Nr. 2018-01405 was obtained.

Surgical Technique

In all of our patients an attempt of closed reduction was made prior to open reduction. All of the operative procedures were carried out under general anesthesia. The patients were positioned in beach chair position. An initial attempt of closed reduction was made in all patients. This was performed by gentle longitudinal traction with abduction and external rotation of the arm. An image intensifier was used to monitor reduction. If closed reduction failed, the surgeon proceeded to open reduction utilizing an anterior deltopectoral approach. Entrapped tissue or periost was gently freed. Once reduction was achieved, a 3.5 mm T-Plate was modelled on the anterolateral part of the proximal humerus and temporary K-wires were inserted through the plate holes to hold the reduction. Under image intensifier control attention was paid not to manipulate and not to cross the physeal plate. After confirming correct alignment, the K wires were then replaced with conventional cortical screws.

Surgical wounds were closed with absorbable Vicryl™ (Ethicon, Johnson-Johnson, New Brunswick, USA) sutures. Skin was closed using absorbable Monocryl™ (Ethicon, Johnson-Johnson, New Brunswick, USA) sutures.

Postoperatively a brace (type Gilchrist) was applied for 2 weeks. For the first 6 weeks range of motion was limited to 90º abduction and flexion. The first 2 weeks only passive mobilization out of the brace was allowed, followed by actively-assisted movements.

Clinical assessment

Outcome of the patients was assessed by study specific clinical and sonographic evaluation. The clinical examination was carried out by a single independent observer and the sonography by a single radiologist specifically trained in musculoskeletal imaging. The Constant-Murley Score and Quick-DASH (Disability of the Arm, Shoulder and Hand) score (including sport & music/work modules) were used for objective assessment [16,17]. The abduction strength was measured using a spring balance (Macro Line 80020, Fa. Pesola), which was attached distal on the forearm adiacent to the wrist with the method described and validated by Bankes et al. [18]. We performed this procedure also with the contra lateral arm to obtain the individual Constant score as described by Fialka et al. [16]. For interpretation, the results of the Constant-Murley Score were divided into four subscales: excellent 90 to 100; satisfactory 80 to 89; unsatisfactory 70 to 79; and failure 70.

In addition, a review of the medical records was carried. No patient had problems with the injured arm prior to surgery and had been operated previously on the same shoulder. Radiological evaluation was carried out using standard anteroposterior and Neer view of the shoulder joint. The follow-up radiographs were carried out 6 weeks postoperatively.

Ultrasound imaging

All patients were scanned in a sitting position with a relaxed arm hanging freely on the side. For the examination a GE Logiq E9 ultrasound system (GE Healthcare; Chicago, Illinois, USA) with a linear transducer with a bandwidth of 6 MHz to 15 MHz.

The subscapularis tendon, supraspinatus tendon and infraspinatus tendon were examined along its long- and short axis. The subscapularis tendon was examined with the arm externally rotated, the elbow fixed at the iliac crest. For the evaluation of the supraspinatus tendon the patient's arm was placed posteriorly, with the palmar side of the hand on the superior aspect of the iliac wing with the elbow flexed and directed posteriorly. To examine the infraspinatus tendon the arm was placed anterior with the hand on the opposite shoulder.

The long head of the biceps tendon was examined also along the

long- and short axis the arm placed in slight internal rotation. The integrity of the conjoint tendon was examined also in both planes with the arm placed in external rotation.

Results

There were five boys and one girl with a mean age of 14 years (8 to 16 years) at the time of injury, mostly accidents during physical activities which causing an isolated injury to the proximal humerus. All fractures were proximal metaphyseal fractures. Five patients had a Neer-Horowitz Grade III fracture and one had a Grade IV (Patient No. 4, see Table 1) completely displaced fracture of the proximal humerus (Figure 1). In all patients an attempt of closed reduction was performed, in five patients an immediate conversion to open surgery with open reduction and internal plate fixation was performed.

The first patient (No. 1, Table 1) from this series was initially treated with closed reduction and percutaneous pinning, due to secondary displacement an open reduction and internal fixation was necessary.

As the fracture site was explored, it was apparent that closed reduction was obstructed by the interposition of periosteum and other soft tissue. Tissue entrapment was intraoperatively observed in all of the six cases (the long biceps tendon in two cases (Patient No. 1 and 5), periosteal tissue in two cases (Patient No. 3 and 6), a bony fragment in one case (Patient No. 4), and both the long biceps tendon as well as the conjoint tendon in one case (Patient No. 4) (Figure 2).

Scheduled removal of the hardware was performed in all 6 patients. The implants were removed under general anesthesia as a day case procedure without difficulty at a mean time of 4.4 months after surgery (range 3 to 5.3 months).

The mean follow-up was 26 months (range 22 months to 29 months) after fracture fixation. Constant Murley Shoulder and Quick-DASH (including sport & music/work modules) scores are presented in Table 1. Constant-Murley score at final follow-up was 97.5 (range 91 to 100) and mean overall Quick-Dash Score (including sport and music/work) was 5.5 (range 0 to 20.8). Analyzing the subtypes of the Quick-Dash score we found a score of 3 for disability (range 0 to 10), 3.125 for sport and music (range 0 to 12.5) and 0 for work. All fractures showed advanced radiological consolidation at 6 weeks follow-up (Figure 1).

Sonographic examination of the soft tissue surrounding the shoulder joint showed no pathologic findings and no structural damage (Figure 3 and 4). No major complication was observed related to primary surgery or plate removal. None of the patients presented vascular or neurological complications. All patients showed a rather apparent skin scar, known to appear frequently in this location [4]. The 3 out of 6 patients reported the scar to be esthetically disturbing. Soft tissue irritation caused by the plate was observed in two patients. This resolved after all cases on plate removal. Asking the patients about their satisfaction regarding the outcome at 2 years follow-up, 5 patients were very satisfied and 1 was satisfied.

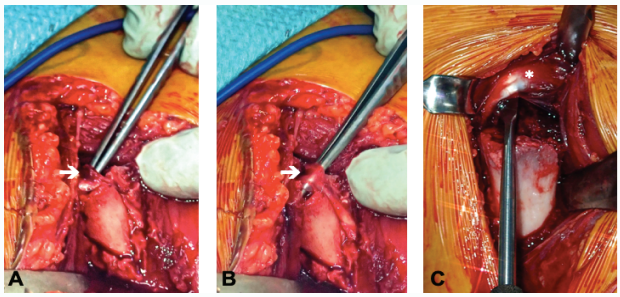

Figure 2: Intraoperative findings. A) Entrapment of the long biceps tendon (white arrow) in the fracture gap (Patient No. 1), B) freed long biceps tendon (Patient No. 1), C) freed conjoint tendons (white asterisk) (Patient No. 4).

Discussion

The first patient of this series was initially treated with closed reduction and percutaneous pinning. Due to secondary displacement a revision with open reduction and internal fixation was necessary due to biceps entrapment. Subsequently, we treated unreducible fractures by open reduction and internal plate fixation and found tissue entrapment to be present in all cases.

All fractures healed completely and functional scores were excellent at a 2-years follow-up with symmetrical shoulder movement (Figure 3). Scaring of the tissue was in all but one case pronounced and may be reflected by the slightly lower satisfaction scores than the maximum values achievable. Obstacle to reduction was, like stated in the literature, and in most cases the entrapped biceps tendon. In one case the trapped conjoint tendons inhibited reduction and in one other case periost tissue.

Figure 3: Range of motion after plate fixation of a proximal humerus fracture on the right site (Patient No. 6).

Table 1: Outcome with 2-year follow-up after open reduction, internal plate fixation and early (mean 4 months postoperative) plate removal,1secondary open reduction due to dislocation after closed reduction and percutaneous pinning.

Case No	Age	Sex	Reduction method	Constant Score	Quick-Dash Score				Subjective outcome
					Total	Disability	Sport/Music	Work	
1	12ys	M	Closed/Open[1]	98	0	0			Satisfied
2	14ys	F	Open	91	11.25	5	6.25	0	Very satisfied
3	14ys	M	Open	100	0	0	0		Very satisfied
4	14ys	M	Open	95	20.8	8.3	12.5	0	Very satisfied
5	16ys	M	Open	97	10	10			Very satisfied
6	8ys	M	Open	100	1	1	0		Very satisfied

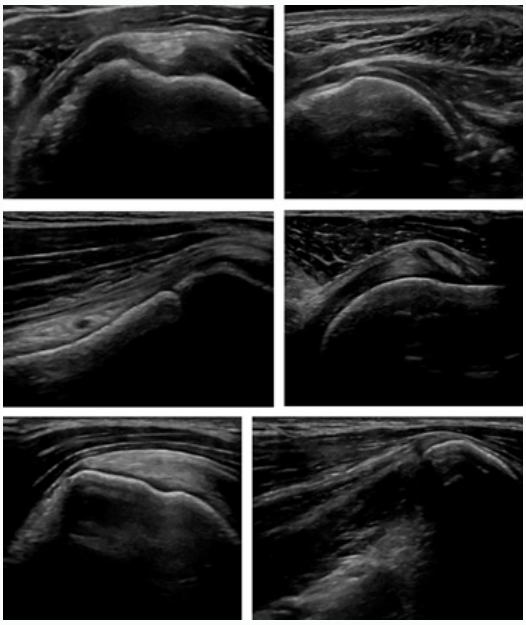

Figure 4: Sonographic scans of the soft tissue surrounding the shoulder joint.

In this series of six patients, we were able to demonstrate the functional and anatomical integrity of the entrapped tissues, namely the biceps and conjoint tendon. To the best of our knowledge, we are the first to verify and report after examination the full integrity of the interposed structures. It might well be questioned what would have been the fate of the interposed tissue if closed reduction had been accepted. The majority of outcome studies included few adolescents at the age of 15 years and older.

Dobbs et al. [11] examined this subgroup (older adolescents) and found worse outcome in none operatively treated patients in comparison to patients treated with surgery. The authors mention patients with irreducible fractures due to tissue entrapment which needed open reduction.

Nevertheless 23 of 28 patients in this study of Neer III and IV fractures were treated with closed reduction followed by pin or screw fixation [11]. They followed the guidelines of Beatty for acceptable angulation of the fragments (<70° (≤ 7 y), <60° (8-11 y), <45° (> 11y) [19].

Entrapment of the long head of the biceps tendon or periosteum has been mentioned earlier, but has not been stated as major cause of irreducibility [4,5,11]. Lucas et al. did not find entrapment of the tendon of the long head of the biceps in the fracture site in 4 patients, which were assessed by magnetic resonance imaging.

In contrast, Bahrs et al. [14] performed open reduction of Neer III and IV fractures in 17 of their 31 patients and found in 9 of these patients the biceps tendon entrapped in the fracture site. They concluded that a failed closed reduction should be interpreted as a possible soft tissue entrapment (most likely biceps tendon) and that these cases should be addressed with open reduction and removal of the entrapped structures.

Twelve patients were treated by Bahrs et al. [14] with K-wire or screw fixation, plate fixation was used only in 5 patients.

The use of a plate for internal fixation after open reduction has not been considered in the majority of operative descriptions because of the invasiveness.

As early as 42 years ago, Weber et al. described treatment of severely displaced or irreducible infratubercular proximal humerus fractures by open reduction and plate fixation without complications and symmetrical function of the shoulders.

Plating the reduced fracture fragments avoids injury to the epiphyseal plate if planned hardware removal is performed 3 to 6 months after initial surgery [15]. The treatment with a plate fixation without harming the epiphyseal plate followed by early plate removal yielded excellent clinical and early radiographic results in our patients.

Plate fixation allows for a very stable construct for fracture healing. The necessity to achieve fracture reduction to avoid important residual angular deformation might be of very high importance in adolescents (>12 years), where remaining remodeling is limited [20].

In contrast, any wire or elastic nail in metaphyseal and epiphyseal fractures will pass the epiphyseal plate and damage it to a certain degree. Excellent outcomes without limb shortening or axial deviation of the proximal humerus after K-wire or intramedullary nailing are reported [4,6,8]. Nevertheless a physeal arrest and progressive deformity can be a potential risk of any crossing stabilization [21]. Peterson [22] reported in their work on physeal injury about physeal fractures at three different sites (proximal humerus, distal humerus, distal femur) and recorded 100% premature closure in the three cases in which K-wire internal fixation had passed the physis. Intramedullary retrograde stabilization with ESIN has been recommended as standard fixation method for proximal humeral fractures in children and adolescents but this technique has some major drawbacks, such as nail penetration into the joint cavity, humeral head perforation, physeal damage due to multiple perforation and displacement of the proximal fragment by pushing with the ESIN tips [4]. Zivanovic et al. observed complications in 5 of 16 patients: 2 humeral head perforations, 10° of residual various deformation in 2 patients and difficulties in nail extraction in one patient. Similar complications were reported by other authors [8,23].

Our study has limitations. The number of patients treated is small and general treatment indications cannot be deducted. We do not have a control group in order to investigate about superiority of treatment. A part of the 6-weeks control there is no follow-up radiographic documentation of our patients to confirm long-term physeal integrity. A drawback of our proposed treatment is the requirement of a second surgery. We do agree with generally accepted age and deformity-based decision making [4,5,24]. But want to emphasize that tissue entrapment, which inhibits closed reduction, is very likely in Neer III and IV fractures and may be underestimated in the literature so far.

Conclusion

If a proximal humeral fracture is not reducible by closed means, a tissue entrapment (most likely biceps tendon and conjoined tendon) has to be considered as obstacle to the reduction. Open reduction and plate fixation not only yield excellent clinical results, but warrants functional and anatomical integrity of the entrapped tendons.

References

1. Landin L. Epidemiology of children's fractures. J Pediatr Orthop B. 1997;6(2):79-83.
2. Neer CS, Horwitz BS. Fractures of the proximal humeral epiphyseal plate. Clin Orthop Relat Res. 1965;41:24-31.
3. Shrader MW. Proximal humerus and humeral shaft fractures in children. Hand Clin.

2007;23(4):431-5.

4. Lefevre Y, Journeau P, Angelliaume A, Bouty A, Dobremez E. Proximal humerus fractures in children and adolescents. Orthop Traumatol Surg Res. 2014;100(1 Suppl 1):S149-56.

5. Bishop JY, Flatow EL. Pediatric Shoulder Trauma. Clin Orthop Relat Res. 2005;432:41-8.

6. Rajan RA, Hawkins KJ, Metcalfe J, Konstantoulakis C, Jones S, Fernandes J. Elastic stable intramedullary nailing for displaced proximal humeral fractures in older children. J Child Orthop. 2008;2(1):15-9.

7. Kinderchirurgie DGf. Leilinien der deutschen Gesellschaft für Kinderchirurgie - Proximale Humerusfraktur beim Kind. AWMF. 2016:1-5.

8. Fernandez FF, Eberhardt O, Langendorfer M, Wirth T. Treatment of severely displaced proximal humeral fractures in children with retrograde elastic stable intramedullary nailing. Injury. 2008;39(12):1453-9.

9. Chee Y, Agorastides I, Garg N, Bass A, Bruce C. Treatment of severely displaced proximal humeral fractures in children with elastic stable intramedullary nailing. J Pediatr Orthop B. 2006;15(1):45-50.

10. Dameron TB, Reibel DB. Fractures Involving the Proximal Humeral Epiphyseal Plate. J Bone Joint Surg Am. 1969;51(2):289-97.

11. Dobbs MB, Luhmann SL, Gordon JE, Strecker WB, Schoenecker PL. Severely Displaced Proximal Humeral Epiphyseal Fractures. J Pediatr Orthop. 2003;23(2):208-15.

12. Pandya NK, Behrends D, Hosalkar HS. Open reduction of proximal humerus fractures in the adolescent population. J Child Orthop. 2012;6(2):111-8.

13. Schwendenwein E, Hajdu S, Gaebler C, Stengg K, Vecsei V. Displaced fractures of the proximal humerus in children require open/closed reduction and internal fixation. Eur J Pediatr Surg. 2004;14(1):51-5.

14. Bahrs C, Zipplies S, Ochs BG, Rether J, Oehm J, Eingartner, et al. Proximal Humeral Fractures in Cildren and Adolescents. J Pediatr Orthop. 2009;29(3):238-42.

15. Weber BG, Burnner C, Freuler F. Die Frakturenbehandlung bei Kindern und Jugendlichen. Germany: Springer; 1978.

16. Fialka C, Oberleitner G, Stampfl P, Brannath W, Hexel M, Vecsei V. Modification of the Constant-Murley shoulder score-introduction of the individual relative Constant score Individual shoulder assessment. Injury. 2005;36(10):1159-65.

17. Quatman-Yates CC, Gupta R, Paterno MV, Schmitt LC, Quatman CF, Ittenbach RF. Internal Consistency and Validity of the QuickDASH Instrument for Upper Extremity Injuries in Older Children. J Pediatr Orthop. 2013;33(8):838-42.

18. Bankes MJK, Crossman E, Emery RJ. A standard method of shoulder strength measurement for the Constant score with a spring balance. J Shoulder Elbow Surg. 1998;7(2):116-21.

19. Beaty JH. Fractures of the proximal humerus and shaft in children. Instr Course Lect. 1992;41:369-72.

20. Binder H, Schurz M, Aldrian S, Fialka C, Vecsei V. Physeal injuries of the proximal humerus: long-term results in seventy two patients. Int Orthop. 2011;35(10):1497-502.

21. Boyden EM, Peterson HA. Partial premature closure of distal radial physis associated with Kirschner wire fixation. Orthopedics. 1991;14(5):585-8.

22. Peterson HA. Physeal Injury Other Than Fracture. Germany: Springer; 2012.

23. Kelly DM. Flexible Intramedullary Nailing of Pediatric Humeral Fractures: Indications, Techniques, and Tips. J Pediatr Orthop. 2016;36 Suppl 1:S49-55.

24. Pahlavan S, Baldwin KD, Pandya NK, Namdari S, Hosalkar H. Proximal humerus fractures in the pediatric population: a systematic review. J Child Orthop. 2011;5(3):187-94.