American Journal of Surgery Case Reports

Short Communication

Pseudomyxoma Peritonei: A Case Report and Review

El Hachami Fatim Zohra, Imami Y, Berrehili H, Guezri A, Benchrifi Y, Benhessou M, Ennachit M and Elkerroumi M*

Department of Obstetrics and Gynaecology, CHU Ibn Rochd Casablanca, Morocco

Abstract

Pseudomyxoma peritonei is a clinical entity characterized by gelatinous ascites associated with mucinous deposits disseminated over the peritoneum and potentially invading abdominal organs. It is considered a tumoral process linked in the vast majority of cases to a mucinous appendicular tumor or one of ovarian origin. Pseudomyxoma can benefit from a therapeutic approach combining complete cytoreduction surgery and chemotherapy.

The aim of this work is to analyze the epidemiological characteristics, clinical, evolutionary and therapeutic outcomes, through a case study of histologically confirmed peritoneal pseudomyxoma managed at the Mohammed VI center service of the University Hospital of Casablanca.

Keywords: Pseudomyxoma peritonei; Appendix; Ovary; Intraperitoneal chemotherapy

Identity

The patient was 54 years old, postmenopausal for 3 years, with a history of a left cystectomy performed in 2019 in a peripheral hospital for a calcified cyst with no sign of malignancy on the pathological result. Two years after this operation, she consulted for abdominal distention associated with chronic pelvic pain in a state of conservation of general condition.

Abdomino-pelvic MRI revealed abundant ascites, more marked in the pelvis, with several peritoneal nodules, creating a mass measuring 52 mm × 45 mm, which was responsible for scalloping on the lower border of the right liver and on the body of the uterus. The rest of the organs were without abnormalities, notably the appendix (Figure 1).

Tumor markers were positive, notably CA 125 at 90.42 U/ml. A diagnostic laparoscopy was performed, revealing a gelatinous ascites of moderate abundance covering the peritoneum, stomach and omentum, which was aspirated, and the presence of a mass adherent to the uterus and right adnexa, which was biopsied (Figure 2). The pathological result showed a grade 3 pseudomyxoma peritonei. Patient was referred to the oncology department for additional adjuvant treatment.

Discussion

Pseudomyxoma peritonei is a pathology first described by Karl F. Rokitansky in 1842, then reported in 1884 by Werth [1]. It is a clinico-radiological condition defined by localized or diffuse accumulation of mucin in the abdominal and/or pelvic cavity.

It belongs to the group of rare diseases of the peritoneum, with an estimated incidence of 1 to 2 cases per million inhabitants per year [2]. Its development is generally associated with the rupture of appendicular mucinous tumors and other mucinous tumors of the gastrointestinal tract or ovaries. Pseudomyxoma peritonei is generally divided into three types: low-grade, high-grade and high-grade with ring cells. The stage of the disease is determined by the peritoneal cancer index [3]. Thanks to immunohistochemistry and molecular engineering, it is now accepted that peritoneal pseudomyxoma is mainly of appendicular origin, more rarely the ovary, notably the teratomatous lesion [2].

There is much debate as to whether ovarian tumours are secondary to appendicular tumours or independent primary ovarian tumours [4]. Immunohistochemical studies of the CK7, CK20 and HAM-56 antigens have shown that the origin of pseudomyxoma is most often appendicular [5].

In addition, several studies of *K-ras* gene mutations and loss of alleles on chromosomes 18q, 17p, 5q and 6q have demonstrated the presence of these abnormalities in peritoneal pseudomyxoma, which are absent in ovarian tumour pathology [6].

The only primary ovarian tumours capable of genuine pseudomyxoma to us dissemination are mature cystic teratomas, probably due to the existence of a gastrointestinal contingent in these embryonic tumours [1]. Three percent (3%) to 8% of cases are associated with peritoneal pseudomyxoma and mature ovarian cystic teratomas [2,7].

The clinical course is variable, non-specific and may be asymptomatic or with digestive symptoms, notably the presence of chronic pelvic pain, progressive abdominal distension or obstructive symptoms [8]. Radiologically, ultrasonography may reveal intra-peritoneal effusion, small cystic lesions, mucinous implants, or a hepatic and splenic imprint forming a scalloping pattern.

CT is the examination of choice, revealing abundant hypodense peritoneal effusion, often compartmentalized and dense due to mucin deposition. Pathognomonic of pseudomyxoma is the "sca1lopping" or indentation of these viscera due to mucinous compression and fibrosis of the organs [8].

CT scans can also be used to search for primary tumors: appendicular, ovarian, colonic mucocele, pancreatic cystadenocarcinoma or urachal cystadenocarcinoma.

Serum levels of the markers ACE, CA19-9 and CA125 can

Citation: El Hachami Fatim Zohra, Imami Y, Berrehili H, Guezri A, Benchrifi Y, Benhessou M. Pseudomyxoma Peritonei: A Case Report and Review of the Literature. Am J Surg Case Rep. 2024;5(2):1118.

Copyright: © 2024 Zohra EL Hachami

Publisher Name: Medtext Publications LLC

Manuscript compiled: Feb 26th, 2024

***Corresponding author:** Zohra EL Hachami, Department of Obstetrics and Gynaecology, CHU Ibn Rochd Casablanca, Morocco

© 2024 - Medtext Publications. All Rights Reserved.

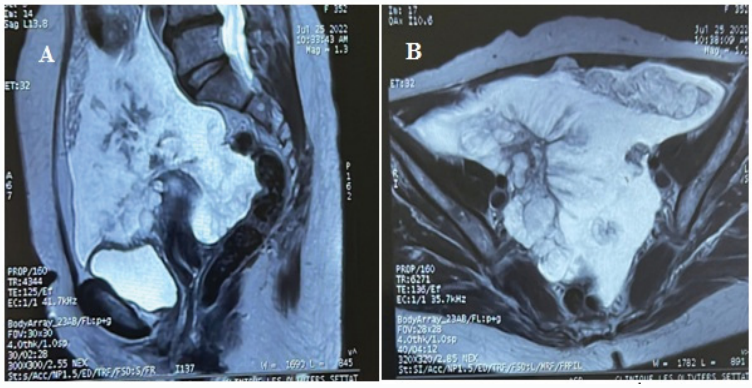

Figure 1: Right latero-uterine mass with abundant ascites and diffuse peritoneal carcinosis (A) Sagittal section; (B) Axial section.

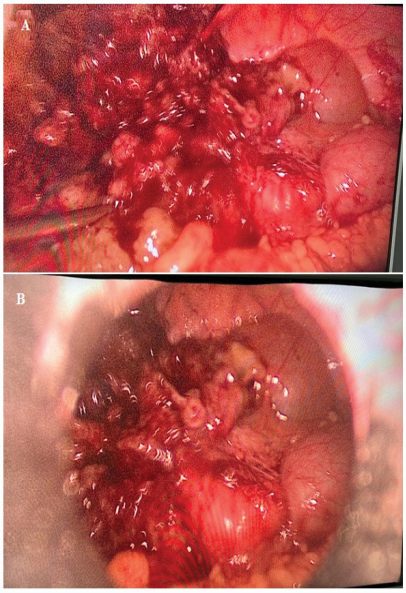

Figure 2: (A,B) Adherent mass in uterus and right adnexa.

therefore be used to assess the biological aggressiveness of PMP. Their increase correlates with the extent of carcinosis and is a prognostic factor.

Diagnosis is based on the presence of mucin in the peritoneal cavity, accompanied by cystic epithelial implants on the peritoneal surfaces. These lesions vary in size from a few mm to several centimetres. Confirmation is provided by histological analysis of peritoneal samples [9]. The morphological appearance (grade) and extent (stage) of the disease are prognostic factors.

- The basic histological criteria for grading PMP are as follows:
- Cellularity of mucinous deposits: hypo-or hypercellularity
- Architectural abnormalities: low or high grade
- Cytological abnormalities: low or high grade,
- Kitten-ring cells: presence or absence,
- Organ invasion: presence or absence. If present, type of invasion: expansive (so-called "pushing") or infiltrative.

Various histological classifications have been proposed, the latest of which is WHO 2019 (5th edition) (Figure 3).

The treatment of pseudomyxoma peritonei is not yet standardized. The gold standard remains cytoreduction surgery followed by hyperthermic intraperitoneal chemotherapy [11].

This therapeutic approach results in 5- and 10-year overall survival rates of 90% and 85% respectively [11].

Resection is considered complete if no mass greater than 2.5 mm remains [12].

When complete cytoreduction surgery is not feasible, due to extensive involvement, palliative debulking surgery is performed, the aim of which is to remove as much gelatin and tumour formations as possible.

Intraperitoneal chemotherapy (CHIP) or Hyperthermia Intraperitoneal Chemotherapy (HIPEC) aims to eradicate residual microscopic disease [13].

Adjuvant chemotherapy with 6 cycles of paclitaxel and carboplatin has been described in some cases, but no study has demonstrated the benefit of this chemotherapy [1,7].

As for recurrence, no intraperitoneal recurrence has been reported for pseudomyxoma peritonei of ovarian origin [10].

Symptomatic recurrences may present as intestinal obstruction, abdominal pain or abdominal distension, which are treated again with debulking surgery [14,15].

The prognosis of peritoneal pseudomyxoma depends on complete cytoreduction surgery and the degree of malignancy of the tumour cells.

Follow-up should take place 3 months after surgery and every 6 months, using CT scans and tumour marker assays to monitor recurrence [2].

Conclusion

Pseudomyxoma peritonei is a rare entity, most often of appendicular origin but which may also be of ovarian origin, with vague and non-specific symptoms. Diagnosis is usually made by imaging and confirmed by histology. Treatment is based on complete cytoreduction surgery combined with hyperthermic chemotherapy. Prognosis depends on histological grade, as well as rapid diagnosis and management.

References

1. Saluja M, Kenwright DN, Keating JP. Pseudomyxoma Peritonei arising from a mucinous borderline ovarian tumour: Case report and literature review. Aust N Z J

© 2024 - Medtext Publications. All Rights Reserved.

- Grade 1 : dépôts mucineux peu cellulaires, atypies de bas grade, absence d'invasion de type infiltratif (destructrice) ;
- Grade 2 : dépôts mucineux hypercellulaires, atypies de haut grade, invasion de type infiltratif (destructrice), se caractérisant par des glandes anguleuses, dans un stroma desmoplasique ou des amas tumoraux au sein de flaques de mucine de petite taille ;
- Grade 3 : dépôts mucineux avec présence de cellules en bague à chaton (*Digestive System Tumours WHO Classification of Tumours* 2019).

Figure 3: WHO histological classification 2019 (5th edition).

Obstet Gynaecol. 2010;50(4):399-403.

2. Mohtaram A, Boutayeb S, El Youbi MBA, Sghiri T, Aaribi I, Kettani F, et al. [Peritoneal pseudomyxoma arising from an ovarian teratoma associated with Bordeline mucinous tumor: report of a case and review of the literature]. Pan Afr Med J. 2013;14:156.

3. Sugarbaker PH, Ronnett BM, Archer A, Averbach AM, Bland R, Chang D, et al. Pseudomyxoma péritonéi Syndrome. Adv Surg. 1996;30:233-80.

4. O'Connell JT, Tomlinson JS, Roberts AA, McGonigle KF, Barsky SH, et al. Pseudomyxoma peritonei is a disease of MUC2-expressing goblet cells. Am J Pathol. 2002;161(2):551-64.

5. Ronnett BM, Shmooker BPM, Diennerwest M, Sugarbaker PH, Kurman RJ. Immunohistochemical evidence supporting the appendiceal origin of pseudomyxoma in women. Int J Gynecol Pathol. 1997;16(1):1-9.

6. Szych C, Staebler A, Connolly DC, Wu R, Cho KR, Ronnett BM. Molecular genetic evidence supporting the clonality and appendiceal origin of pseudomyxoma peritonei in women. Am J Pathol. 1999;154(6):1849-55.

7. Hwang JH, So KA, Modi G, Lee JK, Lee NW, Lee KW, et al. Borderline-like mucinous tumor arising in mature cystic teratoma of the ovary associated with pseudomyxoma peritonei. Int J Gynecol Pathol. 2009;28(4):376-80.

8. Dartigues P, Isaac S, Villeneuve L, Glehen O, Capovilla M, Chevallier A. Peritoneal pseudomyxoma: An overview emphasizing pathological assessment and therapeutic strategies. Annales de Pathologie. 2014;34(1):14-25.

9. Chua TC, Moran BJ, Sugarbaker PH, Levine EA, Glehen O, Gilly FN, et al. Early- and Long-Term Outcome Data of Patients with Pseudomyxoma Peritonei from Appendiceal Origin Treated by a Strategy of Cytoreductive Surgery and Hyperthermic Intraperitoneal Chemotherapy. J Clin Oncol. 2012;30(20):2449-56.

10. Lee KR, Scully RE. Mucinous tumors of the ovary: a clinicopathologic study of 196 borderline tumors (of intestinal type) and carcinomas, including an evaluation of 11 cases with 'pseudomyxoma peritonei'. Am J Surg Pathol. 2000;24(11):1447-64.

11. Hettinga JV, Konings AW, Kampinga HH. Reduction of cellular cisplatin resistance by hyperthermia--a review. Int J Hyperthermia. 1997;13(5):439-57.

12. Yu B, Raj MS. Pseudomyxoma peritonei. StatPearls; 2023.

13. Eveno C, Dagois S, Guillot E, Gornet JM, Pocard M. Traitement des carcinoses péritonéales par chirurgie et chimiothérapieintrapéritonéaleperopératoire (CHIP): des nouveautésmaisaussi des indications validées. Bulletin du Cancer. 2008;95(1):141-5.

14. Bartoška P, Antoš F, Vitek P, Marx J, Kopic J, Holečková P. Pseudomyxoma peritonei. Klin Onkol. 2019;32(5):329-32.

15. Bouia M, Hammounea N, Sliouia B, Bellasria S, Haouaneb MA, Azamib MA, et al. Pseudomyxomepéritonéal: imageried'une cause rare d'ascitegélatineuse à travers deux cas. Service de Radiologie, Hopital Militaire Avicenne Marrakech, Maroc. b. Service d'anatomo-pathologie, Hopital Militaire Avicenne Marrakech, Maroc.

© 2024 - Medtext Publications. All Rights Reserved.