American Journal of Surgery Case Reports

Short Communication

Pyosalpinx after Hysterectomy: Report of a Case

Djelti Sihem and Benmoumen Mohammed Yacine*

Department of Obstetrics and Gynecology, EHS Nouar Fadela, Algeria

Abstract

Pelvic inflammatory disease is an infection of the upper genital tract, including the uterus, ovaries, uterine tubes, and peritoneum.

Tubo-ovarian abscess and pyosalpinx are complications associated with pelvic inflammatory disease, occur in 16% of all pelvic inflammatory disease and are usually encountered in sexually active women. The purpose of this work is to diagnose pelvic inflammatory disease with adequate therapeutic management due to potential long-term complications.

We report here the case of a 44-year-old woman who is nulliparous (10 years of sub fertility of female origin), presenting with pyosalpinx after an interexal hysterectomy.

Keywords: Hysterectomy; Pyosalpinx; Inflammatory disease

Introduction

Pyosalpinx is a complication of salpingitis, associated with a suppurative cystic dilatation of the fallopian tube or in clearer terms, it is an abscess formed in the lumen of the tube [1]; pyosalpinx is in certain cases unilateral but often bilateral, and is associated with one or more elements of upper genital infection such as: endometritis, Tubo-ovarian abscess, Douglas-fir sac abscess, pelvic peritonitis, appendicitis by contact with the right appendix, abscess of the parieto-colic gutters, perihepatitis (Fitz-hugh-Curtis syndrome) which manifests itself by the presence of multiple perihepatic adhesions in the form of cords of violin and which we see in certain upper genital infections caused by chlamydia trachomatis and gonococci [1].

Pyosalpinx is the complication of salpingitis or acute adnexitis which has not been treated quickly but it can also be the infectious complication of hydrosalpinsx.

Pre-existing containing a sterile liquid but becoming infected by bacterial contamination it transforms into an intratubal abscess [1].

Pyosalpinx requires adequate rapid surgical treatment [1]

Pyosalpinx is a serious sequela of chronic pelvic inflammatory disease, in which the fallopian tubes fill with pus; it often affects sexually active women, and is rarely seen after hysterectomy. This pathology is generally unilateral and rarely bilateral; causing intense abdominal pain can have significant consequences on a woman's fertility and requires emergency treatment.

The course of such infection can lead to various long-term reproductive and gynecological complications; early diagnosis and treatment is the key to reducing lifelong complications.

Citation: Sihem D, Yacine BM. Pyosalpinx after Hysterectomy: Report of a Case. Am J Surg Case Rep. 2024;5(2):1115.

Publisher Name: Medtext Publications LLC

Manuscript compiled: Jan 31st, 2024

***Corresponding author:** Djelti Sihem, Department of Obstetrics and Gynecology, EHS Nouar Fadela, Oran, Algeria

The wide range of presenting symptoms of PID makes it easily missed; a pupil suspension index should be maintained for early diagnosis.

Observation

We report the case of a N.M woman 30 old years, nulliparous (primary subfertility of 10 years of female origin), with a history of surgical myomectomy (submucosal myoma) in 2015 who was complicated by uterine synechia treated with hysteroscopy in 2016.

In 2021 the patient presented with a picture of upper genital infection (fever, leukorrhea, metrorrhagia, pelvic pain) admitted to the operating room as part of the emergency for an acute surgical abdomen, she underwent an inter adnexal hysterectomy with flattening of the left tubal abscesses, and given the persistence of the symptoms, the patient should be consulted in our department [2,3].

The clinical examination

General condition remains, with BP 11/07, diffuse abdominal pain, slight pelvic sensitivity on palpation

Speculum: unremarkable vaginal stump. Vaginal touch combined with abdominal palp: sensation of a poorly limited painful formation.

An ultrasound came back: poorly limited latero-uterine mass measuring 07 cm A biological assessment: high CRP with hyperleukocytosis, the rest of the assessment correct. A magnetic resonance imaging made objectifying (Figure 1 and 2): a median pelvic tubulated fluid structure, measuring 70 mm anteroposterior axis 75 mm wide and extending over 90 mm, appearance favoring a left pyosalpinx, on the right a small endometrioma, the two ovaries and the fluid structure adhering to the cervical stump, in conclusion, a diffuse inflammatory change in the pelvis in which there is a left Tubo-ovarian complex associated with a right oophoritis.

The patient benefited from an exploratory laparotomy: we found an adherent pelvis with a mass of approximately 10 cm going from the left appendix extending to the cervical stump, the right annex an endometrioma with a small pyosalpinx, an ovarian kissing, adhesion between the omentum and the two ovaries, we proceed to an adhesiolyse then bilateral salpingectomy leaving the ovaries in place. The surgical part was addressed to the anatomopathological study (Figure 3 and 4).

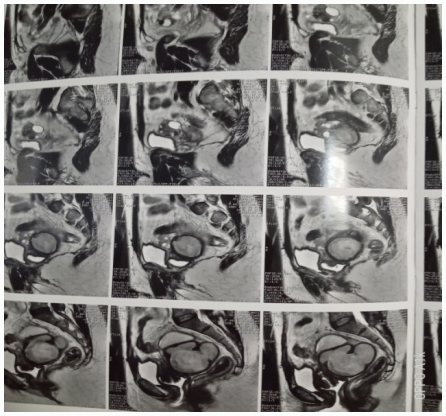

Figure 1: Scan pelvic image of the pyosalpinx.

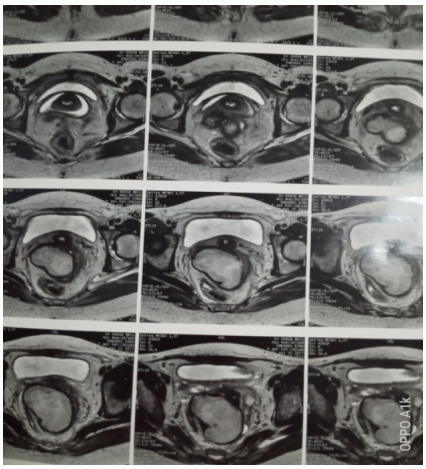

Figure 2: Scan pelvic image of the pyosalpinx.

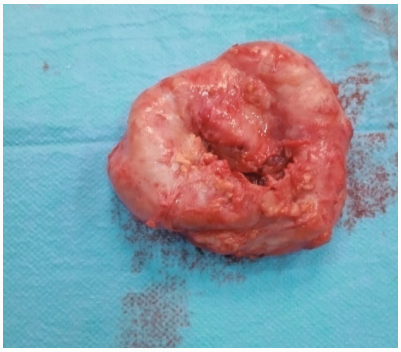

Figure 3: la pièce opératoire.

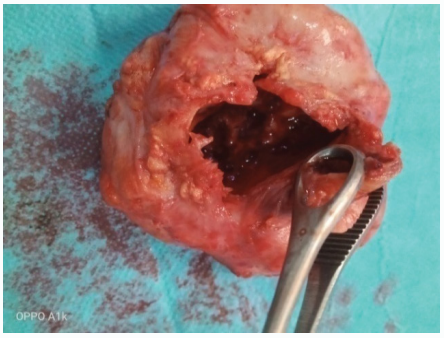

Figure 4: The internal cavity of the pyosalpinx.

Discussion

Salpingitis is an upper genital infection which results in the vast majority of cases from bacterial contamination via the ascending route, with contiguity or hematogenous infection being exceptional.

Chronic inflammation represents *neisseria gonorrhea* and *chlamydia trachomatis*, while bacteroides, *streptococcus*, *E. coli* and other gram-negative enteric organisms are commonly found in cases of Tubo-ovarian abscess or pyosalpinx [4].

The typical isolated organisms in this pathology are poorly known. The clinical picture is silent leading to a delay in diagnosis, in the absence of adequate care, the evolution can be progressive towards irreversible tubal sequelae [1], The treatment which is based on antibiotic therapy must often be complete in the forms complicated by early and atraumatic surgical treatment [2].

The diagnosis remains difficult because the clinical symptoms in upper genital infection (pelvic inflammatory disease), the Anglo-Saxons, grouping together endometritis and salpingitis, are most of the time not very specific [2], the evolution is unpredictable and can lead to acute complications such as pelvic abscesses most frequently represented by pyosalpinx, ovarian abscess, phlegmon of the broad ligament is exceptional, pelviperitonitis, there are two main types of causes: sexually transmitted infections chlamydia, gonococci, mycoplasma, and peritoneal infection in general following appendicitis [2] under treatment the risk of pelvic sequelae induced by immunological inflammatory phenomena persists which can be the cause of sterility, ectopic pregnancy, chronic pelvic pain, the transition to chronicity can occur particularly in the event of inadequate or insufficient treatment, Frequency of chronic salpingitis is unknown.

At this stage the symptoms are generally absent, the diagnosis is generally made by laparoscopy as part of the infertility assessment, the search for chlamydia trachomatis is generally negative, the differential diagnosis is essentially made with an acute surgical abdomen (torsion of the appendix, appendicitis, peritonitis, intestinal obstruction), chronic pelvic pain due to adhesions.

Our patient was a 44-year-old woman who presented with chronic pelvic pain, with a gynecological history of unexplained primary subfertility of 10 years, with a surgical history of a myomectomy without an operating protocol which was complicated by uterine synechia requiring treatment by hysteroscopy, then pelvic thrombophlebitis or the transition to chronicity the patient presented a surgical table to the general surgery department where she was admitted to the operating room, for the exploration of a left tubal abscess, the procedure performed was a drainage of the abscess and an interadnexal hysterectomy, and given the persistence of The symptoms pushed the patient to see another doctor, hence her referral.

Conclusion

To avoid pyosalpinx it is necessary to protect oneself against sexually transmitted infections [2], the control strategies for chronic inflammatory diseases of the pelvis, which currently concern the detection of chlamydia must be reviewed so that they can prevent all cases of PID [5], early diagnosis and treatment can reduce life complications. The wide range of presenting symptoms of PID makes

it easily missed, a high index of suspicion should be maintained for early diagnosis [6]; In the absence of treatment, pelvic inflammatory disease can lead to certain complications such as the formation of scar tissue both outside and inside the fallopian tubes which can lead to blockage of the tubes; geu, infertility, chronic pelvic pain [7].

References

1. Abbara A. pyosalpinx mise a jour. 2014.
2. Giorgetta J. journal des femmes mise a jour. 2017
3. Ze Khan, JH Rizvi. Maladies inflammatoire. 2006.
4. Hurni Y, Bonollo M, Ferrero L, Taraschi G, Canonica C, Lozano SVR. Pyosalpinx complicating chronic hydrosalpinx in a 50-year old virgo woman: a case report. BMC Womens Health. 2018;18(1):90.
5. Simms I, Stephenson JM, Mallinson H, Peeling RW, Thomas K, Gokhale R, et al. Risk factors associated with pelvic inflammatory disease. Sex Transm Infect. 2006;82(6):452-7.
6. Maraqa T, Mohamed M, Coffey D, Sachwani-Daswani GR, Alvarez C, Mercer L. Bilateral recurrent pyosalpinx in a sexually inactive 12-year-old girl secondary to rare variant of Mullerian duct anomaly. BMJ Case Rep. 2017;2017:bcr2016218924.
7. Maladies inflammatoire pelvienne. Sexually Transmitted Infections Treatment Guidelines, 2021. CDC(centers for diseace control and prevention). 2021.