American Journal of Surgery Case Reports

Case Report

Short-Term Effects and Withdrawal of Sacral Neuromodulation in Fowler Syndrome: A Case Report

Cláudia N Fernandes[1], Luís Vale[1,2], Carlos Ferreira[1], João Silva[1,2], Carlos Silva[1,2] and Tiago Antunes-Lopes[1,2]*

[1]Department of Urology, Hospital and University Centre of São João, Portugal

[2]Department of Medicine, Porto University, Portugal

Abstract

Fowler Syndrome (FS) is a rare condition first described in 1950 as a sphincter abnormality, causing voiding dysfunction in women. A large spectrum of treatments had been tried but only Sacral Nerve Stimulation (SNS) has proven to be efficient.

In this work, we present a 22-year-old woman with a history of progressive voiding symptoms presented with recurrent painless urinary retention episodes. She was referred to a tertiary centre for a study evaluation of urinary retention. Any trigger situations were involved and, except for repetitive cystitis, no other pathological issues were listed. Physical examination and neurologic evaluations were on the normal pattern. The neuroaxis study had no relevant alterations.

Urodynamic studies documented a decreased bladder sensation during the filling phase, good bladder compliance with higher bladder capacity. During the voiding phase, voiding hesitancy was reported. Detrusor overactivity and detrusor sphincter dyssynergia were excluded. Post-voiding residual volume was higher than 300 mL. Surface electromyography was also performed.

After the exclusion of urological, gynecological, and neurological abnormalities, FS was considered to be the most compatible diagnosis. Conservative treatment with a trial of 40 mg daily tamsulosin had failed and after one year of Clean Intermittent Catheterization (CIC) the patient was submitted to Sacral Neuromodulation (SNM) with excellent results- spontaneous voiding during the first hours after the surgical procedure with complete bladder sensation restored. SNM effects are maintained after two weeks of SNM withdrawal.

Keywords: Fowler's syndrome; Sacral neuromodulation; Chronic urinary retention

Introduction

Urinary retention is a disturb affecting mostly men, with an estimated incidence of 7 cases per 100000, per year in women. Some epidemiological studies estimate that affected young women range from 3 cases per 100000 per year to 0.3%, after the exclusion of other causes [1,2].

A large spectrum of treatments had been tried but only Sacral Nerve Stimulation (SNS) has proven to be efficient for Fowler's syndrome [1] which has been demonstrated to restore voiding [3,4].

The main mechanisms of urinary retention are divided into two groups, bladder outlet obstruction, and detrusor underactivity [4,5]. The factors can be classified as anatomical, neurogenic, myogenic or pharmacotherapy side effects, and if no organic causes can be identified, the etiology is classified as either infective or functional. Generally, the cause can be identified during urological evaluation, such as an urethrocele, a urethral diverticulum, a urethral stricture, and sometimes a consequence of surgery for stress urinary incontinence. When detrusor underactivity is suspected, pharmacotherapy's adverse effect must be excluded as it usually is transient and reversible [4,6].

Persistent urinary retention in young women without an identifiable organic cause is rare and a challenging condition. In the past, these women were labeled as suffering from psychological disturbance. However, Fowler and their partners described it as a characteristic failure of urethral relaxation. They performed electromyographic studies of the External Urethral Sphincter (EUS) in female patients with unexplained urinary retention and found a specific wave pattern [4,7,8]. They called the disturbed Fowler's Syndrome (FS).

Case Presentation

A 20-year-old woman, with no known history of hereditary genetic disorders, familiar genitourinary disturbs, and any relevant past health issues, except for repetitive cystitis, presented with progressive voiding symptoms and experienced complete painless urinary retention episode. The situation occurred twice when she had 21-year-old. Following the retention episode, which had been ongoing for four months, the patient experienced voiding Low Urinary Tract Symptoms (LUTS), including straining, loss of urination desire, incomplete bladder empty sensation, and voiding hesitation? There were no reported neurologic symptoms (motor and sensory symptoms, balance, and visual changes), surgical procedures, acute illnesses, or deliveries.

The patient was referred to a tertiary center for evaluation, started CIC, and underwent a urogynecological examination that revealed no anomalies, including non-vesicovaginal atrophy, no prolapse, and negative stress test results. Pelvic diaphragmatic muscles and external anal sphincter exhibited normal tonicity.

Citation: Fernandes CN, Vale L, Ferreira C, Silva J, Silva C, Antunes-Lopes T. Short-Term Effects and Withdrawal of Sacral Neuromodulation in Fowler Syndrome: A Case Report. Am J Surg Case Rep. 2023;4(11):1102.

Publisher Name: Medtext Publications LLC

Manuscript compiled: Nov 03rd, 2023

***Corresponding author:** Cláudia Nogueira Fernandes, Department of urology, Hospital and University Centre of São João, Alameda Prof. Hernâni Monteiro, Porto, 4200-319, Portugal, Tel: +351-919455092

Neurologic symptoms were denied (motor and sensitive symptoms, balance, visual changes). She was not submitted to any surgical procedures previously, no acute illness stated and she never had a delivery. The neurological exam revealed preserved superior nervous functions, no cranial nerve paresis, no motor deficits, normal and symmetrical osteotendinous reflexes, negative Romberg test results, no dysmetria, and preserved sensibilities. A neuroaxis study excluded neurologic disease, with cerebral and medular magnetic resonance not showing any relevant anomalies. Reno-vesical and abdominal ultrasound revealed no unusual findings. Uretrocystoscopy demonstrated a normal urethra, without stenosis or diverticula, and a normal bladder wall.

Urodynamic studies documented decreased bladder sensation (with first desire at 490 mL) during the filling phase, satisfactory bladder compliance, and higher bladder capacity (710 mL). Detrusor overactivity was not observed, and during the voiding phase, detrusor sphincter dyssynergia was excluded, with PVR at 498 mL. Surface electromyography shows an increased activity at the end of micturition phases. The urodynamic pressure-flow studies along with electromyographic findings are shown on Figures 1 and 2. The patient started pharmacologic treatment with tamsulosin, which proved ineffective.

Consequently, she remained on CIC for one year. Based on the epidemiology, exam results, failure of tamsulosin trial, and the need for CIC, Fowler Syndrome was considered to be the most probable diagnosis, and SNM was proposed to the patient.

The patient underwent an SNM phase test in June 2021. Results were very positive with the first voiding occurring at 8 hours after phase test surgery. The bladder sensation was completely restored and she had spontaneous voiding 4 to 5 times a day, with voiding diaries volume ranging from 200 mL-600 mL, without PVR. In July 2021 definitive implant was placed with also great results and a PVR of less than 150 mL. No post-surgical complications occurred and the patient has, since then, remained on follow-up, maintaining good satisfaction. The patient maintained a normal voiding pattern one year after implantation, and even after a two-week withdrawal period, reported continued efficacy of the treatment.

Discussion/Conclusion

FS physiopathology is still not totally understood. In 1950, a sphincter abnormality, with evidence of hypertrophy on cystoscopy examination, causing voiding dysfunction in women was first described [4,9]. This syndrome is characterized by chronic urinary retention. It is estimated that more than 50% of the patients have an association with polycystic ovaries or endometriosis [4,10], so it has been linked with hormonal interference [11].

According to European Association of Urology (EAU) 2022 guidelines, "idiopathic urinary retention, also known as FS, is a primary disorder of the external urethral sphincter with hypertrophy of the muscle fibers, which fail to relax during micturition. It is associated with decreased detrusor contractility via enhancement of the guarding reflex" [12].

The usual patient had been reported as a post-menarche and pre-menopause young woman between 20 to 30 years old [2,4,5,11]. Often, a trigger event such as gynecological surgery (30%), other surgical procedures (13%), childbirth (15%), and acute illness (7%) is found. Complain LUTS like infrequent voiding, intermittent urinary stream and longer time to void was also reported. When reaching maximum bladder capacity and complete urinary retention patients typically complain lower abdominal pain rather than a normal urge to void. There is no identifiable structural or neurological cause of urinary retention [4,13].

This case reports a young woman that was diagnosed with FS because of an asymptomatic episode of acute complete urinary retention without organic or structural causes. She reported progressive voiding and post-voiding symptoms previously to the first urinary retention episode. Furthermore, repetitive cystitis could be caused by urinary stasis due to higher PVR volumes. Controversially to the classic patient, there were no trigger situations or pharmacologic therapeutic implied and this woman does not have polycystic ovaries or endometriosis documented.

Fowler and colleagues recorded myotonia-like Electromyographic (EMG) activity in the striated urethral sphincter of women presenting with urinary retention. They proposed that the urinary retention was due to a primary impairment of sphincter relaxation [2]. A careful needle EMG analysis displays that there are two components to sphincter activity: Complex Repetitive Discharges (CRDs) and Decelerating Bursts (DBs) [5], called ephaptic inter muscle fibers signal transmission due to indirect electric fields [10].

In spite of not have performed concentric needle EMG, there are some studies questioning its value on FS diagnosis because they

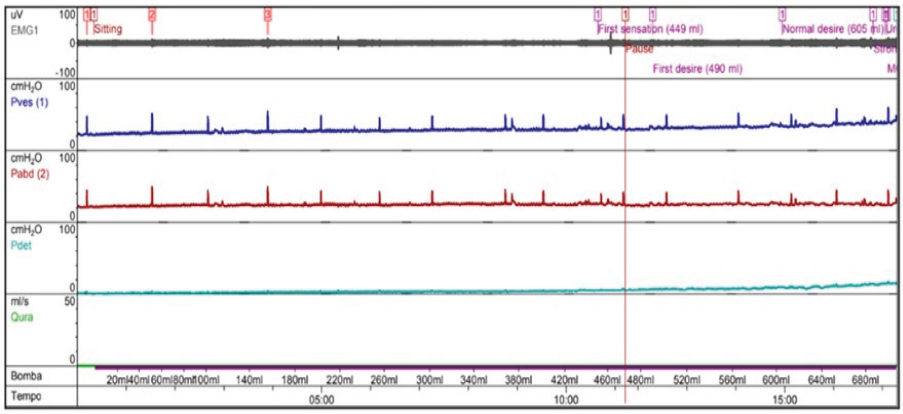

Figure 1: Filling phase pressure-flow study - total infused volume 710 mL. First sensation occurred when 449 mL were infused. During filling phase Pdet had a low increment. Conclusions: Good compliance and high bladder capacity. No detrusor overactivity. Low bladder sensation and low increased detrusor pressure. Pdet = detrusor pressure, MCC = maximal cystometry capacity.

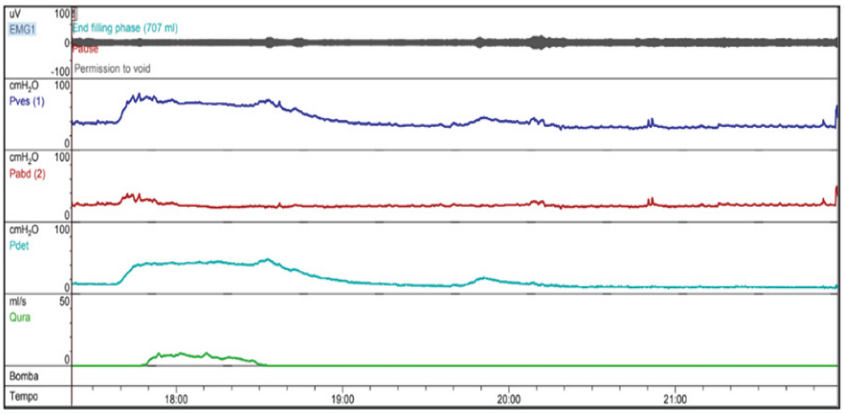

Figure 2: Voiding phase pressure-flow study- Qmax 8.7 mL/s, time to Qmax 23 s, Pdet increased to a maximum of 14 cmH2O, Pdet Qmax 43 cm H2O, voided volume 241 mL, PVR 498 mL, BCI=86.5, BOOIf=23.26. Conclusions: there is detrusor underactivity and no bladder outlet obstructions, if we consider EAU criteria for female DU: Qmax<12 mL/s or PVR>150 mL or BCI<100 and BOOIf >18 for unobtsruction (12). Qmax=maximal flux; Pdet= detrusor pressure, DU=detrusor underactivity; EAU=European Association of Urology; PVR=Post residual volume; BCI=bladder contractility index (PdetQmax+5Qmax); BOOIF=bladder outlet obstruction index female (Pdet Qmax- 2.2 Qmax).

obtained information is qualitative and do not add information about severity and abnormality [2]. CRDs and DBs of striated urethral sphincter have been found in a high proportion of asymptomatic (no urinary symptoms and complete bladder emptying) women and it is believed that this pattern is influenced by the menstrual cycle phase. So, the presence of CRDs and DBs in needle EMG does not automatically establish the FS diagnosis [11].

Besides this clinical course and urodynamic study, the diagnosis is challenging [2,5] and a high suspicion level is necessary. Organic causes must be excluded as well as neuroaxis pathologies.

Cystometric findings are according to literature reviews [2]. It reveals a large-capacity bladder with decreased sensations during the filling phase. During the emptying phase, the patient start to voiding, but with a low flux (Qmax 8.7 mL/s) and a large PVR was registered which seems like an hypocontractile detrusor. We can also observe the micturion ends early with an increased activity in surface electromyography concomitantly. No neuroaxis dysfunction and a structural urinary tract anatomy were objectivated.

A lot of theories about FS had emerged. It is theorized that extreme involuntary sphincter contraction results in the highlighting of the guarding reflex repressing bladder sensation and detrusor contraction withdrew [2]. During the filling phase, intense striated urethral sphincter afferent signals are produced due to CRDs of the urethral sphincter creating autonomous circuitous excitatory activity, leading to impaired relaxation of the urethral sphincter during voiding. These signals inhibit the afferent activity of the bladder in the sacral cord reducing the signal transmission to the Periaqueductal Grey (PAG) and high cerebellar centers, already demonstrated by functional magnetic resonance imaging studies [5,14]. Indirectly, we can interprete the patient urodynamics findings in concordance with this theory.

Based on this hypothesis panoply of treatments had been tried. Medications such as alfa blockers (aiming to promote relaxation of the urethral sphincter) have been tried with no effects as well as urethral dilatations under general anesthesia. Botulinum toxin injection into the urethral sphincter has not been successful [13]. Any patients had symptomatic benefits and some had developed transient stress incontinence suggesting that sufficient toxin had been given to cause sphincter weakness [4].

Phosphodiesterase inhibitor sildenafil citrate has been proposed as an option, based on augmenting nitric oxide-induced relaxation of the rhanbdosphincter, but in a placebo-controlled trial no proven benefits [2]. Most women end with CIC, or as alternative, a suprapubic catheter is placed [4].

SNM is the only intervention that can restore normal voiding in women with FS [2,4]. It is a minimal-invasive technic that stimulates sacral nerve root in order to modulate the neural pathway that controls the functioning of the bladder and pelvic floor [15]. There had been made a lot of research around SNM mechanism but it still remain understood. Authors had report that SNM change activity in brain areas responsible for detrusor overactivity, bladder filling sensation, urge and micturition time [16]. It is hypothesized that SNM acts inhibiting the guarding reflex, in which the external urethral sphincter contraction results in intravesical low pressure, preventing urinary leaks. In this sense, diminishing the sphincter tone will allow bladder emptying [17].

Imaging studies compared the brain activity in healthy women with urinary retention women found that healthy bladder fullness enhanced activity in brainstem (midbrain) and limbic cortical regions. In contrast, women with urinary retention exhibited no substantial brainstem activity but did demonstrate enhanced limbic cortical activity when the bladder was full in the absence of neuromodulation. Sacral neuromodulation appears to re-establish a normal pattern of midbrain activity and decreased cortical activity in this group [18].

Based this, it is believed that SNM assists bladder emptying by blocking inhibition by urethral afferents, leading to restoration of activity associated with brainstem autoregulation and attenuation of cingulate activity [14,18,19].

Wondrous results had been reported with this electric therapy. Not seldom, a woman who had been on CIC for a long time could have an urge to void around 12 hours after the onset of stimulation. Spontaneous voiding by detrusor contraction follows shortly after this [13]. It was reported that FS is a positive predictive factor of success for SNM in female urinary retention [1].

In this case report, it was possible to verify the efficacy of SNM as the patient was able to void spontaneously some hours after surgery, even after one year on CIC, and restored bladder-sensitive functions. The woman is still on follow-up with no complaints about the procedure, she can void normally without PVR. Curiously, the effects of SNM remain event when the device is switch-off. This effect was recently published by Liechti M [20], in neurogenic patients, raising the hypothesis that neuromodulation can give memory-effect and last-longer, without the need of continuous stimulus an open a new option for patients that eventually will need to remove the devide, for example, in case of pregnancy desire, later in life, where SNM its now advised due to lack of studies.

References

1. De Ridder D, Ost D, Bruyninckx F. The presence of Fowler's syndrome predicts successful long-term outcome of sacral nerve stimulation in women with urinary retention. Eur Urol. 2007;51(1):229-33; discussion 233-4.
2. Panicker J, DasGupta R, Elneil S, Fowler C . Pelvic Organ Dysfunction in Neurological Disease: Clinical Management and Rehabilitation, Urinary retention. Cambridge: Cambridge University Press. 2010:293-306.
3. Swinn MJ, Wiseman OJ, Lowe E, Fowler CJ. The cause and natural history of isolated urinary retention in young women. J Urol. 2002;167(1):151-6.
4. Osman NI, Chapple CR. Fowler's syndrome--a cause of unexplained urinary retention in young women? Nat Rev Urol. 2014;11(2):87-98.
5. Szymański JK, Słabuszewska-Jóźwiak A, Jakiel G. Fowler's Syndrome-The Cause of Urinary Retention in Young Women, Often Forgotten, but Significant and Challenging to Treat. Int J Environ Res Public Health. 2021;18(6):3310.
6. Ahmad I, Krishna NS, Small DR, Conn IG. Aetiology and Management of Acute Female Urinary Retention. Br J Med Surgical Urology. 2009;2(1):27-33.
7. Knox SJ. Psychogenic urinary retention after parturition, resulting in hydronephrosis. Br Med J. 1960;2(5210):1422-4.
8. Montague DK, Jones LR. Psychogenic urinary retention. Urology. 1979;13(1):30-5.
9. Moore T. Bladder-neck obstruction in women. Proceedings of the Royal Society of Medicine. 1953;46(7):558-64.
10. Trachta J, Wachter J, Kriz J. Chronic Urinary Retention due to Fowler's Syndrome. European J Pediatr Surg Rep. 2018;6(1):e77-e80.
11. Tawadros C, Burnett K, Derbyshire LF, Tawadros T, Clarke NW, Betts CD. External urethral sphincter electromyography in asymptomatic women and the influence of the menstrual cycle. BJU Int. 2015;116(3):423-31.
12. Harding CK, Lapitan MC, Arlandis S, Bø K, Cobussen-Boekhorst H, Costantini E, et al. EAU guidelines on management of non-neurogenic female lower urinary tract symptoms. The EAU. 2022.
13. Swinn MJ, Fowler CJ. Isolated urinary retention in young women, or Fowler's syndrome. Clin Auton Res. 2001;11(5):309-11.
14. Kavia R, Dasgupta R, Critchley H, Fowler C, Griffiths D. A functional magnetic resonance imaging study of the effect of sacral neuromodulation on brain responses in women with Fowler's syndrome. BJU Int. 2010;105(3):366-72.
15. Mass-Lindenbaum M, Calderón-Pollak D, Goldman HB, Pizarro-Berdichevsky J. Sacral neuromodulation - when and for who. Int Braz J Urol. 2021;47(3):647-56.
16. De Wachter S, Vaganee D, Kessler TM. Sacral Neuromodulation: Mechanism of Action. Eur Urol Focus. 2020;6(5):823-5.
17. Kessler TM, Fowler CJ. Sacral neuromodulation for urinary retention. Nat Clin Pract Urol. 2008;5(12):657-66.
18. Dasgupta R, Critchley HD, Dolan RJ, Fowler CJ. Changes in brain activity following sacral neuromodulation for urinary retention. J Urol. 2005;174(6):2268-72.
19. De Wachter S, Vaganee D, Kessler TM. Sacral Neuromodulation: Mechanism of Action. Eur Urol Focus. 2020;6(5):823-5.
20. Liechti Martina D, van der Lely S, Knüpfer Stephanie C, Abt D, Kiss B, Leitner L, et al. Sacral Neuromodulation for Neurogenic Lower Urinary Tract Dysfunction. NEJM Evid. 2022;1(11).