American Journal of Surgery Case Reports

ISSN: 2766-8304

Case Report

Surgical Repair for Atrial Functional Mitral Regurgitation

Ohba M[1], Asano S[2], Kabasawa M[2], Ito T[2], Matsuo K[2], Hayashida N[3], Murayama H[3] and Tanaka M[3]*

[1]*Department of Cardiovascular Surgery, Kawaguchi Municipal Medical Center, Saitama, Japan*

[2]*Department of Cardiovascular Surgery, Chiba Cardiovascular Center, Chiba, Japan*

[3]*Department of Cardiovascular Surgery, Nihon University School of Medicine, Tokyo, Japan*

Abstract

In recent years, there have been several reports related to the mechanism of onset of Atrial Functional Mitral Regurgitation (AFMR), but clear guidelines or procedures for the surgical treatment of AFMR have not yet been established. We obtained good results by adding left atrium plication to the enlarged Left Atrium (LA), which is considered to be one of the causes of AFMR. This procedure can be one option used for the surgical treatment of AFMR.

Keywords: Atrial functional mitral regurgitation; Mitral repair; Enlarged left atrium

Introduction

Atrial Fibrillation (AF) is one of the common arrhythmias. Chronic AF causes Left Atrial (LA) enlargement and results in annular mitral dilatation [1]. The dilatation further leads to Atrial Functional Mitral Regurgitation (AFMR). AFMR improves if sinus rhythm is restored [2]. However, the percentage of patients free from AF was found to be significantly lower in patients with a Left Atrial Dimension (LAD) >60 mm than in patients with an LAD <60 mm following radiofrequency-modified Maze procedure [3]. Therefore, the Maze procedure is not suitable for the treatment of AFMR, and other procedures may be required instead. Mitral Valve (MV) repair leads to a reduction in Mitral Regurgitation (MR). However, if the movement of the Posterior Mitral Leaflet (PML) is limited, MV repair alone is insufficient. We developed a technique whereby LA plication was added to release the tethering of the PML from the posterior wall of Left Ventricle (LV) and ensure favorable coaptation with the Anterior Mitral Leaflet (AML).

Case Presentation

This case report included 3 male patients who underwent MV repair for AFMR. All of them had severe degrees of MR and chronic AF that had persisted for 10 years, and did not have significant elongation or calcification of their MV leaflets. The New York Heart Association (NYHA) class was II in all patients. The ages were 76 years in patient 1, 78 years in patient 2, and 55 years in patient 3 [1-3].

All patients underwent Transthoracic Echocardiography (TTE) and Transesophageal Echocardiography (TEE) in our hospital. TTE and TEE revealed normal mitral leaflets and chordae without organic valvular disease, significant enlargement of mitral annular diameter and LA (Figure 1A and B), and severe MR despite normal valvular structure (Figure 2A). The antero-posterior systolic diameter of the LA was measured using the parasternal long-axis view. The LV had moderately impaired function [Ejection Fraction (EF) 40% to 50%] in all patients. Tricuspid Regurgitation (TR) was graded as severe in all patients.

Surgery was undertaken through a median sternotomy. Cardiopulmonary bypass was established by ascending aortic cannulation and bicaval venous return. Cardiac arrest and protection were achieved via moderate hypothermia and antegrade cold blood cardioplegia. The MV was exposed through a left-sided atrial approach. All patients underwent LA plication, MV annuloplasty, and Tricuspid Valve (TV) annuloplasty. Initially, LA plication was performed by a procedure of para-annular plication that Kawazoe et al. [4] had described. Next, after measuring the inter commissural distance, an annuloplasty ring (Physio II, Edwards Life sciences, Irvine, CA, USA) of the same size was implanted using interrupted 2-0 Nespolene sutures (Alfresa Pharma Corporation, Osaka, Japan). The valve coaptation was tested by saline injection into the LV across the valve. The ring sizes implanted were 32 mm, 30 mm and 34 mm [1-3]. Finally, TV annuloplasty was performed using an annuloplasty ring (Carpentier-Edwards Physio Tricuspid annuloplasty ring, Edwards Life sciences, Irvine, CA, USA).

No patients had valve-related morbidity or mortality. Postoperatively, the NYHA class improved from II to I in all patients.

TTE and TEE were performed in all patients. Postoperative MR was trivial in two patients and mild in one (Figure 2B). The mitral pressure gradient was 3 mmHg, 4 mmHg and 2 mmHg, respectively. In all patients, the LA diameter was significantly reduced (70 mm → 57 mm [1], 65 mm → 59 mm [2], 65 mm → 50 mm [3]), and the LV diastolic dimension was reduced (59 mm → 56 mm [1], 64 mm → 58 mm [2], 53 mm → 49 mm [3]). The LV EF had slightly changed (46.6% → 48.9% [1], 41.3% → 52.9% [2], 49.5% → 50% [3]).

The Cardiothoracic Ratio (CTR) in the chest radiograph was reduced in all patients (59% → 57% [1], 65% → 55% [2] (Figure 3A and B), 50% → 46% [3]).

Discussion

In this series, we did not perform the Maze procedure for AF. As described above, the Maze procedure does not have good results in

Citation: Ohba M, Asano S, Kabasawa M, Ito T, Matsuo K, Hayashida N, et al. Surgical Repair for Atrial Functional Mitral Regurgitation. Am J Surg Case Rep. 2020;1(1):1002.

Publisher Name: Medtext Publications LLC

Manuscript compiled: Jun 03rd, 2020

***Corresponding author:** Masanao Ohba, Department of Cardiovascular Surgery, Kawaguchi Municipal Medical Center, 180 Nishiarai-juku Kawaguchi Saitama 333-0833, Japan, Tel: 81482872525; Fax: +81482801566; E-mail: naoohbanao@yahoo.co.jp

patients with an LAD >60 mm, and therefore, the procedure is not performed in such patients according to the criteria followed in our hospital.

Chronic AF leads to mitral annular dilatation. In these patients, as the LA expands, the posterior wall of the LA extends to the LV side, so that the mitral annulus rides up the LV muscle layer. As a result, the PML is pulled to a state called Hamstring Leaflet, and its movement is restricted (Figure 1B) [5,6]. Therefore, the length of the PML seems to shorten in appearance. These changes cause AFMR. During surgical intervention, sometimes perfusion can only be controlled by MV annuloplasty, but the coaptation zone tends to be thin. We experienced that sometimes sufficient coaptation zone cannot be obtained with Mitral valve repair alone. Therefore, we think that adding LA plication is important. PML patch augmentation is one alternative for improving the thin coaptation zone; however, the results when using autologous or heterologous pericardium are controversial [7], and it is not an absolute indication. Therefore, we added LA plication (para-annular plication) to eliminate the swelling of the posterior wall of the LA and prevent the posterior mitral annulus from being pulled towards the posterior wall, returning it to its original position and restoring the PML to its original size. A 4 mm to 5 mm coaptation zone was achieved in an intraoperative ink test [8]. In the postoperative TEE, MR had improved to trivial or mild, and in the TTE, the LAD had markedly shrunk. CTR also improved in the chest radiograph. No significant improvement was observed in EF, but the NYHA class had improved from II to I. In our study, this surgical procedure was considered to be effective. However, as the numbers of patients were small and the long-term results are still not available, presuming this procedure to be the optimal method would be premature. However, because there are few cases of AFMR and there are very few reports on surgical treatment of AFMR, the present report can be considered useful. In summary, our results suggest that MV annuloplasty with LA plication can be a feasible option for surgery for AFMR.

Conclusion

LA plication improved the tethering toward the posterior wall of the PML, and performing LA plication in addition to mitral valve annuloplasty was shown to be an effective procedure to treat AFMR.

References

1. Kotecha D, Lam CS, Van Veldhuisen DJ, Van Gelder IC, Voors AA, Rienstra M, et al. Heart failure with preserved ejection fraction and atrial fibrillation. J Am Coll Cardiol. 2016;68(20):2217-28.

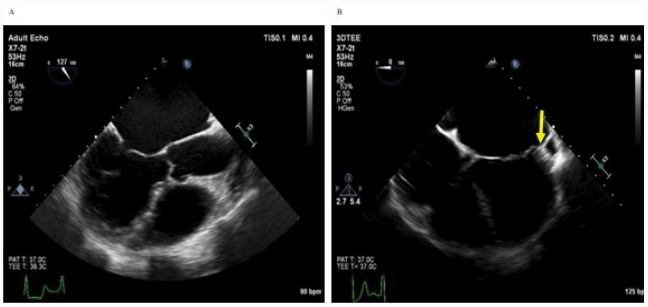

Figure 1: Preoperative TEE (A) TEE showing normal mitral leaflets, chordae and significant enlargement of mitral annular diameter. (B) The posterior leaflet curves and rides up to the muscle layer of the basal posterior wall of the LV.

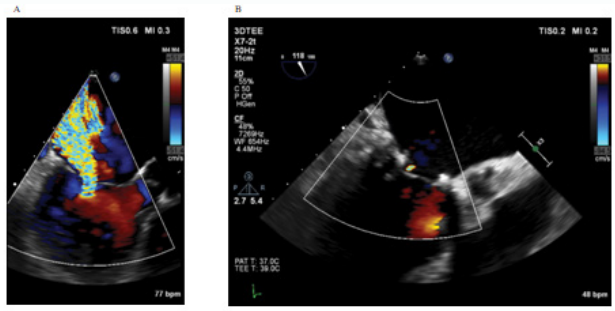

Figure 2: (A) Preoperative TEE with severe MR. (B) Postoperative TEE with trivial MR.

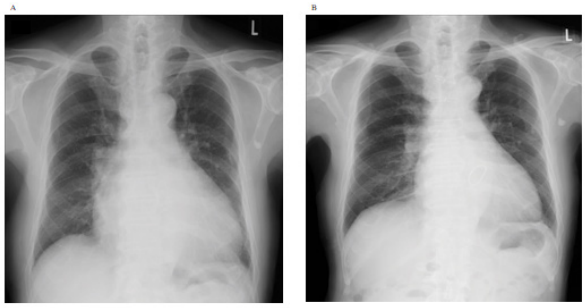

Figure 3: Preoperative TEE (A) TEE showing normal mitral leaflets, chordae and significant enlargement of mitral annular diameter. (B) The posterior leaflet curves and rides up to the muscle layer of the basal posterior wall of the LV.

2. Gertz ZM, Raina A, Saghy L, Zado ES, PA-C, Callans DJ, et al. Evidence of atrial functional mitral regurgitation due to atrial fibrillation. J Am Coll Cardol. 2011;58(14):1474-81.

3. Beukema WP, Sie HT, Misier AR, Delnoy PP, Wellens HJ, Elvan A. Predictive factors of sustained sinus rhythm and recurrent atrial fibrillation after a radiofrequency. Modified Maze procedure. Eur J Cardiothorac Surg. 2008;34(4):746-51.

4. Kawazoe K, Beppu S, Takahara Y, Nakajima N, Tanaka K, Ichihashi K, et al. Surgical treatment of giant left atrium combined with mitral valvular disease. J Thorac Cardiovasc Surg. 1983;85(6):885-92.

5. Takahashi Y, Abe Y, Sasaki Y, Bito Y, Morisaki A, Nishimura S, et al. Mitral valve repair for atrial functional mitral regurgitation in patients with chronic atrial fibrillation. Interact Cardiovasc Thorac Surg. 2015;21(1):163-8

6. Machino-Ohtsuka T, Seo Y, Ishizu T, Sato K, Sugano A, Yamamoto M, et al. Novel mechanistic insights into atrial functional mitral regurgitation -3-Dimensional echocardiographic syudy. Cic J. 2016;80(10):2240-8.

7. Miura T, Eishi K, Sakamoto I, Yamachika S, Hashizume K, Tanigawa K, et al. Time-dependent change in fresh autologous pericardium applied for posterior mitral annuloplasty: degree of calcification and influence on the repaired mitral valve. Gen Thorac Cardivasc Surg. 2012;60(6):334-40.

8. Anyanwu AC, Adams DH, The intraoperative "ink test": a novel assessment tool in mitral valve repair. J Thorac Cardiovasc Surg. 2007;133(6):1635-6.