Annals of Surgical Education

ISSN: 2692-7926

Research Article

Tips and Tricks for a Sound Rives - Stoppa Repair

Oprea V[1], Toma M[1], Grad O[1,2] and Moga D[3,4]*

[1]Department of Clinical Surgery, Constantin Papilian Emergency Military Clinical Hospital, Romania

[2]Department of Surgery, Iuliu Hatieganu University of Medicine and Pharmacy, Romania

[3]Department of Clinical surgery, Alexandru Augustin Military Hospital, Romania

[4]Lucian Blaga University of Sibiu, Romania

Abstract

Background: Incisional and ventral hernia repair is a frequent and challenging topic. Reconstructive techniques are numerous but most of them are unable to achieve the goals of hernioplasty. Rives-Stoppa repair is the gold standard for midline abdominal wall hernias. Our goal is to describe the "step-by-step" procedure for midline incisional hernia repair.

Method: The posterior rectus sheath is incised and the retrorectus plane is developed. For a safe repair the technique, tips and tricks for developing this space are thorough. Mesh is placed in a sublay fashion above the posterior layer. In an overwhelming majority of patients, the Linea Alba is reconstructed, creating a functional abdominal wall with wide mesh reinforcement.

Results: Since 1998, when the procedure was implemented in our Department, 1598 midline incisional hernia patients were operated according to this technique. Mean age was 58.9 years (24-79) with midline defects ranging from 3 cm to 12 cm (mean size 7.9 cm). Major preoperative morbidity present in 17.8% patients. In 178 patients, the anterior fascia cannot be closed, the procedure ending as a retro-rectus bridged repair. Wound complications Surgical Site Events (SSE) encountered in 255 patients (15.95%). Follow-up for 1 to 21 years (mean 8.7 years) with a recurrence rate of 7.8%.

Conclusion: Rives-Stoppa repair is the procedure of choice for all midline incisional hernia being primary or recurrent if the defect is smaller than 8 cm with favorable immediate and long-term outcomes, regardless of age.

"A surgeon can do more for the community by operating on hernia cases and seeing that his recurrence is low than he can by operating on cases of malignant disease" Sir Cecil Wakeley 1948.

Keywords: Surgical site events; Abdominal wall reconstruction; Incisional hernias

Background

The weak abdomen of the human biped has been provided by laparotomy with regrettable iatrogenic 'opportunities" for herniation of a complex kind [1]. Indeed, 15%-20% (sometimes more in high-risk group patients) of all laparotomies are complicated by Incisional Hernias (IH), transforming it into the most frequent reason for reoperation [2,3].

The field of Abdominal Wall Reconstruction (AWR) has seen significant advances in the past decades especially due to the understanding of core anatomy and functionality. The revival of the concept of recreating a functional, dynamic, and anatomically sound Abdominal Wall (AW) by reconstruction of the linea alba led to the emergence and promotion of several innovative techniques involving separation of components [4].

The foundation of AWR can be linked by the seminal work of French surgeons Jean Rives and Renee Stoppa. In 1965, Stoppa developed the preperitoneal space to place a large sheet of polyester mesh (Mersilene®) for the repair of complex and multiply recurrent groin hernias (Giant Preperitoneal Prosthetic Repair) [5]. The forces that act to form hernias became now the factors to protect against recurrence [3]. A year later, Rives revolutionized the technique of repairing IH by placing the same polyester mesh between the Rectus Muscle (RM) (anterior) and posterior rectus sheath (posterior). This reconstructive surgeons brought forth to the concept of posterior component separation to assure complete medialization of the linea alba. Retromuscular Rives-Stoppa repair has gained significant results in the recent surgical era so it was declared "gold standard" for midline IH repair. The goal of this paper is to present step by step operative technical details of the procedure and to promote it for all surgeons.

Methods

Step by step procedure for midline IH [6-9].

Preoperative preparation

When planning an AWR the most important first step is to clarify patients' expectations for a successful outcome. Detailed patients' history, previous operative notes, and physical findings are the foundation of the surgical repair. Assess risk stratification in collaboration with the anesthesiologist, cardiologist, and pneumologist. Assess and correct nutritional status, especially obesity. A Body Mass Index under 35 kg/m^2 is necessary for a scheduled surgery. Deep vein thrombosis and antibiotic prophylaxis according to local protocols. Abdominal CT scan is mandatory for defining hernia characteristics and for assessing nature of the contents, volume

Citation: Oprea V, Toma M, Grad O, Moga D. Tips and Tricks for a Sound Rives - Stoppa Repair. Ann Surg Edu. 2022;3(1):1028.

Publisher Name: Medtext Publications LLC

Manuscript compiled: Feb 09th, 2022

***Corresponding author:** Valentin Oprea, Department of Clinical Surgery, "Constantin Papilian" Emergency Military Clinical Hospital, Cluj-Napoca nr 22 Gral Traian Mosoiu street, Cluj-Napoca, Cluj County, Romania, Tel: +40-745608567; E-mail: opreacv31@gmail.com

of the contents of the sac, the percentage of the contents in the sac, and the size of the defect. Always measure the width of both rectus sheath; if the ratio between width of the defect and the sum of the rectus sheaths is lesser than 2, surely a Rives - Stoppa repair can be performed (Carbonell equation).

Incision

Commonly the procedure begins with a midline laparotomy according to hernia location. Old scars and skin ulcerations are removed at this time or at the end of the operation. The umbilicus, if necessary, is removed to minimize postoperative morbidity (always inform the patient about the possibility and note in the informed consent). The peritoneal cavity is entered through the middle of the sac; the sac is dissected from the subcutaneous adhesions until the medial shift of the RM is reached. Preserve the sac until the posterior rectus fascia is closed.

Adhesiolysis

Is a critical step, as the Abdominal Wall (AW) will be limited in its mobility if it remains fixated to the viscera? Completely free all the bowel/omentum adhesions from the undersurface of the AW taking care to preserve the integrity of the peritoneum and of the posterior rectus sheath. All prior synthetic material, if any, is removed to allow better integration of the new mesh. In addition, it reduces the risk of seroma formation and infections. At the end, protect the peritoneal content with a large wet soft towel.

Creation of the retro-rectus space: begins with the identification of the medial edge of the rectus muscle. Identify visual and by palpation this landmark; if the identification fails, incision of the posterior rectus sheath it is placed improperly, into the hernia sac and the dissection will advance into the subcutaneous plane (Figure 1).

When correctly identified, a horizontal incision is made on the posterior aspect of the sheath, 0.5 cm - 1 cm apart of its medial edge (Figure 2).

The plane is correctly approached if the fibers of the rectus muscle are easy visualized. The incision is carried along the posterior sheath that is open as far to exceed 5 cm to 7 cm the upper and lower limit of the defect. It is not wrong to approach the retro-rectus space placing the incision on the anterior aspect of the rectus sheath, especially when difficulties for identification and dissection are expected (Figure 2). Some surgeons do it deliberately on one size in order to preserve a large peritoneal flap (which usually, in this situation, resides attached on the posterior sheath) for an easier tensionless closure of the posterior fascia. Doing such that we can loss 1 cm to 2 cm of the anterior fascia, which can be paramount for the anterior fascia closure. Once the edge of the posterior rectus sheath is freed from the rectus muscle, constant tension is need to develop the retro-rectus space. Dissection is facilitated by placing two hemostatic clamps on both anterior and posterior sheaths; diverging this upward and medially a constant tension is created to develop the retro-rectus space. A combination between blunt (with a mounted swab) and sharp or electric dissection should be used to advance laterally until the Spiegel line is approached. The perforating neurovascular bundles define the boundary, which looks like the "comb teeth" (Figure 3). Proceed similarly on the contralateral side.

When both sheaths are opened and the retro-rectus space is created, cephalad and caudal extensions are developing according to the location of the defect. Should the hernia defect extend into the upper abdomen, the surgeon may need to develop the dissection up to the costal margin and behind the xiphoid process to the retro-sternal space.

1. For midline hernias with cephalad extension, at least 6 cm below the xiphoid a plane needs to be established to connect bilateral retro-rectus spaces across the midline. Linea alba is maintained in continuity, ventral to the mesh for at least 5 cm by dividing the insertion of each posterior sheath into the linea alba in the cranial direction about 0.5 cm lateral to it.
2. For upper abdominal defects, first divide linea alba to the xiphoid process. Then incise the posterior insertion of the posterior rectus sheath into the xiphoid; the fatty triangle obtained like that assures extension to the substernal plane.
3. For inferior defects, the transition into the pelvis involves the division of the medial attachments of the arcuate line. Following that the pre-peritoneal plane is developed. The inferior epigastric vessels, running along the posterior surface of the rectus muscles need to be identified and preserved. Caudally the dissection extends 2 cm to 3 cm bellow the pubis symphysis and Cooper's ligaments.

Closure of the posterior fascia

The leafs of the posterior rectus sheaths are re-approximated in the midline for an estimation of tension - closure. If the flaps are unable to be connected, use the peritoneal flaps resulting from the sac dissection or the great omentum to patch the resulting hole. A piece of Vicryl absorbable mesh, if available, could be an excellent option. When the re-approximation is possible without tension a running suture with a 2-0 slowly absorbable stitch (Polydioxanone) is

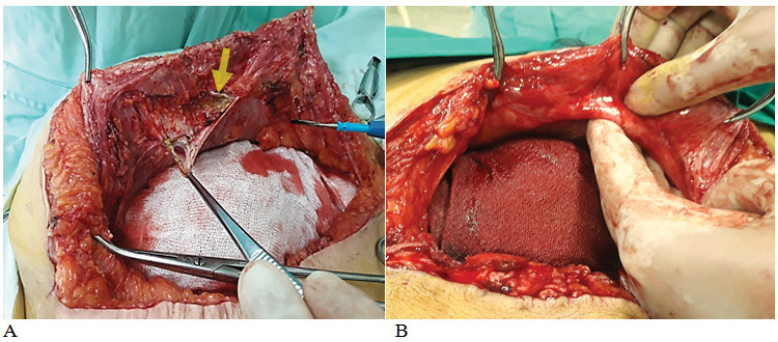

Figure 1: A) If the rectus muscle is not correctly identified, the incision of the rectus sheath will be inadequately placed and the dissection will advance in a wrong plane (usually in the subcutaneous tissue) (arrow); B) the correct bi-manually maneuver for rectus complex identification.

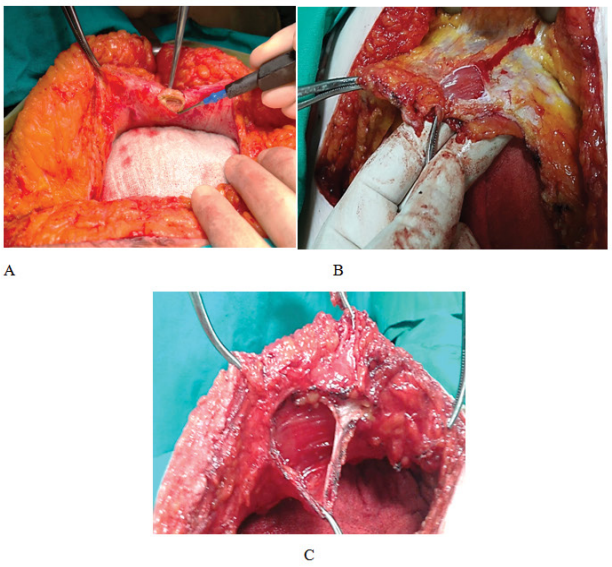

Figure 2: A) Incision of the rectus sheath on its posterior aspect about 1.5 cm apart from midline; B) Incision of the rectus sheath on its anterior aspect; C) After correct identification of the muscular fibers of the rectus muscle the incision of the rectus sheath is carried along the entire defect cranially and caudally (dotted yellow line).

of choice. In our experience, using polypropylene is disadvantageous due to the intense adhesions between bowels and stitches (Figure 4).

This is a crucial step of the procedure because sheath's breakdown exposes to intra-parietal hernia, a challenging complication, difficult to diagnose and to manage. Therefore, the posterior sheath has to be close, has to be close well, and has to be close safely.

Mesh insertion and fixation

The retro-rectus space is variable between patients and it must be measured in its length, and width and the mesh trimmed to adequate size. Usually, s medium or light - weight monofilament large pores polypropylene mesh is the best choice (40 g/m^2-60 g/m^2). There is no real consensus regarding if, where, and how to fix the mesh in this retro-rectus plane. We usually suture the mesh to both Cooper's ligaments and to the symphysis with a number 1 slowly absorbable sutures if the mesh is advanced in the pre-vesical space. Cranially, two stiches fixe the mesh around the xiphoid covering, the epigastric area, and retro-sternal space. Laterally, two trans-fascial sutures passed with a Reverdin needle are inserted on both sides. At the end, the mesh should be flat, with some kind of tension, in order to increase mesh - tissue area interface.

The mesh could be fixed with permanent sutures to the posterior rectus sheath but the technique is blind and expose to an increased risk of inadvertent bowel injury. Another option is to fix the mesh with cyanoacrylates (Hystoacril™). It is quick and safe but its efficiency it is not proved yet by prospective studies. Fixation will remain a personal choice. Two suction drains are placed on the mesh surface or in Retzius space (Figure 5).

Anterior fascial closure

With a size 0 or 1 running slowly absorbable suture. A subcutaneous drain is optional; otherwise, the subcutaneous tissue is closed interrupted absorbable sutures. Skin is closed according to preferences. An abdominal binder is recommended in the first postoperative days in order to reduce seroma formation. After that is patient's choice.

Results

We implement the procedure in our Departmentin1998, and since then to 2019, 1598 midline incisional hernia patients were operated according to this technique. Mean age was 58.9 years (24-79) with midline defects ranging from 3 cm to 12 cm (mean size 7.9 cm). Major preoperative morbidity present in 17.8% patients. In 178 patients operated until 2014 November, the anterior fascia cannot be closed, the procedure ending as a retro-rectus bridged repair. Wound complications Surgical Site Events (SSE) encountered in 255 patients (15.95%). Follow-up for 1 to 21 years (mean 8.7 years) with a recurrence rate of 7.8%.

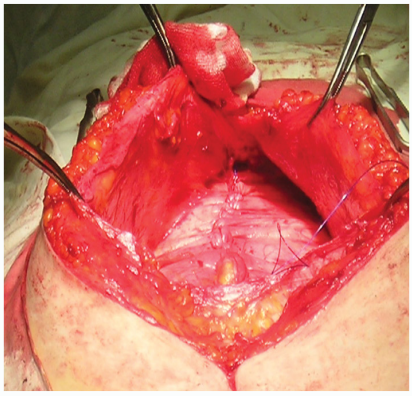

Figure 4: The posterior rectus sheath is closed in a running manner.

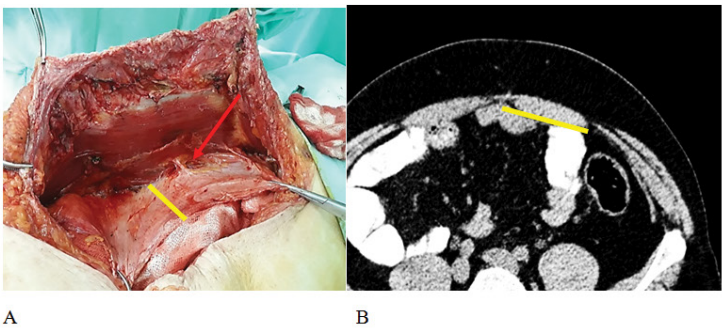

Figure 3: A) The retrorectus space developed; this width cam be measured preoperatively on the native CT scan (B-Yellow line) and intraoperatively (A-yellow line). The red arrow marks the lateral extension of the retrorectus space defined by the neurovascular bundles.

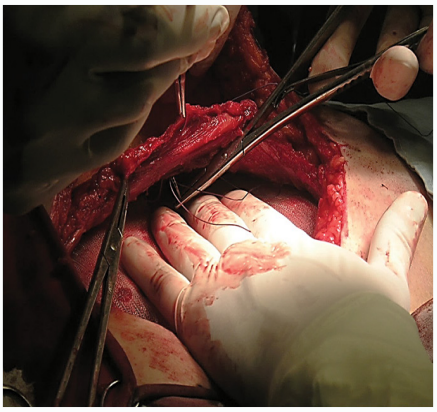

Figure 5: Mesh fixation with trans-fascial sutures.

Discussion

The benefit of the retro-rectus repair of abdominal wall defects has been well documented over the years by many authors after Rives and Stoppa published their researches. This technique provides many advantages in the reconstruction of complex defects [6]:

1. The retro-rectus space is an easily dissected potential space in almost all instances; in our experience the space cannot be attend only twice.
2. It is a well-vascularized compartment with a more efficient collagen deposition and mesh integration
3. In a recent systematic review and network meta-analysis sub-lay was associated with lower risk of recurrences and SSI compared to on-lay, inlay and underlay. Sub-lay was ranked the best mesh placement option with a high probability of being the best treatment (94.2% probability of having the lowest odds of recurrence and 77.3% probability of having the lowest odds for SSI) [10].
4. Fulfils in most instances the goals of modern hernia repair: the restoration of a functional abdominal wall by recreating the linea alba reinforced with a large prosthetic mesh overlap and with minimal early and late wound morbidity.

Frequent impossibility of closing the anterior fascia in large defects, narrow atrophied retrorectus space with limited mesh overlap, and obliterated retromuscular space usually by meshes with fibrosis are the main limitations of the procedure.

References

1. Stoppa R, Ralaimiaramanana F, Henry X, Verhaege P. Evolution of large ventral incisional hernia repair. The French contribution to a difficult problem. Hernia. 1999;3(1):1-3.
2. Sanders DL, Kingsnorth A. The modern management of incisional hernias. BMJ. 2012;344:e2843.
3. Flament JB, Rives J, Palot J, Burde A, Avisse C. Treatment of major incisional hernias. In: Bendavid R, Abrahamson J, Arregui Me, Flament JB (eds.) Abdominal Wall Hernias. Principles and Management. Springer Verlag New-York, Berlin, Heidelberg. 2001:508-16.
4. Hultman CS, Tong WM, Kittinger BJ, Cairns B, Overby DW, Rich PB. Management of recurrent hernia after components separation: 10-year experience with abdominal wall reconstruction at an academic medical center. Ann Plast Surg. 2011;66(5):504-7.
5. Arora E, Kukleta J, Ramana B. A Detailed History of Retromuscular Repairs for Ventral Hernias: A Story of Surgical Innovation. World J Surg. 2022;46(2):409-15.
6. Tastaldi L, Alkhatib H. Incisional Hernia Repair: Open Retromuscular Approaches. Surg Clin North Am. 2018;98(3):511-35.
7. Carbonell AM. Rives-Stoppa retromuscular repair. In: Novitsky YW (editor). Hernia Surgery. Current principles. Switzerland; Springer. 2016:107-15.
8. Rosen MJ. Posterior component separation with transversus abdominis muscle release. In: Rosen MJ (editor). Atlas of Abdominal Wall Reconstruction. 2nd ed. Philadelphia: Elsevier. 82-109.
9. Duce AM, Noguerales F, Villeta R, Hernández P, Lozano O, Keller J, et al. Modifications to Rives Technique for Midline Incisional Hernia Repair. Hernia. 2001;5(2):70-2.
10. Holihan J, Nguyen DH, Nguyen MT, Mo J, Kao LS, Liang MK. Mesh Location in Open Ventral Hernia Repair: A Systematic Review and Network Meta-analysis. World J Surg. 2016;40(1):89-99.