

Case Report

Unusual Root Development in a Pre-Eruptive Intracoronal Resorptive Lesion of Permanent Molar: A Rare Occurrence

Kumar N^{*} and Kumari R

Unit of Pedodontics and Preventive Dentistry, Oral Health Sciences Centre, All India Institute of Medical Sciences, India

Abstract

Pre-Eruptive Intracoronal Resorption (PEIR) is a radiolucent lesion located in the dentin adjacent to the Dentinoenamel Junction (DEJ). Preservation of the tooth is mandatory if PEIR is present in permanent molars and premolars except in cases of third molar where extraction would be the best treatment option. In this case report PEIR in the permanent second molar was diagnosed and necrotic pulp was removed, root canals were irrigated, sealed with Mineral Tri-oxide Aggregate (MTA) and coronal seal with Glass Ionomer Cement (GIC) and composite resin was done. After 24 months of follow up patient was asymptomatic and the tooth showed almost complete root development.

Keywords: Pre-eruptive lesion; Regeneration; Mineral tri-oxide aggregate; Root development; Intra coronal radiolucency

Introduction

Pre-Eruptive Intracoronal Resorption (PEIR) is a radiolucent lesion often located in the dentin, adjacent to the dentinoenamel junction, underneath enamel of the crown. These lesions resemble dental caries radiographically, so can be called pre-eruptive caries or intra-follicular caries, hidden caries or occult caries [1,2]. The etiology of PEIR is still unclear, however it has been suggested that local factors like ectopic positioning of the tooth or pressure from the adjacent tooth may induce the resorptive cells, osteoclasts macrophages and odontoclasts, to invade the dentin through enamel defects or the cemento-enamel junction [3-5].

The prevalence of PEIR ranges from 3% to 27.3% based on the subject and 0.5% to 3.9% based on the teeth [3,6,7]. Single tooth is commonly affected by PEIR followed by two teeth or more in permanent dentition. No significant differences were reported related to gender predilection. PEIR is most commonly located in the mesial half rather than distal portion of the crown. PEIR is usually asymptomatic but may be associated with pain if the coronal resorption is involving the pulp. Restoration of the tooth in mild and moderate involvement or extraction in extensive lesions involving the pulp is usually indicated.

The present case report highlights a case of pre-eruptive intracoronal resorption of the permanent mandibular right second molar and its management using endodontic regenerative procedure.

Citation: Kumar N, Kumari R. Unusual Root Development in a Pre-Eruptive Intracoronal Resorptive Lesion of Permanent Molar: A Rare Occurrence. *J Pediatr Dent Hyg.* 2022;2(1):1007.

Copyright: © 2022 Neeraj Kumar

Publisher Name: Medtext Publications LLC

Manuscript compiled: Jul 11th, 2022

***Corresponding author:** Neeraj Kumar, Unit of Pedodontics and Preventive Dentistry, Oral Health Sciences Centre, All India Institute of Medical Sciences, PGIMER, Chandigarh, India, Tel: +91-9855344680; E-mail: dr.neeraj001@gmail.com

Case Presentation

A 12-year-old girl reported to the unit of Pediatric dentistry with a chief complaint of pain in the lower right back tooth since one month. Medical history was not significant with no systemic disease or other ailments. No relevant past dental history was found. Clinical examination revealed partially erupting grayish colored second molar and the overlying alveolar mucosa distal to the erupting second molar with normal color and texture (Figure 1A). Informed consent was taken prior to Intraoral Periapical (IOPA) radiograph. IOPA radiograph revealed a clear radiolucent area in the crown of erupting second molar extending from the occlusal surface into the dentin and pulp (Figure 1B). Pre-eruptive intra-coronal resorptive lesion was diagnosed and the decision was made to remove the defective tooth structure in the resorbed area and preserve the tooth and attempt was made to regenerate the root development. Parents were counseled about the treatment plan and informed consent was taken. After administration of local anesthesia (2% lignocaine with 1:200,000 adrenaline), rubber dam application was done to isolate the tooth. Access cavity preparation was done and the abscess oozes out from the tooth (Figure 2A). After complete debridement of the undermining tooth structure the canals were irrigated and the triple antibiotic paste was placed on the orifice of the canals and sealed with GIC (Fuji II). After a week the patient was asymptomatic the tooth was reopened and the canals were irrigated with sodium hypochlorite

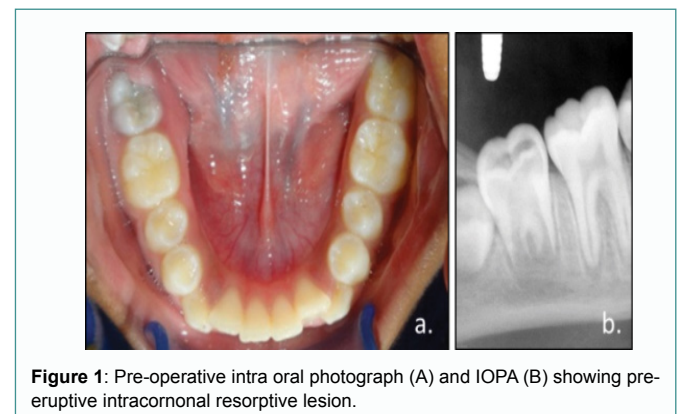


Figure 1: Pre-operative intra oral photograph (A) and IOPA (B) showing pre-eruptive intracoronal resorptive lesion.

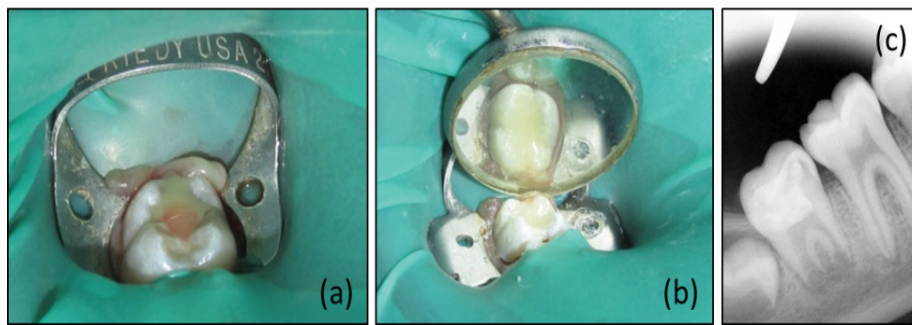


Figure 2: Access cavity was prepared, exudate was cleared (A) and the cavity was sealed with MTA, GIC and composite resin restoration (B) and IOPA after complete restoration (C).

2.6%, saline and Mineral Tri-oxide Aggregate (MTA) (Angelus Solucoes Odontologicas, Londrina, Brazil) was placed over the blood clot and sealed with GIC (Fuji II) and Composite resin (3M, ESPE, USA) to acquire a complete coronal seal (Figure 2B). A periapical radiograph was taken post operatively and the patient was kept on regular follow ups (Figure 2C). After six months of follow-up the tooth was asymptomatic with normal appearance of the tooth and restoration. A radiograph demonstrated continued root development and almost complete apical closure after 6 (Figure 3), 12 (Figure 4) and 24 months follow up (Figure 5).

Discussion

Pre-eruptive intracoronar resorption is rare radiolucent lesions which are diagnosed inadvertently by radiographic examination. It is usually found in the permanent dentition or rarely in the primary dentition. The exact etiology of PEIR is still unknown. Four theories have been proposed like apical inflammation of the primary teeth, dental caries, developmental anomalies like enamel or dentin hypoplasia and internal resorption due to inflammation in the pulp could be the possible etiologies of PEIR [8,9]. In the present case internal resorption due to inflammation in the pulp cavity could be the reason of PEIR.

The enamel in PEIR found to be clinically intact because of its relative hardness and resistance to resorption but there is destruction of dentin with or without apparent external clinical signs or symptoms. This could be due to minimal secondary microbial infection through a small or sealed external opening through which resorptive cells had gained entry into the dentin during the developmental stages of the tooth. In both the cases the teeth were erupting partially covered by the overlying gingiva and there was destruction of dentin with enamel intact.

Radiolucent lesions within the unerupted/erupting teeth may represent hypoplasia of enamel or dentin, large buccal pits or resorptive lesions. Resorption may be due to the local factors like pressure from the local forces, trauma or infection or systemic factors like excessive parathyroid secretion however in PEIR no local or systemic factors have yet been delineated [10-12]. Radiolucent lesions in unerupted teeth are usually round in appearance, and located adjacent to the dentinoenamel junction. The most common location of the resorptive lesion is on the mesial half of the crown. PEIR can be mild if only a portion of dentin is involved, moderate if whole of the dentin is involved without involving the pulp and the lesion is extensive if it involves the pulp. In the present cases the lesions were extensive which involved the pulp.

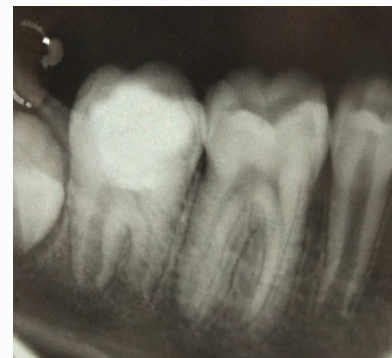

Figure 3: IOPA after 6 months of follow up showing root development.

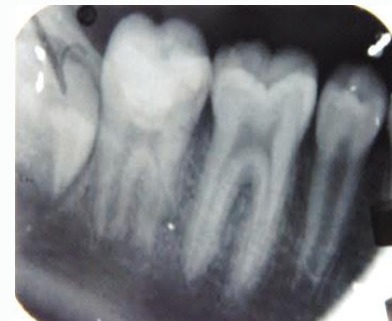


Figure 4: IOPA after 12 months of follow up showing root development and almost apical closure.

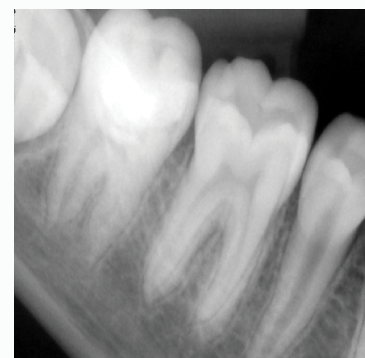


Figure 5: IOPA after 24 months showing apical closure equivalent to first permanent molar.

Although histologic studies [13-15] suggested the evidence of resorptive cells such as osteoclasts, macrophages and multinucleated giant cells at the advancing front of the lesion but the initiating factors are unknown. Loss of integrity of the reduced enamel epithelium which envelopes the developing tooth is thought to be a major factor for the penetration of these cells. The cells of Hertwig's Epithelial Root Sheath (HERS), cells of the apical papilla, odontoblasts and cementoblasts plays a vital role in root formation/development in permanent teeth [16]. There might be disturbance in the root formation if some of the factors like trauma, iatrogenic manipulation of the tooth happens at an early age. This could lead to unusual/aberrant root development with some defects in the root portion of the tooth. There is literature which supports the unusual/aberrant root development in the young permanent traumatized tooth [17]. In the present case after access opening under rubber dam, instrumentation was done in controlled manner so that not to disturb the root walls and apical area of the tooth to preserve the cells of HERS and apical papilla which later helps in the root development.

Intracoronar defects of unerupted teeth present challenging problems in diagnosis and management. The treatment guidelines recommended surgical exposure of the unerupted tooth to prevent the progression of the resorptive process into the dental pulp. In this case, the extensive radiolucent area under the enamel of the erupting mandibular second molar required an immediate intervention due to a concern of pulp involvement. Early diagnosis and prompt treatment could results in the preservation of the tooth and prevention of the future malocclusion.

Conclusions

1. Early diagnosis of pre-eruptive intracoronar resorptive lesion is essential to prevent pulp involvement before/after tooth eruption.
2. Immature dentin might be a source of pulpal inflammation in young permanent teeth.
3. Endodontic regeneration/root development should be a treatment option in PEIR and occult caries/hidden caries to preserve the tooth.
4. Regenerative cells like Stem cells of apical papilla could be responsible for the root growth however histological studies would be needed to confirm the positive outcome.

Acknowledgement

The authors want to acknowledge that the present case was managed at Post graduate Institute of Medical Education and research, Chandigarh. The details related to the present case were not copied from any other sources. The authors have no conflict of interest.

References

1. Guinta JL, Kaplan MA. "Caries-like" dentin radiolucency of unerupted permanent tooth from developmental defects: Case report. *J Pedodont*. 1981;5(3):249-55.
2. Werheijim KL, Kidd EA, Groen HJ. The effect of fluoridation on the occurrence of hidden carried clinically sound occlusal surfaces. *Caries Res*. 1997;31(1):30-4.
3. Seow WK, Lu PC, Mcallan LH. Prevalence of pre-eruptive intracoronar dentin defects from panoramic radiographs. *Pediatr Dent*. 1999;21(6):332-9.
4. Seow WK, Wan A, Mcallan LH. The prevalence of pre-eruptive dentin radiolucencies in the permanent dentition. *Pediatr Dent*. 1999;21(1):26-33.
5. Seow WK. Pre-eruptive intracoronar resorption as an entity of occult caries. *Pediatr Dent* 2000(5);22:370-6.
6. Nik NN, Abul Rahman R. Pre-eruptive intracoronar dentin defects of permanent teeth. *J Clin Pediatr Dent*. 2003;27(4):371-5.
7. Umansky M, Tickotsky N, Friedlander-Barenboim S, Faibis S, Moskovitz M. Age related prevalence of pre-eruptive intra-coronar radiolucent defects in the permanent dentition. *J Clin Pediatr Dent*. 2016;40(2):103-6.
8. Walton JL. Dentin radiolucencies in unerupted teeth: report of two cases. *ASDC J Dent Child*. 1980;47(3):183-6.
9. Rankow H, Croll TP, Miller AS. Preeruptive idiopathic coronar resorption of permanent teeth in children. *J Endod*. 1986;12(1):36-9.
10. Tronstad L. Root resorption--etiology, terminology and clinical manifestations. *Endod Dent Traumatol*. 1988;4(6):241-52.
11. Andreasen JO. External root resorption: its implication in dental traumatology, paedodontics, orthodontics and endodontics. *Int Endod J*. 1985;18(2):109-18.
12. Chuong R, Kaban LB, Kozakewich H, Perez-Arayde A. Central giant cell lesions of the jaws: A clinicopathologic study. *J Oral Maxillofac Surg*. 1986;44(9):708-13.
13. Grundy GE, Pyle RJ, Adkins KF. Intra-coronar resorption of unerupted molars. *Aust Dent J*. 1984;29(3):175-9.
14. Brooks JK. Detection of intracoronar resorption in an unerupted developing premolar: report of a case. *J Am Dent Assoc*. 1988;116(7):857-9.
15. Taylor NG, Gravely JE, Hume WJ. Resorption of the crown of an unerupted permanent molar. *Int J Paediatr Dent*. 1991;1(2):89-92.
16. Andreasen JO. Pulp and periodontal tissue repair-regeneration or tissue metaplasia after dental trauma. A review. *Dent Traumatol* 2012;28(1):19-24.
17. Kumari R, Kumar N, Gauba K. An Aberrant Root Development in Severely Extruded Immature Young Permanent Tooth: A Case Report. *J South Asian Assoc Pediatr Dent*. 2020;3(2):84-7.