American Journal of Surgery Case Reports

Case Report

Use of EVAR in the Patient with Acute Case of Aortocaval Fistula (ACF) and Hemodynamic Instability Resulting from Ruptured Abdominal Aorta Aneurysm (rAAA): Case Report

Michał Zalewski[1], Jarosław Janc[2], Patrycja Leśnik[2] and Artur Milnerowicz[1]*

[1]*Department of Vascular Surgery, 4th Military Clinical Hospital, Poland*

[2]*Department of Anesthesiology and Intensive Therapy, 4th Military Clinical Hospital, Poland*

Abstract

Introduction: Rare cases of ruptured infrarenal abdominal aorta aneurysm with the formation of aortocaval fistula can be treated either by open surgery or endovascular approach.

Case: We present a ruptured infrarenal abdominal artery aneurysm with an aortocaval fistula.

Result: Endovascular Aortic Repair (EVAR) procedure was performed with a successful closure of the aortocaval fistula and restoration of hemodynamic stability without need of open abdominal surgery.

Conclusion: EVAR in ruptured aortic aneurysm with aortocaval fistula is safe and efficient way of treatment.

Keywords: Aortocaval fistula; Infrarenal ruptured abdominal aortic aneurysm; Endovascular repair; Endoleak

Case Presentation

A 76-year-old man with a history of uncontrolled hypertension was urgently admitted to hospital due to the single episode of syncope, tachycardia (130-140/min) and hypotension (MAP 60 mmHg-50 mmHg) without abdominal pain. FAST ultrasound indicated abdominal aorta aneurysm with probable dissection/rupture. Patient underwent Computed Tomography Angiography (CTA) which revealed infrarenal aorta aneurysm with Penetrating Atherosclerotic Ulcer (PAU) ruptured into vena cava (aortocaval fistula; ACF) just above the aortic bifurcation without extravasation into the retroperitoneum (Figure 1A). Laboratory test revealed stable hemoglobin level of 10, 8 g/dl, elevated BNP and D-dimer of 4788 pg/ml and 4915 ng/ml respectively. Renal function parameters creatinine 1.52 mg/dl, urea 40.67 mg/dl, sodium 138.6 mmol/l and potassium 4.39 mmol/l. Liver function parameters were normal. Due to the unstable hemodynamic state endovascular approach was preferred. Written informed consent was obtained for the EVAR procedure. Analgosedation was chosen for anesthesia and after balloon predilatation of both iliac arteries due to the atherosclerotic lesions standard Endovascular Aortic Repair (EVAR) was performed percutaneously using GORE Excluder AAA Endoprosthesis (GORE, AZ, USA). Perclose ProGlide (Abbott Vascular, CA, USA) was used to close vascular access sites. Treatment was successfully completed endovascularly (Figure 1B) with complete exclusion of the aneurysm and immediate hemodynamic stabilization. Procedure time was 90 minutes, radiation 280 mGy, and contrast agent volume injected 100 mL. Computed Tomography Angiography (CTA) was performed on the following day minor type II endoleak was present (Figure 1C). The patient was discharged from the hospital 3 days after the surgery. One month later, CTA showed patent stent-graft with no visible type II endoleak (Figure 1D).

Discussion

Aortocaval fistula is rare complication of the ruptured abdominal aorta aneurysm (<1% of cases) and can be approached by both open surgery and endovascular procedure [1]. While compared with open aortic repair in cases of ruptured aortic aneurysm EVAR patients showed lower in-hospital mortality and shorter hospital stay [2]. Lack of recommendation preferring EVAR approach in case of ACF complicate the decision making process [3]. Mass effect of the abdominal aortic aneurysm on the inferior vena cava should also be taken into consideration as it may require additional endovenous intervention [4].

However, in case of ACF usually there is an obvious lack of retroperitoneal hematoma which reduces the risk of intra-abdominal hypertension. Therefore, EVAR procedure might have an initial superiority over open repair in such a case. And might be the first choice in patients with multiple comorbidities and significantly elevated risk of intra- and postoperative death [1,4,5]. Stent-graft delivery systems require certain intraluminal diameter to make EVAR procedure possible.

Citation: Zalewski M, Janc J, Leśnik P, Milnerowicz A. Use of EVAR in the Patient with Acute Case of Aortocaval Fistula (ACF) and Hemodynamic Instability Resulting from Ruptured Abdominal Aorta Aneurysm (rAAA): Case Report. Am J Surg Case Rep. 2023;4(1):1052.

Publisher Name: Medtext Publications LLC

Manuscript compiled: Jan 06th, 2023

***Corresponding author:** Michał Zalewski, Department of Vascular Surgery, 4th Military Clinical Hospital, Wroclaw, Poland, E-mail: zalewski1988@gmail.com

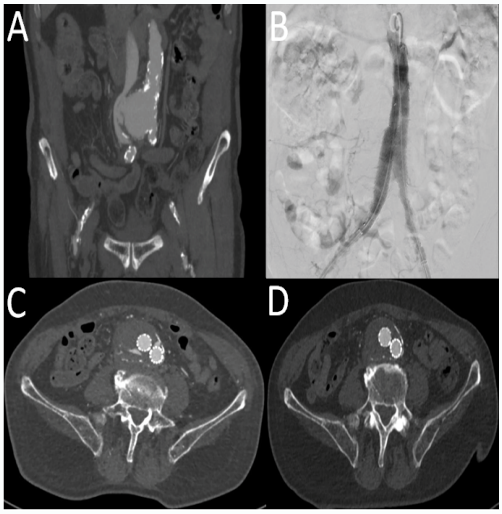

Figure 1: A) Large aortocaval fistula on admission. B) Final angiography showing closure of the aortocaval fistula C) Postoperative CTA showing minor type II endoleak. D) One month after EVAR there is no visible type II endoleak in CTA.

In some patients additional intravascular procedures [6,7] or even minor open surgery [7] might be required for the proper stent-graft placement. This should also be taken into consideration while deciding on operation method.

Most common intravascular complication in endovascular approach is post-procedural endoleak [3]. In this particular case, type II endoleak which was seen day after the procedure resolved spontaneously month later like often observed after EVAR procedures without VCF [8]. Therefore, the type II endoleak seems to be not an issue even in cases with ACF while close patient follow-up and control angiotomography should be introduced to minimize risk of late complications.

Conclusion

EVAR in ruptured aortic aneurysm with the formation of aortocaval fistula is safe and efficient way of treatment.

References

1. Ribeiro T, Ferreira RS, Catarino J, Vieira I, Correia R, Bento R, et al. Primary Aortocaval Fistula in Ruptured Abdominal Aortic Aneurysm: Institutional Experience and Literature Review. EJVES Vascular Forum. 2021;50:43.
2. Mohan PP, Hamblin MH. Comparison of endovascular and open repair of ruptured abdominal aortic aneurysm in the United States in the past decade. Cardiovasc Intervent Radiol. 2014;37(2):337-42.
3. Orion KC, Beaulieu RJ, Black JH 3rd. Aortocaval Fistula: Is Endovascular Repair the Preferred Solution? Ann Vasc Surg. 2016;31:221-8.
4. Oikonomou K, Sachsamanis G, Kasprzak PM, Schierling W, Pfister K. Endovascular Exclusion of Juxtarenal Aortic Aneurysm in Concomitant Presence of an Aortocaval Fistula. EJVES Vascular Forum. 2022;54:e16-7.
5. Dhillon B, Morrow D, Lewis M, Ali T. Abdominal Aortic Aneurysm with Aortocaval Fistula– Staged Endovascular Management. J Vasc Interv Radiol. 2019;30(10):1608-9.
6. Henretta JP, Karch LA, Hodgson KJ, Mattos MA, Ramsey DE, McLafferty R, et al. Special iliac artery considerations during aneurysm endografting. Am J Surg. 1999;178(3):212-8.
7. Vallabhaneni R, Sorial EE, Jordan WD, Minion DJ, Farber MA. Iliac artery recanalization of chronic occlusions to facilitate endovascular aneurysm repair. J Vasc Surg. 2012;56(6):1549-54.
8. Brown A, Saggu GK, Bown MJ, Sayers RD, Sidloff DA. Type II endoleaks: challenges and solutions. Vasc Health Risk Manag. 2016;12:53-63.