

Case Report

A Rare Case of Anomalous Origin of Right Pulmonary Artery with PDA and Features of Eisenmenger Syndrome in 40-Year-Old Nepalese Male

Tsering Phinjok Sherpa¹, Nima Ongchuk Sherpa^{2*}, Rajan Poudel³, Janer Kurumbang⁴, Santosh Karki⁵

¹Department of Internal Medicine, Civil Service Hospital, Nepal

²Department of Emergency Medicine, Karuna Hospital, Nepal

³Civil Service Hospital, Nepal

⁴Department of Internal Medicine, Civil Service Hospital, Nepal

⁵Department of Internal Medicine, Civil Service Hospital, Nepal

Abstract

Adult Congenital Heart Disease (ACHD) encompasses a group of heart conditions that persist from birth and extend into adulthood. This case report focuses on a late-diagnosed case of Anomalous Origin of a Pulmonary Artery (AORPA) with associated features of Eisenmenger syndrome. AORPA refers to the abnormal origin of the Right Pulmonary Artery (RPA) from the ascending aorta, deviating from its typical connection to the main pulmonary artery. The patient, a 40-year-old male, presented with symptoms of blood mixed expectoration, shortness of breath, and a dry cough. Diagnostic procedures, including CT Pulmonary Angiogram, revealed the anomalous origin of the right pulmonary artery along with a patent ductus arteriosus. Further investigations confirmed features of Eisenmenger syndrome, characterized by severe Pulmonary Arterial Hypertension (PAH) and associated clinical findings. This case report highlights the significance of timely diagnosis, individualized care, and regular follow-up for patients with AORPA, PDA, and Eisenmenger syndrome. These complex conditions necessitate a multidisciplinary approach, involving healthcare professionals with expertise in congenital heart diseases and PAH.

Moreover, the article emphasizes the importance of clinical examination, electrocardiography, and imaging techniques in diagnosing AORPA and associated anomalies. CT Pulmonary Angiogram played a pivotal role in confirming the diagnosis in this particular case, given the limitations of echocardiography due to a poor window. Additionally, the management of Eisenmenger syndrome focuses on medical interventions rather than surgical correction due to the presence of irreversible pulmonary hypertension. Medications such as pulmonary vasodilators have shown promising outcomes in improving functional and hemodynamic parameters.

This case report underscores the complexity and challenges involved in diagnosing and managing AORPA with Eisenmenger syndrome. Timely diagnosis, individualized care, and a multidisciplinary approach are crucial for optimizing patient outcomes and improving quality of life.

Keywords: Adult congenital heart disease; Anomalous origin of right pulmonary; Pulmonary arterial hypertension; Eisenmenger syndrome; Patent ductus arteriosus

Introduction

Adult Congenital Heart Disease (ACHD) refers to a group of heart conditions that are present from birth (congenital) and continue into adulthood. These conditions result from abnormal development of the heart during fetal development. However, ACHD is considered a relatively common condition, and its prevalence has been increasing over the years due to improved diagnostic techniques and medical interventions [1]. According to studies conducted in various countries, the estimated prevalence of ACHD ranges from

0.2% to 1.4% of the adult population. In other words, approximately 2 to 14 adults per 1,000 have some form of congenital heart disease. Congenital anomalies of the pulmonary artery refer to structural abnormalities that occur during fetal development and affect the normal formation of the pulmonary artery, which is responsible for carrying deoxygenated blood from the right ventricle to the lungs [2]. These anomalies can involve the size, position, branching pattern, or connections of the pulmonary arteries, for example: Anomalous Origin of a Pulmonary Artery (AORPA), Pulmonary Artery Stenosis, Pulmonary Artery Agenesis or Hypoplasia, Pulmonary Artery Sling, Double Outlet Right Ventricle (DORV), Anomalous Pulmonary Venous Connection [3]. The diagnosis of these anomalies usually involves various imaging techniques, including echocardiography, cardiac MRI and cardiac catheterization. Treatment options depend on the specific anomaly and its impact on blood flow and oxygenation. In this article, we present a late diagnosed case of AORPA with PDA, associated with features of Eisenmenger syndrome which was confirmed by CT Pulmonary Angiogram [4].

Case Presentation

A case of a 40 years old male shop proprietor with no known comorbidities presented at the emergency department with blood mixed expectoration about 20 ml to 30 ml. Fifteen years prior to

Citation: Sherpa TP, Sherpa NO, Poudel R, Kurumbang J, Karki S. A Rare Case of Anomalous Origin of Right Pulmonary Artery with PDA and Features of Eisenmenger Syndrome in 40-Year-Old Nepalese Male. *J Med Public Health*. 2023;4(7):1086.

Copyright: © 2023 Tsering Phinjok Sherpa

Publisher Name: Medtext Publications LLC

Manuscript compiled: Sep 13th, 2023

***Corresponding author:** Nima Ongchuk Sherpa, Medical Officer, Department of Emergency Medicine, Karuna Hospital, Chunikhel, Kathmandu, Nepal

consultation the patient visited a hospital for a similar complaint of hemoptysis where primary intervention was given and discharged. One year prior to the consult, the patient started to redevelop episodic hemoptysis on and off in a fairly minimal amount, no consult was done. One month prior to consultation the patient now developed shortness of breath which was progressive (mMRC II-III) associated with dry cough and increasing frequency of episodes of hemoptysis. He is a non-smoker and non-alcoholic drinker. Patient was born *via* normal vaginal delivery with no complications noted. No history of peripheral or central cyanosis was noted during his childhood period.

Patient was short stature and with well-built presented with blood stained around oral mucosal region. Upon physical examination patient had normal blood pressure of 130 mmhg/80 mmhg with regular pulse of 98 bpm with SP_{O_2} of 88% to 90% in room air. No clinical sign of respiratory distress, cyanosis, and finger clubbing was noted. Symmetrical chest expansion was noted with occasional crackles at infrascapular region bilaterally. A dynamic precordium with normal rate and rhythm was noted with loud P2 heart sound 12 Lead Electrocardiogram showed sinus rhythm associated with right atrial enlargement, p-pulmonale and right ventricular hypertrophy (Figure 1). Chest radiography showed fibrotic changes noted at the right lung (Figure 2).

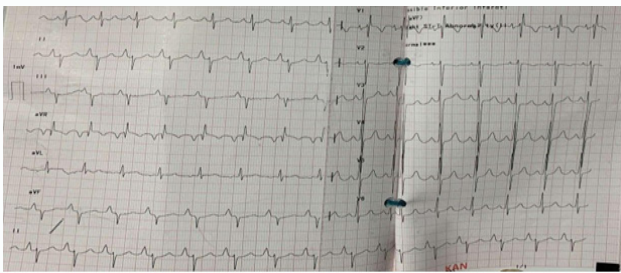


Figure 1: Twelve lead Electrocardiogram showed sinus rhythm associated with right atrial enlargement, p-pulmonale and right ventricular hypertrophy.

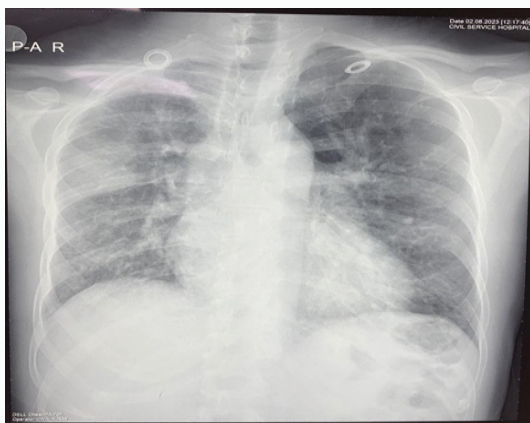


Figure 2: Fibrotic changes noted at the right lung.

Erythrocytosis with thrombocytopenia and lymphopenia was noted in CBC and prolonged PT (16.3) was noted. D-Dimer, ANA and ESR showed within normal range. Peripheral Blood smear suggested Myeloproliferative Neoplasm or Polycythemia vera. JAK2 V617F mutation detection exon 14 (real time PCR) detected no Mutation. Erythropoietin EPO level shown within normal range. Urinalysis

showed gross microalbuminuria and upon 24 hours Total urinary protein collected the report revealed of total urinary volume of 4100 ml and total urinary protein of 1599 ml/24 hrs. Further investigation was done by testing for Glomerular basement membrane antibody, IFA showed negative result to rule out RPGN with/without lung hemorrhage (Goodpasture's syndrome). High Resolution Computed Tomography of the Chest showed Patchy and confluent ground glass opacities in apical and posterior segment of right upper lobe with nonspecific septal thickening scattered in bilateral lung suggesting of Infective pathology. Minimal fibrotic and bronchiectasis in left lingular segment with few mediastinal lymph nodes which suggested to be reactive. Sputum profile revealed normal reports. Poor 2D ECHO window was visualized where only dilated RA, RV, mild TR with Severe PAH (ePASP: 99 mm/hg RSVD (TAPSE:12 mm) and LVEF of 50% was noted (Figure 3). Hence, we proceeded with MDCT Pulmonary angiogram for better visualization which revealed no evidence of pulmonary thromboembolism but an anomalous origin of right pulmonary artery with patent ductus arteriosus was noted. Patchy and confluent ground glass opacities in apical and posterior segment of right upper lobe which suggested of infective pathology (Figure 4). The patient was managed accordingly appropriate antibiotics and supportive treatment such as diuretics. With the result collected diagnosis of anomalous origin of right pulmonary artery with patent ductus arteriosus and severe PAH was made. Due to severe PAH patient was kept under pulmonary vasodilator (Sildenafil 25 mg BID and Bosentan 62.5 mg BID) and was referred to Cardiothoracic vascular and transplant center for further evaluation and management.

2D ECHO was repeated by Pediatric Cardiologist which confirmed congenital heart disease (Eisenmenger Syndrome) with hemitruncus, RPA arises from Ascending Aorta and Left Pulmonary artery arises from MPA (Figure 3). Cardiothoracic Surgeon reviewed the case and noted that patient was clinically improved and stable and noted to have high risk to repair surgically. Hence no active surgical intervention was done and medical management under pulmonary vasodilator was advised. Patient was planned for Transesophageal Echocardiogram if any symptoms persist. Patient was then discharged with Azithromycin 250 mg OD for 3 months with diuretics and pulmonary vasodilator (Sildenafil 25 g BID) and was advised to follow up at CTVS OPD.

Patient is on regular follow up in our Cardiac OPD with no other

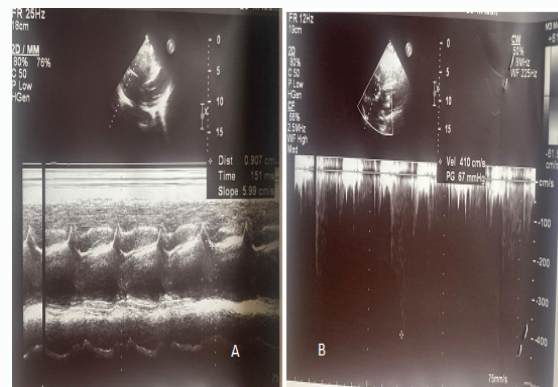


Figure 3: A) 2D ECHO shows right ventricle dysfunction present (TAPSE 9 mm). B) Tricuspid regurgitation (67 mmHg); Severe PAH (TR with estimated pulmonary pressure (67+10=77 mmHg).

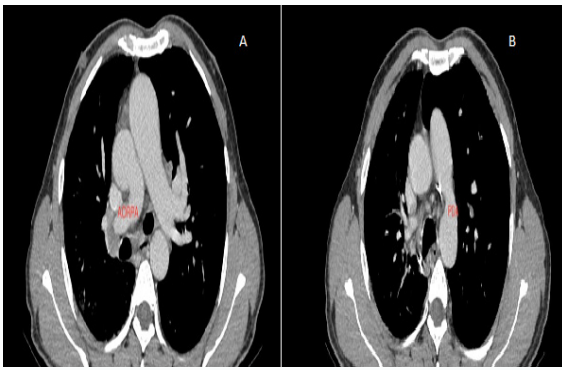


Figure 3: A) 2D ECHO shows right ventricle dysfunction present (TAPSE 9 mm). B) Tricuspid regurgitation (67 mmHg); Severe PAH (TR with estimated pulmonary pressure (67+10=77 mmHg).

significant complaints and clinically improved state of health although shortness of breath occurs during strenuous activity or climbing stairs. Patient was reassured with condition and was advised to have continued follow up routine.

Discussion

Anomalous Right Pulmonary Artery (ARPA), also known as Anomalous Origin of the Right Pulmonary Artery (AORPA), is a congenital cardiac anomaly where the Right Pulmonary Artery (RPA) has an abnormal origin. In a normal heart, the RPA arises from the main pulmonary artery, which carries deoxygenated blood from the right ventricle to the lungs. However, in AORPA, the RPA takes an abnormal course and originates from a different location. In the case of AORPA, the anomalous origin of the RPA occurs from the ascending aorta instead of its usual connection to the main pulmonary artery [5]. This means that the right pulmonary artery branches off from the aorta rather than originating from the right ventricular outflow tract along with the left pulmonary artery. AORPA is a rare condition and often occurs in combination with other congenital heart defects. It can affect the normal blood flow to the lungs and lead to various symptoms depending on the severity of the anomaly and associated abnormalities. It was first described by Wood in 1865, and since then, several cases have been reported in the literature. AORPA is a rare condition, with an estimated incidence of 0.1% to 0.2% of all congenital heart defects. AORPA is most commonly diagnosed in infants and children, but only 5% has been reported in adults [6]. Patients with AORPA may remain asymptomatic for a long time, and the condition may only be discovered incidentally during imaging studies for other conditions or symptoms. The clinical presentation of AORPA can vary widely, from mild to severe, and the prognosis depends on the severity of the anomaly and the presence of associated cardiovascular defects. As like our patient who presented with the complaint of hemoptysis we focused on common causes but missed lots of things due patient overload at first. Hence, clinical examination is crucial and entails a careful assessment of any changes in auscultation findings, blood pressure, or the emergence of heart failure symptoms. Along with a clinical exam, an electrocardiogram (ECG) and puls CT Pulmonary Angiogram was a key diagnostic element in obtaining a diagnosis of Anomalous origin of RPA with a patent ductus arteriosus after a visualizing poor ECHO window. It is a rare cardiac malformation that abnormally originates the right or left pulmonary artery from the aorta has a 30% mortality risk within the first three months of life. Adults who have PAH may develop this high-flow, high-pressure

left-to-right shunt. There is a 0.33% frequency of anomalous origin of right or left pulmonary artery ascending from the aorta in patients with known congenital cardiac disease, and a 30% death rate during the first three months after delivery. Nearly 80% of cases of anomalous origin of the right pulmonary artery fall under the most prevalent subtype, RPA [1,6].

Patent Ductus Arteriosus (PDA) is a fetal vascular structure that persistently connects the proximal descending aorta and the roof of the main pulmonary artery near the origin of the left branch pulmonary artery. Patent Ductus Arteriosus (PDA) is a congenital heart disease found in 1 in 2000 infants and is twice more common in females than in males. Untreated PDA in adults is estimated to be 1.8% per year. PDA in adults is typically discovered by coincidence during a physical examination or echocardiography. It is a rare mature adult's congenital anomaly and the third most frequent congenital anomaly in which the arterial duct that ordinarily shuts spontaneously within 24-48 hours of life in full-term infant's remains open continually. Initially PDA introduces a left to right shunt following an overload of volumes in both left atria and ventricle. PAP increases in moderate and large PDAs. Once patient CHD survives to adulthood with moderate PDA either there will be a left ventricular volume overload or predominant PAH. This condition later progress to Eisenmenger physiology.

A clinical diagnosis of Eisenmenger syndrome is made using physiologic indicators, most frequently isolated massive, unrestrictive, unrepaired shunt lesions at the ventricular or arterial level and complex univentricular situations. Shunt reversal happens as pulmonary vascular disease develops and worsens over time. Patients experience cyanosis, which is frequently accompanied by visual cyanosis and clubbing's. Shunt closure is contraindicated in patients presenting late with established Eisenmenger syndrome, as this will worsen prognosis. Eisenmenger patients have significantly confined life expectancy due to complex underlying heart defects. Shortness of breath, fatigue, vulnerability to physical activity, and palpitations are some of the primary symptoms of Eisenmenger syndrome, which has a varied clinical presentation. Rarely do patients present with hemoptysis alongside bacterial endocarditis or pneumonia. Arrhythmias may be linked to malignant arrhythmias and rapid cardiac death, and cerebral abscess should be feared. Hematological abnormalities include consequences from bleeding and secondary erythrocytosis. In comparison to patients with idiopathic pulmonary hypertension, patients with Eisenmenger have relatively preserved survival prospects.

Similar presentations of hemoptysis like in our patient, Eisenmenger patients frequently experience hemoptysis, which is typically self-limiting. However, large hemoptysis can be fatal. The initial step in evaluating a patient with hemoptysis is to examine their airway, breathing, and circulation. Anticoagulation can be stopped and/or reversed in order to stop bleeding. Airway protection fluid resuscitation and anti-fibrinolytic medications (such tranexamic acid) may be used with caution in cases of significant hemoptysis. Infected lungs should be treated with antibiotics and supportive treatment. Iron should be provided and hemoglobin levels should be adjusted to match oxygen saturation levels. It is advised to maintain strict in-hospital supervision.

Secondary erythrocytosis, a low platelet count, an iron shortage, and hyperuricemia are among the laboratory results. The increase in hemoglobin levels seen in our patients was apparently a welcome compensatory mechanism due to long term Eisenmenger disease

which aimed at increasing the blood's oxygen carrying capacity. As it is best referred to as "erythrocytosis" to distinguish it from Polycythaemia Rubra Vera, with which it does not share the same propensity to thrombotic and embolic events. In our case, we only did a therapeutic phlebotomy was only performed once on the first day of admission, once it been diagnosed with congenital heart defect with severe PAH, secondary erythrocytosis was identified and a routine phlebotomy was not performed. As per the ESC guidelines, therapeutic phlebotomy should be performed only in the presence of moderate/severe symptoms of hyperviscosity secondary erythrocytosis (hematocrit at least >65%), in the absence of dehydration and iron deficiency [5,7].

A study showed that, 16 weeks of therapy, patients in World Health Organization (WHO) functional class III for Eisenmenger have shown improved 6MWT and decreased PVR in response to the ERA bosentan [8]. With less convincing data, experiences with various ERAs and the PDE-5 inhibitors sildenafil and tadalafil demonstrate favorable functional and hemodynamic outcomes in individuals with PAH-CHD and Eisenmenger syndrome. The majority of clinics use a stepwise, symptom-focused approach to treating Eisenmenger syndrome, often beginning with an oral ERA or PDE-5 inhibitor and raising medication if symptoms worsen or if there is a change in the patient's clinical condition.

In general, once a diagnosis of a condition requiring surgery is confirmed, it is often recommended to proceed with surgery as soon as possible. However, in cases like ours where there is presence of irreversible pulmonary hypertension with Eisenmenger syndrome, surgery is contraindicated [6]. Instead, management focuses on medical treatments and interventions to alleviate symptoms, improve quality of life, and slow the progression of the condition. These may include medications to manage symptoms and maintain heart function, supplemental oxygen, and close monitoring by a healthcare team specializing in pulmonary hypertension.

Patients diagnosed with AORPA with features of PAH must be sent to specialized facilities in order to improve their quality of life and results. Such centers should necessitate the use of particular multidisciplinary management techniques by doctors with expertise in congenital heart disorders and PAH.

Conclusion

In conclusion, the management of AORPA, PDA, and Eisenmenger syndrome requires a multidisciplinary approach and individualized care. Timely diagnosis, appropriate interventions, and regular follow-up are essential to optimize patient outcomes and improve quality of life. Collaborative efforts and ongoing research are necessary to further advance the understanding and treatment of these challenging conditions.

References

- Zhou L, Liu X. Anomalous Origin of the Right Pulmonary Artery from the Aorta. *Radiology*. 2022;305(1):220310.
- Liu H, Juan YH, Chen J, Xie Z, Wang Q, Zhang X, et al. Anomalous Origin of One Pulmonary Artery Branch from the Aorta: Role of MDCT Angiography. *Cardiopulmonary Imaging*. 2015;204:979-87.
- Spence MS, Balaratnam MS, Gatzoulis MA. Clinical update: cyanotic adult congenital heart disease. *Lancet*. 2007;370(9598):1530-2.
- Moodie DS. Adult Congenital Heart Disease. *Ochsner J*. 2002;4(4):221-6.
- Baumgartner H, De Backer J, Babu-Narayan SV, Budts W, Chessa M, Diller GP, et al. 2020 ESC Guidelines for the management of adult congenital heart disease. *Eur Heart J*. 2021;42(6):563-645.
- Plata-Corona JC, Hernández-González GL, Candia-Ramírez MA, Sierra Lara JD, Arenas-Díaz JO. Anomalous origin of the right pulmonary artery in a young man with Eisenmenger syndrome. *Arch Cardiol Mex*. 2023;1:1-4.
- Oechslin E, Mebus S, Schulze-Neick I, Niwa K, Trindade PT, Eicken A, et al. The Adult Patient with Eisenmenger Syndrome: A Medical Update after Dana Point Part III: Specific Management and Surgical Aspects. *Curr Cardiol Rev*. 2010;6(4):363-72.
- Galiè N, Beghetti M, Gatzoulis MA, Granton J, Berger RME, Lauer A, et al. Bosentan therapy in patients with Eisenmenger syndrome: a multicenter, double-blind, randomized, placebo-controlled study. *Circulation*. 2006;114(1):48-54.