

## Case Report

# A Rare Case of Robotic Revascularization for Obstructed Left Main with Automated Suture Fastener

Azzahra Edrees<sup>1</sup>, Osama Abdulrahman<sup>2</sup>, Badr Bannan<sup>3</sup>, Mohamed Ismail<sup>4</sup>, Nabeel Ismaeil<sup>5</sup>, Ahmed A. Jamjoom<sup>1</sup> and Uthman Aluthman<sup>1\*</sup>

<sup>1</sup>Department of Cardiovascular, King Faisal Specialist Hospital and Research Center, Saudi Arabia

<sup>2</sup>Department of Medicine, College of Medicine, Umm Al-Qura University, Saudi Arabia

<sup>3</sup>Department of Radiology, Cardiothoracic Imaging, King Faisal Specialist Hospital and Research Center, Saudi Arabia

<sup>4</sup>Cardiothoracic Surgery Cardiac Center, Imam Abdulrahman Bin Faisal University, Saudi Arabia

<sup>5</sup>Department of Cardiovascular, King Faisal Specialist Hospital and Research Center, Saudi Arabia

## Abstract

In comparison to traditional, manual knot-tying, the use of an automated titanium suture fastening device has demonstrated a considerable reduction in cardiopulmonary bypass time, aortic cross-clamp time, and operative time in valve procedures. However, there aren't many reports in the literature on the side effects related to using such device. Here we present a case in which the automated titanium suture fastener resulted in left main coronary artery ostium obstruction following its use in the aortic position and subsequent treatment with robotic Coronary Artery Bypass Grafting (CABG).

**Keywords:** COR-KNOT; Valve surgery; Knot-tying; Robotic CABG; Left main

## Abbreviations

AVR: Aortic Valve Replacement; CABG: Coronary Artery Bypass Grafting; ECG: Electrocardiogram; ECHO: Echocardiogram; LAD: Left Anterior Descending Artery; LIMA: Left Internal Mammary Artery; MVR: Mitral Valve Replacement; PVL: Paravalvular Leak

## Introduction

Knot-tying is a basic part of any valve surgery. However, it can be time consuming and a cause of prolonged aortic cross clamp time and overall cardiopulmonary bypass time [1,2] which leads to higher risk of postoperative organ dysfunction and overall adverse outcomes [3]. An automated titanium suture fastening system otherwise known as the COR-KNOT, has demonstrated a significant reduction in the amount of time needed for cardiopulmonary bypass and aortic cross clamping in valve operations in comparison with conventional, manual knot-tying [2]. The COR-KNOT device has also shown superiority in terms of suture strength and consistency, eliminating the occurrence of loose or 'air' knots that might result with the use of hand-tying or a knot-pusher [4-6]. In terms of complications associated with this device, there have been a few reports in the literature. Namely, paravalvular leak [7,8] embolization [1-9] and leaflet perforation. To our knowledge there has not been any report of coronary obstruction

following COR-KNOT use in aortic valve surgery. Here we report a case of left main coronary artery obstruction following aortic valve replacement using COR-KNOT.

## Case Presentation

A 69-year-old female patient known to have hypertension, diabetes mellitus, and dyslipidemia, presented 3 years following Aortic Valve Replacement (AVR) with tissue valve using the COR-KNOT fastening system. She came to the cardiology clinic in February 2021 complaining of shortness of breath and chest pain described as burning and aching. The pain started one month after her surgery, gradually worsening, aggravated by walking and not relieved even at rest. She was investigated multiple times at an outside facility with Echocardiogram (ECHO), Electrocardiogram (ECG) and upper gastrointestinal endoscopy with normal results. Following her visit with cardiology at our hospital she underwent ECG, ECHO, routine labs and chest X-ray which all came back normal.

The patient was seen and evaluated by multiple physicians and all excluded any cardiac reason. Fibromyalgia and anxiety disorder were among the differential diagnoses. She was prescribed oral pain medications and intravenous lidocaine for the pain with minimal improvement. In April of 2022 she underwent stress testing which was positive for ischemia. A computerized tomography coronary angiogram (Figure 1) (Video 1) and coronary angiogram (Video 2) both revealed the COR-KNOT fastener to be obstructing her left main coronary artery orifice. On May 10<sup>th</sup>, 2022, the patient underwent robotic assisted CABG using one graft (LIMA to LAD). She had an uneventful postoperative course and was discharged on May 16<sup>th</sup>, 2022, in stable condition.

Video 1: <https://youtu.be/YfHQ6ZCfx5Y>

Video 2: [https://youtu.be/znw\\_Io7BSHs](https://youtu.be/znw_Io7BSHs)

## Discussion

The COR-KNOT device, an automated fastener made of titanium, has demonstrated feasibility and efficacy in both open and minimally

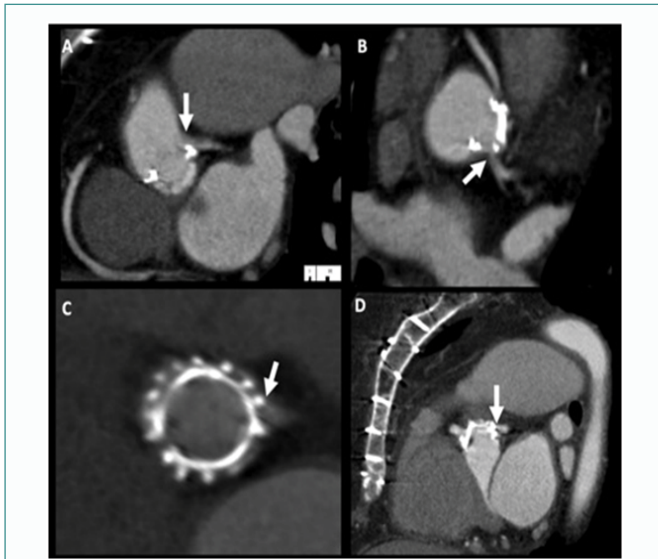
**Citation:** Edrees A, Abdulrahman O, Bannan B, Ismail M, Ismaeil N, Jamjoom AA, et al. A Rare Case of Robotic Revascularization for Obstructed Left Main with Automated Suture Fastener. Am J Surg Tech Case Rep. 2023;3(2):1023.

**Copyright:** © 2023 Uthman Aluthman

**Publisher Name:** Medtext Publications LLC

**Manuscript compiled:** Dec 05<sup>th</sup>, 2023

**\*Corresponding author:** Uthman Aluthman, Department of Cardiovascular, Division of Cardiac Surgery, King Faisal Specialist Hospital and Research Center, Jeddah, Po Box: 40047, Jeddah, 21499, Saudi Arabia



**Figure 1:** Retrospective ECG triggering Coronary CT angiogram with multi-planar reformats in coronal (A), axial oblique (B), short axis (C), and sagittal (D) planes showing dynamic obstruction to the left main coronary artery ostium by the metallic suture fastener (white arrowhead).

invasive valve surgeries [3]. Several studies have shown decreased operative times with the use of the COR-KNOT automated fastener [2-4]. However, this reduction in operative time did not necessarily lead to improved postoperative clinical outcomes [3]. In contrast to operative times, there's very little in the literature that highlights the associated risks and possible adverse outcomes of the COR-KNOT device. The reported complications include paravalvular leak [7,8] embolization [1-9] and leaflet perforation. Paravalvular Leak (PVL) was found to be significant in two cases in a study by Sazzad et al. both valves were readdressed in the same setting, with an overall incidence of PVL to be 5.1%, all of which were trivial to mild [5]. Presented two cases in which the COR-KNOT fastener resulted in leaflet perforation following AVR in one case, and MVR in another case, both necessitating a redo operation [6] also reported a case of aortic leaflet perforation due to a medially directed COR-KNOT placement [8]. In another report by a case of severe aortic valve regurgitation after AVR was found to be due to perforation in one of the leaflets of the explanted valve, which was in alignment with one of the knots made by the COR-KNOT Fastener [9]. These reports all attributed the perforation to the orientation of the knot. In the embolization cases both patients were found to have metal densities on brain imaging which were thought to have originated from the COR-KNOT fastener [1,7]. In our case the patient presented with chest pain after AVR using COR-KNOT fastener. And after multiple normal tests, she eventually had a CT coronary angiogram that revealed the COR-KNOT fastener to be obstructing her left main coronary artery orifice. Following a successful robotic CABG, her symptoms resolved completely. It is believed that the obstruction this patient had was of dynamic nature, hence the normal testing results prior to diagnosis.

## Conclusion

The use of COR-KNOT fastener in the aortic position can result in coronary ostium obstruction. Care should be taken when using the device to avoid such complications in the future.

## References

1. Garrett HE Jr. Delayed metallic embolization of a Cor-knot fastener. *Thorac and Cardiovasc Surg Rep.* 2017;06(01):e40-1.
2. Grapow MT, Mytsyk M, Fassl J, Etteret P, Matt P, Eckstein FS, et al. Automated fastener versus manually tied knots in minimally invasive mitral valve repair: Impact on Operation Time and short- term results. *J Cardiothorac Surg.* 2015;10(1):146.
3. Perin G, Shaw M, Pingle V, Palmer k, Al-Rawi O, Ridgway T, et al. Use of an automated knot fastener Shortens operative times in minimally invasive mitral valve repair. *Ann R Coll of Surg Engl.* 2019;101(7):522-8.
4. Lee CY, Sauer JS, Gorea HR, Martellaro AJ, Knight PA. Comparison of strength, consistency, and speed of cor-knot versus manually hand-tied knots in an ex vivo minimally invasive model. *Innovations (Phila).* 2014;9(2):111-6; discussion 116.
5. Sazzad FS, Xian OZ, Ler A, Guohao C, Swee KG, Kofidis T. Incidence of valvular regurgitation and leaflet perforation by using automated titanium fasteners (CORKNOT<sup>®</sup>) in heart valve repair or replacement: Less usual than reported. 2020.
6. Brescia AA, Bolling SF, Patel HJ. Valvular regurgitation after implantation of prostheses secured with Cor-knot automated fasteners. *Ann Thorac Surg.* 2017;103(6):e491-2.
7. Sagheer S, Sheikh AB, Hallstrom JJ, Raizada V. Metallic Embolus to the brain in a patient with mechanical heart valves: An extremely rare complication. *BMJ Case Rep.* 2019;12(8):230653.
8. Baciewicz FA. Cor-knot perforation of aortic valve leaflet. *Ann Thorac Surg.* 2018;106(3):936-7.
9. Balan R, Mogilansky C, Larsen A-L, Massoudy P. Severe aortic regurgitation after implantation of a suture less valve prosthesis using an automatic knot fastener device. *Interact Cardiovasc Thorac Surg.* 2017;25(1):153-4.