

Case Report

An Unusual Presentation of Thrombotic Microangiopathy after an Aortic Trauma

Valentin de Villiers de la Noue^{*}, Alain Wynckel², Bruno Mourvillier¹ and Antoine Goury¹

¹Intensive Care Unit, Reims University Hospitals, Reims, France

²Department of Nephrology, Reims University Hospitals, Reims, France

Abstract

TMA can be classified as primary TMA in patients with Thrombotic Thrombocytopenic Purpura (TTP) associated with reduced activity of ADAMTS13 (a disintegrin and metalloproteinase with thrombospondin domains, 13th member) or atypical hemolytic and uremic syndrome mostly caused by complement alternative pathway abnormalities.

Keywords: Microangiopathy thrombotic; Aortic hematoma; Eculizumab; Acute kidney injury; Dialysis; Aortic trauma; Intensive care unit

Background

The Thrombotic Microangiopathy (TMA) syndromes are life-threatening conditions characterized by Microangiopathic Hemolytic Anemia (MAHA), thrombocytopenia, and organ injury [1]. TMAs can be classified as primary TMAs in patients with Thrombotic Thrombocytopenic Purpura (TTP) associated with reduced activity of ADAMTS13 (a disintegrin and metalloproteinase with thrombospondin domains, 13th member) or atypical hemolytic and uremic syndrome mostly caused by complement alternative pathway abnormalities. Secondary TMAs may be associated with shiga-toxin or other infection not related to shiga-toxin. It can be also observed in transplantation, malignancies, autoimmune diseases, drugs, and malignant hypertension. Despite their diversity, Acute Kidney Injury (AKI) is one of the most prominent clinical features [2,3]. Outside the surgical context, post-traumatic TMA is a rare entity. Here, we report an unusual presentation of a secondary TMA triggered by an aortic wall hematoma after a fall from a tree.

Case Presentation

A 75-year-old male initially experienced a polytrauma following a fall from a tree. At the emergency room the patient was hemodynamically stable, with pain over the left shoulder and in the left hemithorax. The total body CT-scan showed a left anterior pneumothorax and an anterior luxation of the humeral head with a hematoma. In addition, tomography revealed a hematoma of the aortic wall from aortic isthmus to iliac bifurcation (Figures 1 and 2). The renal perfusion was preserved. After insertion of chest

tube drainage for pneumothorax, the patient was transferred to the intensive care unit.

The days after his admission, the patient presented with anemia (hemoglobin 6.3 g/dL vs. 13.6 g/dL at the admission) and thrombocytopenia (Platelets count $38 \times 10^9/L$ vs. $271 \times 10^9/L$ at the admission) associated with schistocytes on blood smear, a low haptoglobin (<0.10 g/L) and free bilirubin icterus without other associated coagulation disorders. Thus, a TMA was diagnosed. In this context of aortic hematoma, fresh frozen plasma was administered as well as 4 packed red blood cell transfusion according to recommendations. Plasmatic exchanges were not available. Then, he developed a severe AKI (increasing in the serum creatinine from 96 to 432 $\mu\text{mol/l}$ at day 4) complicated by a diuretic resistant acute pulmonary oedema needed dialysis with ultrafiltration and non-invasive ventilation.

TTP was excluded since ADAMTS-13 activity was 53%. There were neither evidence for shiga toxin-producing *Escherichia coli*-HUS neither infections nor infection aHUS (HIV, hepatitis B and C, Influenza H1N1). Search for autoimmune diseases, vasculitis, drugs induced TMA or heparin-induced thrombocytopenia was negative.

We searched to identify a complement predisposition but C1q, C3, C4, CH50 fractions and complement factor B were at normal levels. Finally, in waiting a complete exploration of complement pathways, and regarding to clinical worsening, we decided to start ECULIZUMAB (900 mg by week) at day 4 associated with prophylaxis by ORACILLIN and tetravalent ACWY conjugated and multicomponent serogroup B vaccines.

The outcome was rapidly favorable with increase in platelet count and no evidence for hemolysis. After 3 days of continuous extra-renal epuration, the patient recovered renal function and was weaned from dialysis and oxygen support (Figure 3).

Here, serum concentrations of C3, C4, factor B, factor H and factor I and MCP expression on granulocytes were normal and there were no CFH autoantibodies but genetic analysis was not performed. The patient was discharged from ICU at day 7 and hospital at day 12. After 4 injections of ECULIZUMAB, the patient has fully recovered. At one month, control abdominal CT scan showed a spontaneous regression

Citation: Valentin de Villiers de la Noue, Wynckel A, Mourvillier B, Goury A. An Unusual Presentation of Thrombotic Microangiopathy after an Aortic Trauma. *Ann Clin Cases*. 2022; 3(1): 1038.

Copyright: © 2022 Valentin de Villiers de la Noue

Publisher Name: Medtext Publications LLC

Manuscript compiled: Jul 05th, 2022

***Corresponding author:** Valentin de Villiers de la Noue, Intensive Care Unit, Reims University Hospitals, Reims, France, E-mail: vde-villiers-de-la-noue@chu-reims.fr

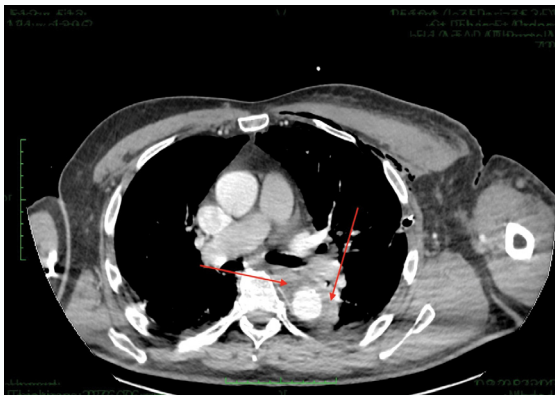


Figure 1: Axial intravenous contrast-enhanced computed tomography thorax images showing an aortic wall hematoma and subcutaneous emphysema in the left hemithorax. The red arrows point to the location of the hematoma.

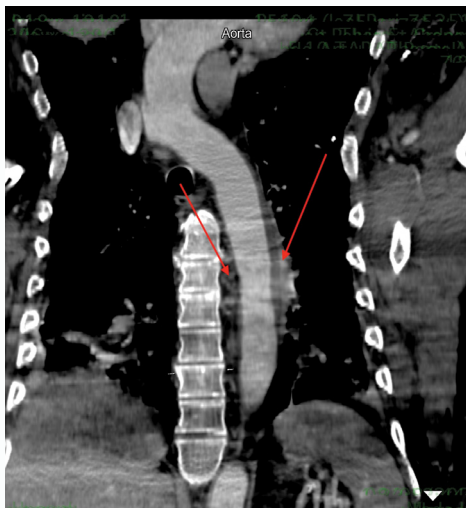

Figure 2: Computed tomography thorax images showing an aortic wall hematoma. The red arrows point to the location of the hematoma.

of aortic hematoma. In this context, ECULIZUMAB treatment has definitively stopped. The patient has never relapsed.

Discussion

To the best of our knowledge, this is the first case of TMA following an aortic trauma without context of open-heart surgery. The

diagnosis of TMA remains a challenge for clinicians, especially in a context of polytrauma. Early treatment is important because TMA is associated with a significant mortality and morbidity including need for renal replacement therapy. To assist clinicians in the investigations and management of a patient presenting with TMA, a stepwise approach is necessary [2]. First, after confirmation of TMA based on laboratory analysis, we should focus initially on the consideration of TTP, because immediate management is imperative given the high mortality rate if untreated. Urgent test for ADAMTS13 activity should be performed. In waiting for the results, we start supportive treatment including fluid resuscitation, intensive care admission, reached a specific non-complement-mediated etiology and discuss plasma exchange. If the ADAMTS13 activity is superior to 10%, this excludes TTP. Thus, in the absence of a specific cause (severe hypertension, infectious, drug induced...), a complement-mediated aHUS must be evocated and treatment with eculizumab is recommended, pending the complete complement evaluation [4]. This syndrome is caused by a dysregulation of the complement system in the alternative pathway, causing vascular endothelial injury and microvascular thrombosis whose consequences are thrombocytopenia, microangiopathic hemolytic anemia and AKI. An investigation into gene mutations of aHUS is needed for the definitive diagnosis of aHUS when the patient has been clinically diagnosed with aHUS. However, the frequency of rare genetic variants in complement genes seems not increased in secondary TMA [5]. Even if complement activation is not the initial trigger, complement activation may occur and prolong MAT. Eculizumab, which inhibits the terminal complement pathway, has demonstrated his efficacy in aHUS [5,6].

In our case, the patient presented a typical TMA. The initial investigation highlighted a possible aHUS because the ADAMTS-13 activity was not lowered (53%). Nevertheless, the aortic trauma could be the starting point of a possible endothelial cell damages can lead to coagulopathy, inflammation and platelet activation [7]. These mechanisms had already been reported in TMA associated with solid organ transplantation [8] or open heart surgery especially with cardiopulmonary bypass or extracorporeal circulation [9]. In our case, the complete complement investigation did not report functional anomalies, but genetic analysis was not performed. Thus, we cannot confirm the aHUS diagnosis and we rather suggest a TMA secondary to an aortic trauma.

Finally, we decided to start Eculizumab at day 4 after his admission. Our strategy had been motivated by the worsening clinical

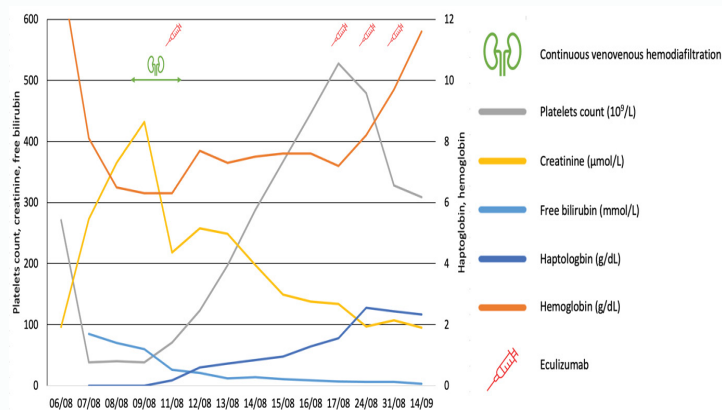


Figure 3: Laboratory findings, therapies and clinical course of the patient.

course and the absence of quickly reversible etiology. The outcome after Eculizumab was quickly favorable with a complete renal function recovery and a discharge from ICU at day 8. Here, plasma exchanges could have been discussed but was not available. We found two cases of patients having trauma-related TMA with normal ADAMTS13 activity (which was consistent with aHUS) and improved after plasma exchanges [10]. In these cases, authors had not performed complement investigation to assess or eliminate the diagnose of aHUS.

The use of complement-inhibiting therapy in TMAs other than complement-mediated aHUS is still controversial [2]. For our patient, according to a complete clinical and biological TMA recovery and the spontaneous regression of aortic hematoma, we finally decided to stop ECULIZUMAB after 4 injections. The optimal eculizumab treatment duration remains still unknown. In absence of strong recommendations [11], we hardly think that use of plasma exchange or ECULIZUMAB to treat a TMA after a severe trauma should remain the choice of experts.

Informed Consent

The authors declare to have informed consent of the patient to publish the case report.

References

- George JN, Nester CM. Syndromes of Thrombotic Microangiopathy. *N Engl J Med*. 2014;371(7):654-6.
- Brocklebank V, Wood KM, Kavanagh D. Thrombotic Microangiopathy and the Kidney. *CJASN*. 2018;13(2):300-17.
- Kerr H, Richards A. Complement-mediated injury and protection of endothelium: lessons from atypical haemolytic uraemic syndrome. *Immunobiology*. 2012;217(2):195-203.
- Legendre CM, Licht C, Muus P, Greenbaum LA, Babu S, Bedrosian C, et al. Terminal Complement Inhibitor Eculizumab in Atypical Hemolytic-Uremic Syndrome. *N Engl J Med*. 2013;368(23):2169-81.
- Le Clech A, Simon-Tillaux N, Provôt F, Delmas Y, Vieira-Martins P, Limou S, et al. Atypical and secondary hemolytic uremic syndromes have a distinct presentation and no common genetic risk factors. *Kidney Int*. 2019;95(6):1443-52.
- Cavero T, Rabasco C, López A, Román E, Ávila A, Sevillano Á, et al. Eculizumab in secondary atypical haemolytic uraemic syndrome. *Nephrol Dial Transplant*. 2017;32(3):466-74.
- Huber-Lang M, Ignatius A, Brenner RE. Role of Complement on Broken Surfaces After Trauma. *Adv Exp Med Biol*. 2015;865:43-55.
- Le Quintrec M, Lionet A, Kamar N, Karras A, Barbier S, Buchler M, et al. Complement mutation-associated *de novo* thrombotic microangiopathy following kidney transplantation. *Am J Transplant*. 2008;8(8):1694-701.
- Huang MJ, Deng JN, Gao LL, Zhou JF. Thrombotic thrombocytopenic purpura complicated with acute aortic dissection: A case report. *Medicine*. 2021;100(46):e27898.
- Ikegami K, Yamagishi T, Tajima J, Inoue Y, Kumagai K, Hirose Y, et al. Post-traumatic thrombotic microangiopathy following pelvic fracture treated with transcatheter arterial embolization: a case report. *J Med Case Rep*. 2018;12(1):216.
- Hossain MA, Ahmed N, Gupta V, Bajwa R, Alidoost M, Asif A, et al. Post-traumatic thrombotic microangiopathy: What trauma surgeons need to know? *Chin J Traumatol*. 2021;24(2):69-74.