

Research Article

An Update on the Advances in Classification as well as Reproductive Surgeries in Mullerian Anomalies - A Systematic Review

Kaur KK^{1*}, Allahbadia G² and Singh M³

¹Kulvinder Kaur Centre for Human Reproduction, Punjab, India

²Rotunda-A Centre for Human reproduction, Mumbai, India

³Consultant Neurologist, Swami Satyanand Hospital, Punjab, India

Abstract

If during development anything goes wrong at the time of development be it in fusion, or mullerian ducts getting resorbed as well as urogenital sinus might end up in a variety of congenital malformations although similar, those of the body of the uterus, cervix, vagina as well as fallopian tubes. Although a variety of classifications as well as definitions have been developed no uniformity exists in globally assessing and evaluating usefulness of surgical procedures for mullerian anomalies, of these the most important one is septate uterus that has undergone varied classifications right from American Fertility Society (ASE) to European Society of Human Reproduction and Embryology (ESHRE)/ European Society of Gynecological Endoscopy (ESGE) and American Society of Reproductive Medicine (ASRM) classifications. Lot of discrepancy exists in the ESHRE/ESGE and ASRM classifications thus need for a modified ASRM classification is urgently needed to bring in uniformity regarding management and evaluate criteria as well as results of surgery uniformly as per Ludwin A the group having done maximum work on the subject. Further details of complicated malformations like Robert's uterus, blind hemivagina, cervical atresia has been discussed in detail.

Keywords: ESHRE/ESGE classifications; Mullerian anomalies; ASRM classification; Septate uterus; Robert's uterus; Cervical atresia; Obstructed hemivagina

Introduction

If during development anything goes wrong at the time of development be it in fusion, or mullerian ducts getting resorbed as well as urogenital sinus might end up in a variety of congenital malformations although similar, those of the body of the uterus, cervix, vagina as well as fallopian tubes [1]. The calculated prevalence of mullerian anomalies in patients that are not selected is about 5%, while in women presenting with reproductive failures have >incidence of uterine abnormalities with 8% prevalence in infertile women and 13% in women having a history of abortion respectively [2]. Sometimes these abnormalities might remain silent or lead to severe health adverse effects including markedly disrupted reproductive function. It is believed that those having same morphology have common embryonic initiation and might associate with clinical importance [3]. A lot of efforts have been made with regards to classification of disorders of mullerian ducts that are paired and give definitions of particular kinds of abnormalities as per morphologic commonness, embryonic initiation, clinical effects as well as how to manage them [1]. During the last 10 years, these classifications as well

as definition have been formed, altered or clarifications given though what are the importance of these with regards to patient management are not properly understood [4,5]. With the development of modern noninvasive/minimally invasive diagnostic equipment's becoming available easily they are utilized for classification as well as surgery plans. These have mostly started getting used instead of the classical diagnostic tools like Hysterosalpingography (HSG), 2 Dimensional Ultrasonography (2D USG), diagnostic hysteroscopy separately [6], as well as hysteroscopy with laparoscopy [5,7].

Earlier, surgeries done for correction of mullerian anomalies was done in women for particular presentation history of Bad Obstetric History (BOH) including recurrent abortions or to increase fertility. In case of observational experiments that clinical meaning of surgery on reproductive results were not same for all kind of anomalies. Lot of benefits as well as advances of pre-surgical qualification as well as intraoperative imaging availability methods, surgical methods as well as post-operative management has been carried out.

A total summarization of reproductive surgery associated with mullerian abnormalities on the basis of previous decade, earlier as well as present classifications, their definition as well as confusion during surgical managing as well as research correlated with the utilization of various definitions.

The differences in anatomy can create reproductive problems for young girls as well as reproductive aged women. Looking after these patients can offer lot of challenges as well as be rewarding, and one needs to be creative in trying to make a plan for patient's management.

Methods

Thus here we tried to update on the classifications of mullerian abnormalities with their definition using the pubmed search engine using the MeSH terms like mullerian abnormalities; classifications be

Citation: Kaur KK, Allahbadia G, Singh M. An Update on the Advances in Classification as well as Reproductive Surgeries in Mullerian Anomalies - A Systematic Review. Am J Surg Tech Case Rep. 2020;1(1):1002.

Copyright: © 2020 Kaur KK

Publisher Name: Medtext Publications LLC

Manuscript compiled: May 12th, 2020

***Corresponding author:** Kulvinder Kochar Kaur, Scientific Director, Dr. Kulvinder Kaur Centre for Human Reproduction 721, G.T.B. Nagar, Jalandhar-144001, Punjab, India, Tel: 91-181-9501358180, 91-181-4613422; E-mail: kulvinder.dr@gmail.com

it ESHRE; ASRM; Surgical procedures to improve fertility outcomes; need for surgery; management of adolescent girls with special complicated abnormalities in last 2 decades from 80s to 2020 till date.

Results and Discussion

We found a total of 7147 articles out of which we selected 70 articles for this review basically with the aim of updating management along with classifications and definitions and improving reproductive outcomes. No meta-analysis was done.

Classifications

American fertility society classification (1988)

Following the 1st classifications of congenital anomalies in 19th century by cruvellier [1], >than 30 classifications as well as their manipulations have been detailed [1]. The commonest used description for morphologic details of anomalies are the terms septate, bicornuate, didelphys as well as unicornuate uterus have a long history [1-7]. Among 1 of the greatest advances was getting the Buttram as well as Gibbons classification in 1979 on the basis of assessment of morphologic kinds of defects that was encountered in clinical practice [3]. Buttram as well as Gibbons system classification was done for abnormalities based on uterine morphology and clubbed them into classes having same presentations, therapy options, as well as prognosis of pregnancy results [8]. This classification was taken up by the American Fertility Society (AFS); given the new name American Society of Reproductive Medicine (ASRM) in 1988. This AFS classification mullerian duct anomalies get classified as per the main uterine kinds [9]. 7 main classes of abnormalities exist class I agenesis/hypoplasia; class II, unicornuate uterus; class III, didelphys uterus; class IV bicornuate uterus; class V septate uterus; class VI arcuate uterus; and class VII diethylbestrol related anomalies. Class I is heterogenous, and includes vaginal, cervical, fundal, tubal, as well as combined agenesis as well as hypoplasia, class VI or arcuate uterus represents a specific case as though it is included in uterine anomaly, it is not correlated with any bad pregnancy results and might represent a normal variant [9].

Basic benefits of this AFS classification were uniformity of nomenclature regarding anomalies and simple representation of major morphologic kinds for practical utilisation for clinical doctors. This classification had been accepted universally for 3 decades and mostly used in the form of a global common language for describing mullerian anomalies in practice as well as research.

But the initial AFS classification possesses various limitations. The absence of strict morphometric criteria, with diagnosis of the abnormality done only on subjective basis in the absence of standardized diagnostic criteria [12]. Further proper uterine definition is missing [10,11]. Thus during the last 2 decades extra morphometric criteria were advocated for backing up the AFS classification [4,7,11,12], that were taken into account by the ASRM regarding recommendations on the indications as well as management of septate uterus [5].

Present criticism of this AFS classification was emphasized regarding European Society of Human Reproduction and Embryology (ESHRE)/European Society of Gynecological Endoscopy (ESGE) that lot of unique abnormalities exist which can't be classified in proper fashion [13]. Actually 140 unclassified cases were presented by ESHRE/ESGE group [14]. Inspire of that criticism, not much proof is there that a very elaborate classification system is required regarding clinical management like that of ESHRE/ESGE classification system.

Other AFS classification lacuna is that it only addresses mullerian abnormalities and is basically concentrated on the uterus. Hence as an alternative to this AFS classification, embryological clinical classification was advocated to collect all female genitourinary malformations as well as their, embryologic initiation [1,15]. A 2nd group detailed the Vagina, Uterus, Cervix, Adnexa as well as another associated Malformations (VCUAM) system getting stimulated by the tumor, nodes as well as metastases system in oncology [16]. These 2 systems, despite being really comprehensive, are complicated and not user friendly for clinicians, thus not used commonly.

ESHRE/ESGE classification system (2013, 2016)

ESHRE/ESGE published the classification of female genital tract abnormalities as the major classification for the Uterine body (U) as well as supplemental classification for the Cervix (C) as well as Vagina (V) [14]. Combining classes as well as subclasses gives us classification of 36 various Combinations of abnormalities. Fallopian Tubes are not taken into account for this classification system. There are 7 classes of regarding uterine: U0, normal uterus; U1, dysmorphic uterus; U2 septate uterus; U3, bicorporeal uterus; U4 hemiplastic uterus; U5, aplatic uterus U6, unclassified cases. Only 1 abnormality has the similar name got from the AFS system namely septate uterus. Compared to the AFS classification, where main basis of classification was subjective impression of the treating doctor regarding uterine abnormalities in ESHRE/ESGE classification system is on the basis of particular criteria that were decided by morphometric measurements, classifying main different uterine comparing particular factors of, like internal as well as external fundal indentations in relation to the uterine wall thickness, with like the normal as well as septate uterus. These diagnostic criteria were given by the committee without associating them with any clinical results [13]. A lot of studies point that ESHRE/ESGE criteria on the basis of uterine wall thickness as well as internal as well as external uterine abnormality can never be dependent [4,17,18], since the classification of usual abnormalities does not tell the variations in internal as well as external uterine wall deformity but only tells the variations in wall thickness among women [5,19]. The ESHRE/ESGE classification has got updated recently [20]. 2 definitions of uterine wall are advocated; the myometrium above the interstitial line (main definition) and the average of anterior as well as post uterine wall (alternative definition). Significant variations in wall thickness are there as per these 2 definitions, that cause diagnosis that is not consistent as well as reliable [19]. Moreover ESHRE/ESGE classification is totally dependent on imaging techniques with diagnostic endoscopy not having any place for diagnosis.

Biggest criticism emphasized by some independent experts is that the ESHRE/ESGE system might be utilized for promoting corrective surgery for benign uterine problems [4,19,21]. The studies point that the ESHRE/ESGE system need to eliminate uterine wall thickness with regard to deformity index, and thus classification needs to be improved markedly before it can be put to use in clinical practice. This was accepted by ESHRE/ESGE that their classification doesn't have to be used regarding surgical treatment, since it was made just from the point of cataloging objectives [22].

Other perplexing situation in ESHRE/ESGE system is definitions that overlap. Normal uterus, by definition is just the same like that of U1c, dysmorphic uterus with a graphic scheme of U1c uterus has not been given. Further one just can't differentiate a normal from dysmorphic T shaped uterus, in view of absence of any cutoffs for differentiating these conditions. Knowing these shortcomings

emphasized in this research, the aim of ESHRE/ESGE criteria for uterine abnormalities are not factual.

It appears that the basic benefit of the ESHRE/ESGE system is >elaboration of grouping of cervical as well as vaginal abnormalities as compared to AFS classification. But the thought of sub classification of these abnormalities is not innovative; it is quiet like old Jones classification [23], as well as the newer VCUAM classification [16]. Separately sub classification for cataloguing of rare as well as unique complex abnormalities is helpful. But still confusion by relating embryologic origin for interpreting cervical morphology like class of unilateral cervical aplasia [24,25].

Present ASRM classification regarding normal/arcuate/septate as well as bicornuate uterus

Various modifications of the initial AFS classification system, of these the initial modulation having measurable criteria for uterine abnormalities was given by Salim, et al. [26] that became very popular. Other modulation possessing particular morphometric criteria was advocated currently [4,7]. ASRM, following a systematic review of the literature in 2016, gave new precise definitions to separate the commonest morphologies as well as pointed that these definitions be utilized regarding management of patient [5]. As per the definitions pointed, normal as well as arcuate uterus get defined as a single class which apparently is reasonable seeing the results that we have as per the clinical effects of arcuate uterus. Definition of normal/arcuate uterus, is as per Salim et al. [26] (internal indentation angle >90), as well as for Normal uterus is based on Ludwin, et al. (internal indentation depth <1 cm) [4,6,7].

The basis of internal indentation depth <1 cm agrees with good obstetrical results in women with these morphologies following surgical correction [27]. Further a recent study demonstrated that women having arcuate uterus that by definition is the one having internal indentation angle >90 gave outcomes equivalent to those with straight or concave fundal contour of the uterine cavity [24]. Making the diagnosis made usually by subjective assessments made by big experts, the internal indentation depth <1 cm is believed to be normal/arcuate uterus without having any potential effect on reproductive results while most experts believe an internal indentation depth >1 cm to be septate uterus [23].

Little lacunae of this updated ASRM definitions of usual anomalies are there. Cutoffs were on the basis of a systematic review of literature and thus definitions are arbitrary, just like in the ESHRE/ESGE classification system. More challenge of making the whole AFS classification better is there.

Thus of all classifications which is best for patient management

As per the authors of the ESHRE/ESGE system the classification rendered by them gives a precise definitions of all usual anomalies, with those anomalies categorized as properly detailed classes as well as subclasses, with the ESHRE/ESGE criteria letting us classify the uterine morphology [22]. Yet studies have revealed that the criteria given by ESHRE/ESGE regarding major classes possess significant lacunae in methodology [4,18]. Researchers separately corroborated these methodologic lacunae which makes the diagnosis not to be confirmed [21]. Further the diagnosis of septate uterus on diagnosis using ESHRE/ESGE criteria doesn't correlate with poor reproductive outcomes [19,28]. At present 3 groups of workers have emphasized that the ESHRE/ESGE system tends to cause extra surgeries for

conditions which seem to be benign uterine variants as well as normal uterus [4,19], as well as risk of patients getting subjected to over therapy. Authors of ESHRE/ESGE system pointed that the system as well as their criteria included updated definitions and had not been made with the aim of patient management [20,22]. Recent systematic review points that present proof indicates that we should continue to use ASRM classification [29-33]. Thus this is a difficult query to answer regarding which system is better since both systems have their advantages as well as disadvantages. Both the systems are arbitrary, imperfect as well as incomplete having overlapping, confusing as well as non-objective criteria in the ESHRE/ESGE system with only partly improved ASRM system.

Definition by congenital uterine malformations by experts (CUME) 2018

Now it is thought that using various definitions in US as well as Europe would bring about lot of communication problems amongst practitioners, experts as well as researchers. The most lucrative definition is to have a single classification globally utilizing the maximum voted one by top independent expert's world over as a reference to get a language that is same regarding anomalies. Recently these unitedness of definitions, criteria as well as classifications were done by Congenital Uterine Malformations by Experts (CUME) group, as well as the 1st definition, that gives the diagnosis made by experts that normal/arcuate as well as septate uterus [21].

Proper Diagnostic Tests

Various potential 1 year helpful tests regarding screening, diagnosing as well as classification of congenital uterine malformations [2]. Basic evaluation of female genital tract anatomy in women of reproductive age is mostly done by using a gynae examination with the help of speculum as well as 2D Transvaginal Sonography (TVS). However these methods have limited sensitivity as well as specificity. Thus in a targeted group, other tests have been used by tradition. Earlier laparoscopy combined with hysteroscopy was thought to be the standard criterion in diagnosing as well as classification of congenital uterine malformations [6]. In the last decade, changes in use of particular methods have been seen regarding uterine anomalies [7,30]. Methods for diagnosis can be divided into those that can evaluate the total pelvis, i) uterus including the myometrium, ii) internal uterine structures as well as iii) communications among particular areas of female genital tract (USG, MRI, II) as well as those limited to uterine cavity (hysteroscopy, HSG) or pelvis as well as external structure of the Uterine cavity (laparoscopy). To evaluate the uterus, imaging methods which aid in reconstructing the coronal view of the uterine body are of help. For vaginal as well as cervix evaluation particularly in women having anatomic problems with perspeculum, right diagnosis might need vaginocopy or recently detailed sonovaginoscopy [31]. Diagnosis in children, girls as well as women having an intact hymen, as well as those with particular unique problems might be difficult and need to be individualized.

3D USG is noninvasive as well as supplemented with 3D sonohysterography [8]. Sonovaginoscopy aids in the maximum complicated as well as sophisticated evaluation of the female genital tract in one visit [32]. New methods like 3D sonohysterography as well as automatic volume estimation (sonohystero AVC), aid in giving newer ways of morphology evaluation as well as variations in uterine cavity volume, symmetry as well as deformity extent, as well as surgical anatomic outcomes [33]. More problems are there to form proof dependent Definitions and say what normal as well as

abnormal uterus is and to correlate the new measurable parameters with prognosis as well as patient management.

Surgery

Newer surgical ways for therapy of mullerian anomalies are getting evolved, with advancement of imaging noninvasive as well as >precise diagnosis of malformations has led to better planning of surgery with <diagnostic surgeries required. Further advancement of surgical equipment have aided in forming minimally invasive methods to rectify these malformations. Moreover earlier surgical methods for correction of mullerian anomalies meant excision or rectifying to give pain relief without bothering regarding future reproductive possibility. Currently patient's future reproductive ability as well as her individual preference is taken into account before deciding surgery.

Now use of 3D as well as Magnetic Resonance Imaging (MRI) has mostly replaced laparoscopy combined with hysteroscopy. Whereas USG has the benefit of being easy, as well as available it is suitable to make a differentiation of uterine anomalies, MRI remains the best imaging method as far as complicated mullerian anomalies are concerned in multiple planes and does not depend on user as far as imaging data retrieval is concerned. The crucial part of this imaging method is that a radiologist having experience as well as knowledge of interpreting these studies is there. It appears that using or acquisition of skills in conducting modern 3D USG as well as interpreting MRI by surgeons as well as clinicians is the most appropriate for managing malformations by a single expert who is dedicated.

Like in all surgical areas minimally invasive methods are utilized in surgery of mullerian anomalies. Using <invasive methods has also altered the approach of treatment, of these most significant change is the hysteroscopic incision of septum that has replaced the Jones [34], or Tompkins [35], metroplasty done by laparotomy [5]. This hysteroscopic septum incision is the same day outdoor (OPD) procedure not risking uterine rupture and aids in normal delivery as well as shorter recovery as compared to laparotomy [6]. Previously hysteroscopic septum incision was done under laparoscopic control, mainly in those patients having presence of fundal indentations for avoiding extra incision as well as fundal perforation. Right now, USG guidance, in later stages performed abdominally [36], with more recent transradially using 2D or 3D imaging as well as high resolution transducers have replaced more invasive laparoscopy [18,37]. If the procedure has good planning with 3D USG or sonohysterography, laparoscopy as well as USG guidance might not be required, mainly in patients having straight or concave external fundal contours. Other methods, like strass man metroplasty, have now been done through laparoscopy vs. robotic assisted laparoscopy instead of laparotomy [38]. Recovery is shorter as well as outcomes seem to be similar with this minimally invasive approach.

Uterine transplantation is a novel way for treatment of mullerian agenesis [39]. Getting the donor uterus has been done at laparotomy from a living or deceased donor. Originally uterus harvest regarding a live transplant needs a long as well as complex procedure of uterus removal along with its vascular supply without causing any undue trauma for the donor. Recently the 1st case of robotic assisted laparoscopic harvesting was detailed to obtain the uterus via a live donor [40]. The donor has a procedure akin to radical hysterectomy, with removal of ovaries for getting enough ovarian vascular pedicles, both arterial as well as venous, to allow perfusion of the uterus in the recipient. Since the robotic assisted laparoscopic method has become common in doing radical hysterectomy, it is natural that this same

method might get utilized for the uterus donor that helps in fast recovery.

Total way for a woman with a mullerian anomaly has got altered in the past few years to aid in better reproductive methods for the person as well as allowing her to take part in the decision making process which in the end has a repercussion on her life. Like, various mullerian anomalies can get treated using extirpated surgeries which are correlated with irreversible loss or affect reproduction in a negative way. Like hysterectomy for treating a patient having a high transverse septum or cervical agenesis, hemi hysterectomy as well as vaginectomy for obstructed hemiuterus in blind hemivagina as well as an amputation or ablation surgery of the blind obstructed hemi cavity in Robert septate uterus (Figure 1) [25,41]. Alternate methods are now available for every one of these abnormalities which sees to it that reproduction is preserved. Since these patients classically present during adolescence, they might not be mature enough for taking a decision as far as the treatment method that is proper for them in short as well as long term results. Minimally invasive methods for postponing definitive surgery can be utilized, like aspiration of hematocolpos or hematometra in combination with consequent hormonal repression of menstruation using hormonal contraception, progestin's as well as GnRH agonists (Figures 2-4) [42]. These methods have been utilized to postpone surgery and let the patient mature so that she can participate in her own decision taking properly at a later time.

With ART advent many patients having h/o obstructive mullerian anomalies have been aided in conceiving. With IVF patients having h/o adhesions as well as previous salpingectomy in view of retrograde menstruation, endometriosis as well as adhesive disease. Pregnancies have got using transmyometrial transfer of embryos in case of cervical agenesis [43-45].

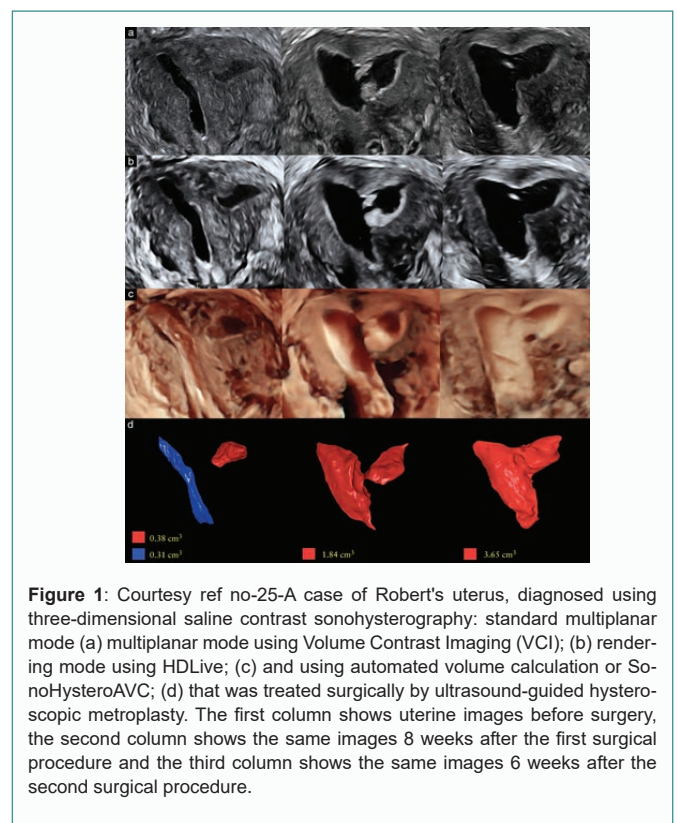


Figure 1: Courtesy ref no-25-A case of Robert's uterus, diagnosed using three-dimensional saline contrast sonohysterography: standard multiplanar mode (a) multiplanar mode using Volume Contrast Imaging (VCI); (b) rendering mode using HDLive; (c) and using automated volume calculation or SonoHysteroAVC; (d) that was treated surgically by ultrasound-guided hysteroscopic metroplasty. The first column shows uterine images before surgery, the second column shows the same images 8 weeks after the first surgical procedure and the third column shows the same images 6 weeks after the second surgical procedure.

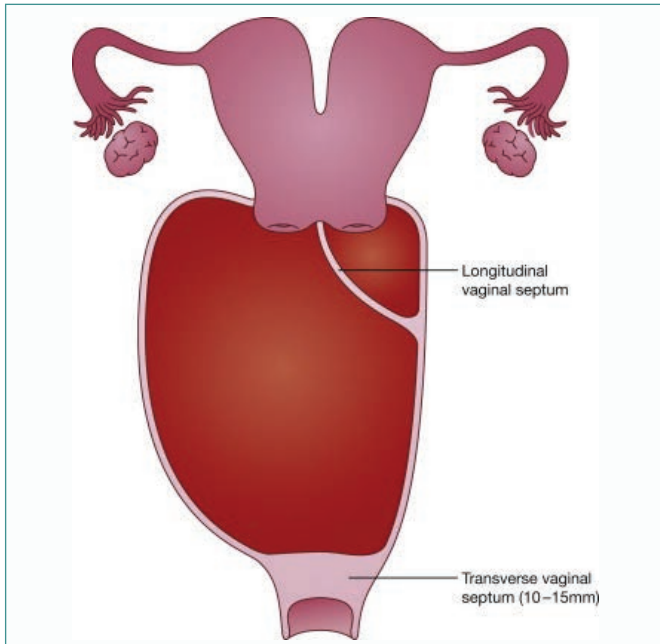


Figure 2: Courtesy ref no-42 Schematic representation of magnetic resonance imaging findings, case 1.

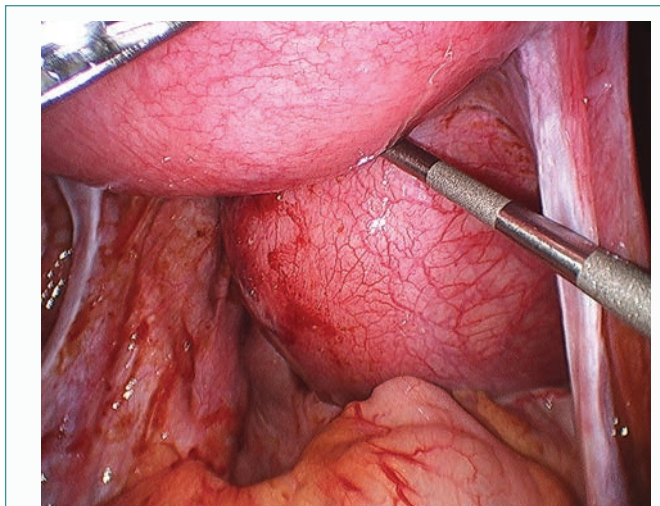


Figure 3: Courtesy ref -42-Laparoscopic view of hematocolpos, -a case of turners syndrome with transverse vaginal septum.

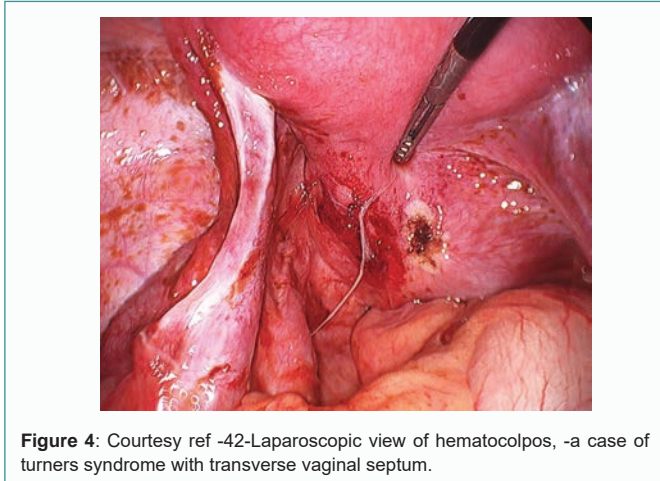


Figure 4: Courtesy ref -42-Laparoscopic view of hematocolpos, -a case of turners syndrome with transverse vaginal septum.

Controversial cases

Utero vaginal anastomosis for cervical agenesis: Initially cervical agenesis had been treated by doing a Total Abdominal Hysterectomy (TAH) mainly for relief of pain in view of hematometra developing with consequences of retrograde menstruation, along with endometriosis like, hematosalpinx, endometriomas. Initial case series studying outcomes of utero vaginal fistula, demonstrated poor outcomes. Incidence of those having reoperation as well as consequent hysterectomy in those having utero vaginal reconstruction varied from 10% to >50% with various deaths reported by sepsis (Figures 5 and 6) [46,47]. In those where both cervical agenesis as well as vaginal agenesis were present had >possibility of failing. Although pregnancies have been reported following utero vaginal anastomosis [46], incidence was very less, most probably in view of high chance of tubal damage as well as adhesive disease secondary to retrograde menstruation. The risk of reoperation as well as death chances via reconstructive surgery have made many to recommend hysterectomy as the treatment of choice in such patients. But the case series that have been documented more currently using Utero Vaginal Anastomosis for cervical agenesis as well as dysgenesis have shown marked success even on combining with creating a neovagina [48-51]. In a single study comprising of 18 cases, all of the women had successful reconstruction with just one woman having restenosis that was treated that was successfully treated utilizing canalization [48]. In 10 women pregnancy took place without any external aid, while 4 more women had a successful delivery through LSCS at 36 weeks to 38 weeks. Another case series of laparoscopically assisted utero vaginal anastomosis in 14 patients, 9 had vaginoplasty as well [51]. Only 1 patient had hysterectomy due to restenosis as well as infection. Unassisted pregnancy was got in 3/5 patients who had sexual activity. 1 delivered at term, 1 had intrauterine death at 21 weeks, and the other was 22 weeks at the time this was published.

These good results in these studies have queried which management is the proper one. Though hysterectomy is safer option since it avoids potential complications of restenosis, infection as well as death, it does not let the woman preserve her uterus for cultural or

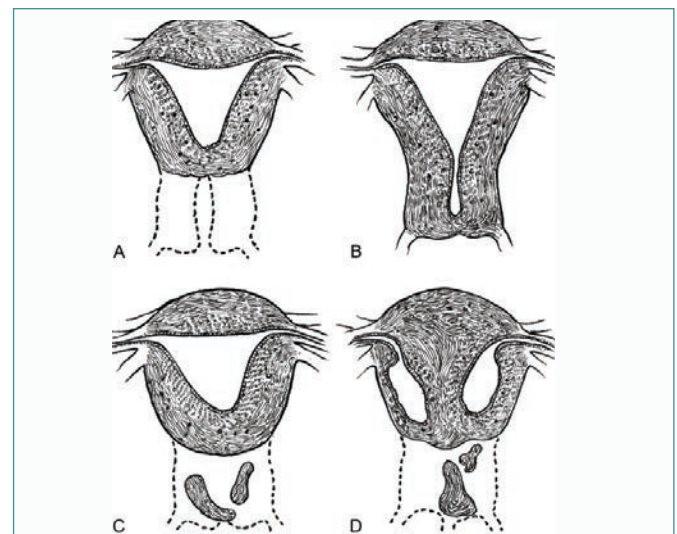


Figure 5: Courtesy ref no-46, (A) The fundus of the uterus is noted without a cervix; (B) The cervical body is intact with obstruction of the cervical os; (C, D) Fragmentation of the cervix in which portions of the cervix is noted with no connection of the uterine body. In one patient, hypoplasia of the uterine cavity was noted and Reproduced with permission.

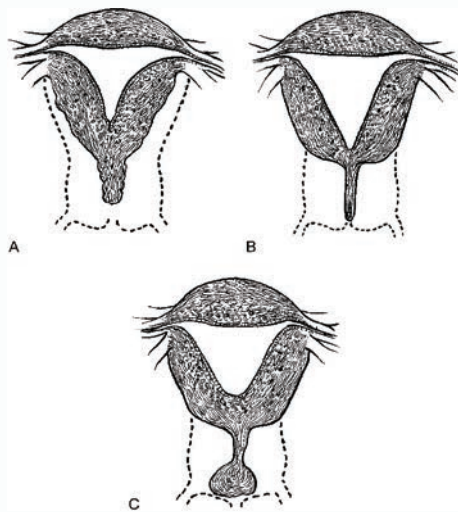


Figure 6: Courtesy ref no-46, the cervical body consists of a fibrous band of variable length and diameter that can contain endocervical glands. Variable portions of the endocervical lumen are obliterated. In C, a stricture is noted of the midportion of the cervix, which is hypoplastic with a bulbous tip. No endocervical lumen is identified and Reproduced with permission.

emotional reasons or to carry a conception. Further surrogacy is not an answer for many persons due to cultural factors or laws banning or restricting the procedure all over the world like parts of US also [51-61]. Decision of reconstructive surgery should be done on basis of several factors like culture and patient's wishes, size of uterus, potential of uterus to carry a pregnancy, surgeons skill as well as experience as well as availability of Assisted Reproductive Technology (ART), all weighed against risk of side effects.

Septate uterus surgery - as per various definitions: In this field of mullerian anomalies, septate uterus is a topic having lot of controversies. Reason behind this is the definition of a septate uterus and if there is improvement in clinical results. Further There are various definitions of a septate uterus as per ESHRE/ESGE and ASRM classification systems [5,12,21]. ESHRE/ESGE classification might tend to over diagnose septate uterus, ending in >metroplasties [6,21]. 44 cases of septate uterus diagnosed by ESHRE/ESGE classification systems were compared. The median internal indentation in the ones diagnosed by ESHRE/ESGE criteria was 10.7 mm (lower upper quarterile 18.8 mm to 33.1 mm) [5]. Moreover, in 16/44 (36%) internal indentation was <1 cm and agreed with the ASRM criteria for normal/arcuate uterus [5]. Utilizing the updated 2016 ESHRE/ESGE definition of a septate uterus in reevaluation of same sample, septate uterus was observed in 80 cases (31%) as compared to the above quoted 44 (17%) cases utilizing the earlier ESHRE/ESGE definition; using the new definition the internal indentation was mostly <0.5 cm [53]. Though septate uterus resection is commonly advocated for avoiding poor reproductive performance [5], this recommendation was based on poor quality data and most of studies utilized criteria separate from ESHRE/ESGE classification. Knowing the overall small sample size of septa utilizing this classification system and data that points that a septum of <1 cm is not correlated with poor clinical results [27], >surgeries might be done without any definite clinical advantage [19]. RCT are being performed at present for analyzing results after septate uterus treatment *via*. expectant management [54]. Still >studies are required to find if surgery of a uterine septum defined by either of the criteria's is beneficial as regards clinical performance.

Cervical septum for preservation or resection: Treatment of complete septate uterus by hysteroscopy might need preservation of cervical septum or resection. 1 randomized study did a comparison of surgery of septate uterus with as well as without cervical septum resection in 28 patients [55]. In the group that had preservation of the cervical septum, time taken to operate were longer, incidence of bleeding >150 ml with >Lower Segment Caesarean Section (LSCS) rate as compared to those who had cervical septum incision. No differences were there as far as reproductive performance was concerned among the 2 groups. But another group showed cerclage was required for 5/22 patients due to cervical shortening with removal of cervical septum [56]. But these studies did not separate PTs on the basis of size of cervical septum. Usually interstitial cases of septate as well as double cervix (wide septa or septate/double cervix) are there, and strict separation of these 2 problems might be challenging and sometimes impossible. 2 cervixes (double cervix) with intracervical cleft between different cervixes might be there in class V [3,57]. In these cases metroplasty just limited to uterine body needs to be taken into account rather than surgical cervical unification. More data as well as proper anatomical classification as well as characteristics of cervical morphology are required for guiding proper treatment.

Blind hemivagina: Double uterus with obstructed hemivagina is a well, recognized abnormality of the mullerian system [58]. This abnormality is also referred to as Herlyn, Werner and Wunderlich syndrome [59,60]. This kind of obstructed hemivagina is seen usually correlated with complete septate uterus or didelphys uterus and occasionally with bicornuate uterus having double uterine cavity as well cervical canal [41,55]. Multiple treatment modalities have been offered. Mostly a vaginal approach has been utilized for resecting a vaginal septum, thus relieving the obstruction and aiding in a single common vaginal canal [59,61,62]. But hysteroscopic resection has also been tried for resecting a vaginal septum, in a virginal PT when hymen preservation is needed [63-65]. Hemi hysterectomy of the obstructed side as well as ipsilateral vaginectomy has been offered as another form of management. But the method should be kept for cases where obstructed hemivagina is very high, and thus vaginoplasty is not possible. The obstructed hemiuterus is functional following vaginoplasty, with 36% of pregnancies taking place in earlier obstructed side [61]. A triad of cystic pelvic tumor, contralateral renal agenesis or anomaly, and uterine anomaly with uterine cavity a cervical canal division needs to be taken into account as proposed for evaluation of Blind hemivagina for preventing unnecessary abdominal or amputative surgery during adolescence [65-70].

Conclusion with Future Challenges as well as Studies Still Getting Conducted

Despite many advances in diagnosis, classifications as well surgery getting detailed as well as utilized clinically in last decade, still few basic queries are answered as per the basic principles of evidence dependent medicine. The absence of strong evidence aided particular management is well clear and remains a challenge to guide even for clear cut mullerian abnormalities.

Studies of good quality on prevalence as well as clinical effects having criteria than can be measured, are needed for differential diagnosis of normal as well as abnormal problems. Studies concentrated on obvious morphologies, like normal as well as arcuate uterus, septate, bicornuate as well as uterus didelphys as well as other debatable problems like T shaped uterus, using criteria that are measurable criteria to diagnose need to be done in an

unselected nonmedical population using proper diagnostic tests (like 3D ultrasound). These observational studies without any surgical interventions would aid in developing insight regarding baseline prognosis.

Doing surgical studies without proper control groups in obvious abnormalities make most studies not appropriate. Surgery in women having infertility as well as recurrent pregnancy loss and having potentially benign morphologic anomalies of uterus might display good reproductive performance following correction. Despite that, this is not enough proof to decide that surgery is actually of help for these women. Since many women with earlier reproductive failures have a possibility of getting a spontaneous pregnancy as well as live birth, it is a problem to decide any benefit of a surgical intervention on reproductive outcome in that population, studies without control group of untreated women might give a wrong practice.

Randomized Controlled Trials (RCT's) also might get false outcomes if methods are not sound or criteria that are not reliable get utilized for surgical qualifications. Right now 2 RCT's are ongoing that are concentrated on septate uterus. The protocols ask queries about the definitions how valid are they regarding defining septate uterus. The first of this study started 10 years back and will end fast. Going through the protocol points that most essential drawback of this trial are the definitions utilized for septate uterus as well as imperfect diagnostic methodology. The diagnostic criteria for this study for septate uterus were ESHRE/ESGE, though the criteria got altered at the time of study and were not too standardized.

Conversely doing RCT's in women possessing unique abnormalities is not simple and impossible sometimes. The most potential women that are eligible for the trial refuse to get randomly assigned for intervention or expectant management, mainly if data from even typically biased studies point that the intervention might enhance fertility as well as avoid miscarriages. One of the best solutions might be to open a registry that should include datasets from accurate diagnosed methods like 3D USG as well as MRI, which can get reliably evaluated. Universally accepted classification as well as measurable evidence dependent definitions as well as criteria of normal conditions as well as mullerian anomalies should be accepted with wide global consensus.

References

- Acien P, Acien MI. The history of female genital tract Malformations Classifications and proposal of an updated system. *Hum Reprod Update*. 2011;17(5):693-705.
- Chan YY, Jayaprasakan K, Zamora J, Thornton JG, Raine-Fenning N, Coomaraswamy A. The prevalence of Congenital Uterine anomalies in unselected and high risk populations: a systematic review. *Hum Reprod Update*. 2011;17(6):761-71.
- Buttram VC. Mullerian anomalies and their management. *Fertil Steril*. 1983;40(2):159-63.
- Ludwin A, Ludwin I. Comparison of the ESHRE/ESGE and ASRM Classification of Mullerian duct anomalies in everyday practice. *Hum Reprod*. 2015;30(3):569-80.
- Practice Committee of the American society of reproductive Medicine. Uterine septum: a guideline. *Fertil Steril*. 2016;106(3):530-40.
- Ludwin A, Ludwin I, Banas T, Knafel A, Miedzyblocki M, Basta A. Diagnostic accuracy of sonohysterography, hysterosalpingography and diagnostic hysteroscopy in diagnosis of arcuate, septate, and bicornuate uterus. *J Obstet Gynaecol Res*. 2011;37(3):178-86.
- Ludwin A, Pitynski K, Ludwin I, Banas T, Knafel A. Two and three dimensional ultrasonography and sonohysterography versus hysteroscopy with laparoscopy in the differential diagnosis of septate, bicornuate and arcuate uteri. *J Minim Invasive Gynaecol*. 2013;20(1):90-9.
- Buttram VC, Gibbons WE. Mullerian anomalies: A proposed Classification (an analysis of 144 cases). *Fertil Steril*. 1979;32(1):40-6.
- American Fertility Society. The American Fertility Society Classification of adnexal adhesions, distal tubal occlusion, tubal occlusion secondary to tubal ligation, tubal pregnancies, Mullerian anomalies and intrauterine adhesions. *Fertil Steril*. 1988;49(6):944-55.
- Woelfer B, Salim R, Banerjee S, Elson J, Regan L, Jurkovic D. Reproductive outcomes in women with Congenital Uterine anomalies detected by three dimensional ultrasound screening. *Obstet Gynecol*. 2001;98(6):1099-103.
- Salim R, Regan L, Woelfer B, Backos M, Jurkovic D. A comparative study of the morphology of Congenital Uterine anomalies in women with and without a history of recurrent first trimester miscarriage. *Hum Reprod*. 2003;18(1):162-6.
- Ludwin A, Ludwin I, Kudia M, Kottner J. Reliability of the European society of human reproduction and embryology European society of Gynaecological Endoscopy and American society of reproductive Medicine Classification system for Congenital Uterine anomalies detected using three dimensional ultrasonography. *Fertil Steril*. 2015;104(3):688-97.e8.
- Grimbizis GF, Gordts S, Di SpiezioSardo A, Bucker S, De Angelis C, Gergolet M, et al. The ESHRE/ESGE consensus on the Classification of female genital tract anomalies. *Hum Reprod*. 2013;28(8):2032-44.
- Di Spiezio Sardo A, Campo R, Gordts S, Spinelli M, Cosimato C, Tanos V, et al. The comprehensiveness of the ESHRE/ESGE Classification of female genital tract Congenital anomalies: a systematic review of cases not classified in the AFS system. *Hum Reprod*. 2015;30(5):1046-58.
- Acien P. Embryological observations on the female genital tract. *Hum Reprod*. 1992;7(4):437-45.
- Oppelt P, Renner SP, Brucker S, Strissel PL, Strick R, Oppelt PG, et al. The VCUAM (vagina, uterus, cervix, adnexa- associated malformations) Classification: a new Classification for genital malformations. *Fertil Steril*. 2005;84(5):1493-7.
- Ludwin A, Ludwin I, Pitynski K, Banas T, Jach R. Role of morphologic characteristics of the Uterine septum in the prediction and prevention of abnormal healing outcomes after hysteroscopic metroplasty. *Hum Reprod*. 2014;29(7):1420-31.
- Ludwin A, Martins WP, Bhagavath B, Lindheim SR. Overdiagnosis, over detection and over definition of the ASRM and ESHRE/ESGE criteria is urgently needed. *Fertil Steril*. 2019;112(3):448-9.
- Knez J, Sandogan E, Van Den Bosch T, Mavrelou D, Amber G, Jurkovic D. ESHRE/ESGE female genital tract anomalies classification system-the potential impact of discarding arcuate uterus on clinical practice. *Hum Reprod*. 2018;33(4):600-6.
- Grimbizis GF, Di Spiezio Sardo A, Saravelos SH, Gordts S, Exacoustos C, Van Shoubroek D, et al. The Thessaloniki ESHRE/ESGE consensus on diagnosis of female genital tract anomalies. *Hum Reprod*. 2016;13:1-16.
- Ludwin A, Martins WP, Nastri CO, Ludwin I, Coelho-Neto MA, Leitao VM, et al. Congenital Uterine Malformations by Experts (CUME): better criteria for distinguishing between normal/arcuate and septate uterus? *Ultrasound Obstet Gynecol*. 2018;51(1):101-9.
- Grimbizis GF, Gordts S, Di Spiezio Sardo A, Bucker S, De Angelis C, Gergolet M, et al. Reply: are the ESHRE/ESGE criteria of female genital anomalies for diagnosis of septate uterus appropriate? *Hum Reprod*. 2014;29(4):868-9.
- Jones HW, Jones GE. Double uterus as an etiological factor in repeated abortion: indication for surgical repair. *Am J Obstet Gynecol*. 1953;65(2):325-39.
- Acien P, Acien M. The presentation and management of complex female genital tract Malformations. *Hum Reprod Update*. 2016;22(1):48-69.
- Ludwin A, Ludwin I, Martins WP. Robert's uterus: modern imaging techniques and ultrasound - guided hysteroscopic treatment without laparoscopy or laparotomy. *Ultrasound Obstet Gynecol*. 2016;48(4):526-9.
- Salim R, Woelfer B, Backos M, Regan L, Jurkovic D. Reproducibility of three dimensional ultrasound diagnosis of Congenital Uterine anomalies. *Ultrasound Obstet Gynecol*. 2003;21(6):578-82.

27. Fedele L, Biachi S, Marchini M, Mezzopane R, DiNola G, Tozzi L. Residual Uterine septum of less than 1cm after hysteroscopic metroplasty does not impair reproductive outcome. *Hum Reprod.* 1996;11(4):727-9.
28. Ludwin A, Martins WP, Nastri CO, Ludwin I. Septate uterus by ESHRE/ESGE and ASRM Classification: association with infertility and previous miscarriage. *Int Soc Ultrasound Obstet Gynecol.* 2017.
29. Bhagvath B, Elle G, Griffiths KM, Winter K, Alur Gupta S, Richardson C, et al. Uterine Malformations:an update of diagnosis, management, and outcomes. *Obstet Gynaecol Surv.* 2017;72(6):377-92.
30. Ludwin A, Ludwin I, Kudla M, Pitynski K, Banas T, Jach R, et al. Diagnostic accuracy of three dimensional sonohysterography compared with office hysteroscopy and its interpreter/intrarater agreement in uterine cavity assessment after hysteroscopic metroplasty. *Fertil Steril.* 2014;101(5):1392-9.
31. Ludwin A, Martins WP, Ludwin I. Three dimensional saline-contrast sonovaginoscopy or virtual speculscopy with HD live: potential diagnostic tool for women with intact hymen or uterovaginoscopy complex malformations. *Ultrasound Obstet Gynaecol.* 2017;50(5):669-71.
32. Groszmann YS, Benacerraf BR. Complete evaluation of anatomy and morphology of the infertile patient in a single visit: the modern infertility pelvic Ultrasound examination. *Fertil Steril.* 2016;105(6):1381-93.
33. Ludwin A, Martins WP, Ludwin I. Uterine cavity imaging, volume estimation and quantification of degree of deformity using automatic volume calculator: description of technique. *Ultrasound Obstet Gynecol.* 2017;50(1):138-40.
34. Muasher SJ, Acosta AA, Garcia JE, Rosenwalks Z, Jones HW. Wedge metroplasty for the septate uterus:an update. *Fertil Steril.* 1984;42(4):515-9.
35. McShane PM, Reilly RJ, Schiff I. Pregnancy outcomes following Tompkins metroplasty. *Fertil Steril.* 1983;40(2):190-4.
36. Quercleu D, Brasme TL, Parmentier D. Ultrasound guided transcervical metroplasty: feasibility and safety. *Fertil Steril.* 1990;54(6):995-8.
37. Ghirardi V, Bizzarri N, Remorgida V, Venturini PL, Ferrero S. Intraoperative transrectal ultrasonography for hysteroscopic metroplasty: feasibility and safety. *J Minim Invasive Gynecol.* 2015;22(5):884-8.
38. Alborzi S, Asefjah H, Amini M, Vafael H, Madadi G, Chubak N, et al. Laparoscopic metroplasty in bicornuate and didelphic uteri: feasibility and outcome. *Arch Gynaecol Obstet.* 2015;291(5):1167-71.
39. Branstrom M. Womb transplants with live births: an update and the future. *Expert Opin Biol Ther.* 2017;17(9):1105-12.
40. Wei L, Xue T, Tao KS, Zhang G, Zhao GY, Yu SQ, et al. Modified human uterus transplantation using ovarian veins for venous drainage: the first report of surgically successful robotic assisted uterus procurement and follow up after 12mths. *Fertil Steril.* 2017;108(2):346-56.
41. Ludwin A, Ludwin I, Bhagvath B, Lindheim SR. Pre, intra and postoperative management of Robert 's uterus. *Fertil Steril.* 2018;110(4):778-9.
42. Dennie J, Pillay S, Watson D, Grover S. Laparoscopic drainage of hematocolpos: a new treatment option for the acute management of a transverse vaginal septum. *Fertil Steril.* 2010;94(5):1853-7.
43. Xu C, Xu J, Gao H, Huang H. Triplet pregnancy and successful twin delivery in a patient with Congenital cervical atresia who underwent transmyometrial embryos transfer and multifetal pregnancy reduction. *Fertil Steril.* 2009;91(5):e1-3.
44. Anttila L, Pnttila TA, Suikkari AM. Successful pregnancy after in vitro fertilization and transmyometrial embryos transfer in a patient with congenital atresia of cervix. *Hum Reprod.* 1999;14(6):1647-9.
45. Lai T, Wu M, Hung K, Cheng Y, Chang F. Succesful pregnancy by transmyometrial and transtubal embryos transfer after IVF in a who Congenital cervical atresia who underwent uterovaginal canalization during caesarean section. *Hum Reprod.* 2001;16(2):268-71.
46. Rock JA, Roberts CP, Jones HW. Congenital anomalies of the Uterine cervix:lessons learnt from 30 cases managed by clinical protocol. *Fertil Steril.* 2010;94(5):1858-63.
47. Casey CA, Laufer MR. Cervical agenesis: septic death after surgery. *Obstet Gynecol.* 1997;90(4):706-7.
48. Deffaeges JV, Haddad I, Musset R, Paniel BJ. UteroVaginal Anastamosis in women with Uterine cervical atresia: longterm follow up and reproductive performance. A study of 18 cases. *Hum Reprod.* 2001;16(8):1772-5.
49. Rock JA, Schlaff WD, Zacur HA, Jones HW. The clinical management of congenital absence of theuterine cervix. *Int J Gynecol Obstet.* 1984;22(3):231-5.
50. Rock JA, Breech LL. Surgery for anomalies of the mullerian ducts. In: Rock JA and Jones HW, editors. *Telinde's operative gynecology.* 10th ed. Philadelphia: Lippincott Williams & Wilkins; 2008.
51. Kriplani A, Kacchawa G, Awasthi D, Kulshereetha V. Laparoscopic-assisted Utero Vaginal Anastamosis in Congenital atresia of the uterine cervix: follow up study. *J Minim Invasive Gynecol.* 2012;19(4):477-84.
52. Soderstrom-Anttila V, Wennerholm UB, Loft A, Pinborg A, Attornaki K, Romundstad LB, et al. Surrogacy outcomes of surrogate mothers, children and the resulting families-a systematic review. *Hum Reprod Update.* 2016;22(2):260-76.
53. Ludwin A, Ludwin I, Coelho-Neto MA, Nastri CO, Bhagvath B, Lindheim SR, et al. Septate uterus by updated ESHRE/ESGE ASRM and CUME Definitions: association with infertility previous miscarriage and warnings for women and health care systems, and associated cost analysis. *Ultrasound Obstet Gynecol.* 2019;54(6):800-14.
54. Rikken JFW, Kowalik CR, Emanuel MH, Bongers MY, Spinder T, De Kruif JH, et al. The randomized uterine septum transaction trial (TRUST) design and protocol. *BMC Womens Health.* 2018;18(1):163.
55. Parsanezhad ME, Alborzi S, Zarei A, Dehbashi S, Shirazi LG, Rajeeferd A, et al. Hysteroscopic metroplasty of the complete uterine septum, duplicate cervix and vaginal septum. *Fertil Steril.* 2006;85(5):1473-7.
56. Grynberg M, Gervasis A, Faivre E, Deffieux X, Frydman R, Fernandez H. Treatment of twenty two patients with complete uterine and vaginal septum. *J Minim Invasive Gynecol.* 2012;19(1):34-9.
57. Smith BC, Brown DL, Carter RE, Famuyide AD. Double cervix: clarifying diagnostic dilemma. *Am J Obstet Gynecol.* 2014;211(1):26.e1-5.
58. Fedele L, Motta F, Frontino G, Restelli E, Biachi S. Double uterus with Obstructed hemivagina and ipsilateral renal agenesis: pelvic anatomic variants in 87 cases. *Hum Reprod.* 2013;28(6):1580-3.
59. Smith NA, Laufer MR. Obstructed hemivagina and ipsilateral renal anomaly (OHVIRA) syndrome: management and followup. *Fertil Steril.* 2007;87(4):918-22.
60. Tong J, Zhu L, Lang J. Clinical characteristics of 70 patients with Herlyn-Werner-Wunderlich syndrome. *Int J Gynecol Obstet.* 2013;121(2):173-5.
61. Haddad B, Barranger E, Paniel BJ. Blind hemivagina: longterm follow up and reproductive performance in 42 cases. *Hum Reprod.* 1999;14(8):1962-4.
62. Candiani GB, Fedele L, Candiani M. Double uterus, Blind hemivagina and ipsilateral renal agenesis:36 cases and longterm follow up. *Obstet Gynecol.* 1997;90(1):26-32.
63. Tsai EM, Chiang PH, Hsu SC, Su JH, Lee JN. Hysteroscopic resection of vaginal septum in an adolescent virgin with Obstructed hemivagina. *Hum Reprod.* 1998;13(6):1500-1.
64. Kim TE, Lee GH, Choi YM, Jee BC, Ku SY, Suh CS, et al. Hysteroscopic resection of the vaginal septum in uterus didelphys with obstructed hemivagina: a case report. *J Korean Med Sci.* 2007;22(4):766-9.
65. Ludwin A, Ludwin I, Bhagvath B, Martins WP, Lindheim SR. Virginitiy-sparing management of Blind hemivagina in Obstructed hemivagina and ipsilateral renal anomaly syndrome. *Fertil Steril.* 2018;110(5):976-8.
66. Christiansen OB, Nybo Andersen AM, Bosch E, Daya S, Delves PJ, Hviid T, et al. Evidence based investigations and treatments of recurrent pregnancy loss. *Fertil Steril.* 2005;83(4):821-39.
67. Kowalik CR, Goodijn M, Emanuel MH, Bongers MY, Spinder T, De Kruif JH, et al. Metroplasty versus expectant management for women with recurrent miscarriage and a septate uterus. *Cochrane Database Sys Rev.* 2011;115(6):CD008576.

68. Rikken JF, Kowalik CR, Emanuel MH, Mol BW, Van der Veen F, van Wely M, et al. Septum resection for women of reproductive age with a septate uterus. *Cochrane Database Sys Rev.* 2017;1:CD008576.
69. Saravelos SH, Cocksedge KA, Li TC. Prevalence and diagnosis of Congenital Uterine anomalies in women with reproductive failure: a critical appraisal. *Hum Reprod Update.* 2008;14(5):415-29.
70. Prior M, Richardson A, Asif S, Polanski L, Parris-Larkin M, Chandler J, et al. Outcome of assisted reproduction in women with congenital uterine anomalies: a prospective observational study. *Ultrasound Obstet Gynecol.* 2018;51(1):110-7.