

Case Report

Anal Mucinous Adenocarcinoma Secondary to Chronic Anorectal Fistulae: A Case Report with Review of the Literature

Ibrahim AH¹, Almusayb MF², Alghazwi AA² and Alkhalidi MS²

¹Department of General Surgery, King Fahd University Hospital, Dammam, Saudi Arabia

²Department of General Surgery, Dammam Medical Complex, Dammam, Saudi Arabia

Abstract

Introduction: Perianal fistula is a common clinical condition that is caused mainly by abscess formation of the anal glands or as a side effect of surgical intervention. Anal mucinous adenocarcinoma associated with chronic anal fistula is an uncommon condition.

Case report: Here, we report a case of a 59-year-old male following in clinic as a case of persistent perianal discharge post incision and drainage of perianal abscess seven months ago. Examination revealed a soft, non-tender abdomen; rectal exam showed induration involving the perianal area from 3-5 o'clock, the external opening of perianal fistula at 3 o'clock, with active discharge, MRI pelvis showed a 7.3 × 8.1 × 10.4 cm perianal U-shaped fairly well-demarcated mass lesion. Image-guided biopsy was taken, and the histopathology showed low-grade peritoneal mucinous neoplasia.

Discussion: The mucinous adenocarcinoma is a rare malignancy accounting for only 3% - 11% of anal cancer; its association with perianal fistula is infrequent; Rosser first described that. The condition can be easily misdiagnosed with benign conditions (perianal fistula/abscess).

Conclusion: Chronic perianal fistula could represent a serious underlying condition such as perianal adenocarcinoma. Thus, a high clinical suspicion index is required to reach the diagnosis.

Keywords: Perianal Fistula; Mucinous Adenocarcinoma

Introduction

Perianal fistula is a common clinical condition that is mostly caused by abscess formation of the anal glands or as a side effect of its surgical intervention (incision and drainage) [1]. However, chronic non-healing fistula in old age patients can indicate a serious condition like malignancy, withier primary as rectal or anal adenocarcinoma or secondary spread of intra-abdominal origin [2]. Anal carcinoma is a rare malignant entity that accounts for 2% - 3% of all large bowel cancer [3]. Here we report a case of anal mucinous carcinoma in a patient with a perianal fistula. This work has been reported in line with the SCARE 2020 criteria [4].

Case Presentation

A 59 years olds male was followed in the outpatient clinic for a case of persistent perianal discharge associated with on/off anal discomfort that started seven months back post-incision and drainage of perianal abscess. The patient denied a history of perianal swelling, per rectal bleeding, fever, and night sweats. He had a past

surgical history of hemorrhoidectomy 20 years ago and controlled diabetes mellitus as a medical background. On examination, a thin gentleman's vital signs were within normal limits. Abdominal exam: soft, non-tender abdomen; rectal exam showed induration involving perianal area from 3-5 o'clock, external opening of perianal fistula at 3 o'clock, with active discharge. Laboratory investigations (complete blood count, Renal panel, liver function test, coagulation profile, and RBS) were unremarkable.

MRI pelvis showed a 7.3 × 8.1 × 10.4 cm (Figure 1) perianal U-shaped fairly well-demarcated mass lesion with minimal surrounding inflammatory changes involving the ischioanal fossae, which is encircling the anal canal from 2 to 10 O'clock and extending superiorly to mesorectal fat. It displays a low T1 signal intensity, intensely high T2 signal intensity, internal low T2 mesh-like septation/content, and low T2 rim with a progressive internal enhancement on post-contrast images. The lesion is communicating with the anal canal (internal opening) at the 3 o'clock position and has an external opening at the left natal cleft. It abuts the lower sacral bones and bilateral obturator internus muscles and causes mass-effect on the anal canal, lower rectum, and prostate with no definite invasion. A few prominent inguinal lymph nodes with a mildly enlarged lymph node are seen in the left inguinal region, measuring 1.1 cm in the short axis. There is a very low-lying simple trans sphincteric fibrotic perianal fistula with an internal opening at the 3 o'clock position and an external opening at the left natal cleft.

Further assessment with colonoscopy revealed an internal opening of the anal fistula with discharge and external compression along the distal part of the rectum seen on retroflexion; the reaming of the study was unremarkable. A decision was made for image-guided

Citation: Ibrahim AH, Almusayb MF, Alghazwi AA, Alkhalidi MS. Anal Mucinous Adenocarcinoma Secondary to Chronic Anorectal Fistulae: A Case Report with Review of the Literature. Am J Surg Case Rep. 2024;5(9):1151.

Copyright: © 2024 Arwa Hanafie Ibrahim

Publisher Name: Medtext Publications LLC

Manuscript compiled: Dec 02nd, 2024

***Corresponding author:** Arwa Hanafie Ibrahim, Department of General Surgery, King Fahd University Hospital, Dammam, Saudi Arabia

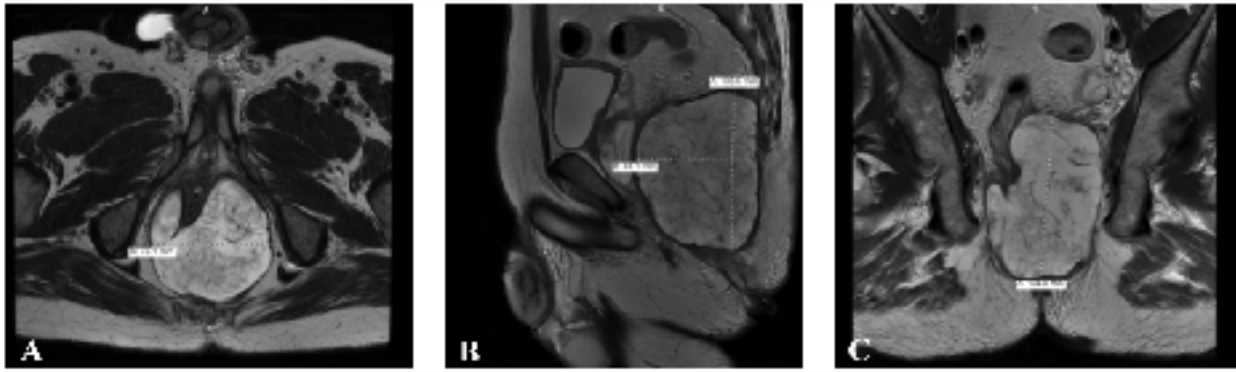


Figure 1: Showing different view of perianal mass in pelvic MRI.

biopsy; the histopathology came as low-grade peritoneal mucinous neoplasia. Based on histopathology, the patient was referred to the oncology center for further evaluation and management.

Discussion

Rosser first reported perianal mucinous adenocarcinoma arising from anorectal fistula in 1934; he described the criteria for diagnosis area:

1. The fistula should antedate the carcinoma by a minimum of ten years.
2. The tumor present in the rectum or anal canal should be due to direct extension from carcinoma in the fistula.
3. The internal opening of the fistula should be into the anal canal and not into the tumor [5]. The two later criteria were fulfilled in our case.

The mucinous adenocarcinoma is a rare malignancy accounting for only 3% - 11% of anal cancer; moreover, its association with perianal fistula is infrequent, with few cases being reported in the literature [6].

The pathophysiology is believed to be dysplasia secondary to chronic inflammation, seen in chronic fistula with recurrent infection or the presence of Inflammatory Bowel Disease (IBD), which is considered a risk factor [7-9]. Additionally, advanced age and male gender have higher rates of disease.

Perianal discharge or discomfort are the common symptoms of clinical presentation that are nonspecific and can easily misdiagnosed with benign conditions (perianal fistula/abscess) [2,10].

While the histologic assessment is the gold standard for diagnosis confirmation that showing extracellular mucinous lakes surrounded by well-differentiated dilated tortuous glands, nerves, and vessels, the application of Magnetic Resonance Imaging (MRI) and Ultrasonography (US) helps in delineating the anatomy of the fistula tract, the characteristic imaging of the mass, detecting associated tumors in extramural locations [11-13].

On the other hand, colonoscopy might be of less significance as the majority of reported cases had unremarkable exams; however, ruling out the presence of primary or synchronous tumors is important for management planning [7,14].

Due to a lack of consensus, the optimal management plan remains controversial; surgical resection with Abdominoperineal

Resection (APR) is the first line; some authors advocate for adjuvant chemoradiotherapy for a better outcome, while others end as palliative care due to delayed presentation and diagnosis [3,9,11,14,15].

Conclusion

In conclusion, chronic perianal fistula could represent a serious underlying condition such as perianal adenocarcinoma. Thus, a high clinical suspicion index is required to diagnose.

References

1. Sarveazad A, Bahardoust M, Shamseddin J, Youseffard M. Prevalence of anal fistulas: a systematic review and meta-analysis. *Gastroenterol Hepatol Bed Bench.* 2022;15(1):1-8.
2. Clancy C, Iqbal Z, Sheehan M, Joyce MR. An unusual ischiorectal Fossa mass. *Int J Surg Case Rep.* 2014;5(2):79-81.
3. Shao WJ, Sun GD, Chen YQ, Huang JC. Perianal mucinous adenocarcinoma arising from chronic anorectal fistulae: A review from Single Institution. *Int J Colorectal Dis.* 2009;24(9):1001-6.
4. Sohrabi C, Mathew G, Maria N, Kerwan A, Franchi T, Agha RA, et al. The SCARE 2023 guideline: updating consensus Surgical CAse REport (SCARE) guidelines. *Int J Surg.* 2023;109(5):1136-40.
5. Rosser C. Relation of fistula in ano to cancer of the anal canal, *Trans Am Proct Soc.* 1934;35:65-71.
6. Okada K, Shatari T, Sasaki T, Tamada T, Suwa T, Furuuchi T, et al. Is histopathological evidence really essential for making a surgical decision about mucinous carcinoma arising in a perianal fistula? report of a case. *Surg Today.* 2008;38(6):555-8.
7. Pai VD, Jatal S, Engineer R, Ostwal V, Saklani AP. Multidisciplinary management of colorectal adenocarcinoma associated with anal fistula: An Indian series. *Colorectal Dis.* 2015;17(11):O240-6.
8. Venclauskas L, Venclauskas L, Saladzinskas Z, Tamelis A, Pranyš D, Pavalkis D, et al. Mucinous adenocarcinoma arising in an anorectal fistula, *Medicina (Kaunas).* 2009;45(4):286-90.
9. Hisham RB, Rahman SA, Gul YA. Mucinous adenocarcinoma arising from chronic perianal fistula. *Surgical Practice.* 2007;11(2):88-9.
10. Ong J, Jit-Fong L, Ming-Hian K, Boon-Swee O, Kok-Sun H, Eu KW, et al. Perianal mucinous adenocarcinoma arising from chronic anorectal fistulae: A review from a single institution. *Tech Coloproctol.* 2007;11(1):34-8.
11. Díaz-Vico T, Fernández-Martínez D, García-Gutiérrez C, Suárez-Sánchez A, Cifrián-Canales I, Mendoza-Pacas GE, et al. Mucinous adenocarcinoma arising from chronic perianal fistula-a multidisciplinary approach. *J Gastrointest Oncol.* 2019;10(3):589-96.
12. Toyonaga T, Mibu R, Matsuda H, Tominaga Y, Hirata K, Takeyoshi M, et al. Endoanal ultrasonography of mucinous adenocarcinoma arising from chronic fistula-in-ano: Three case reports. *J Anus Rectum Colon.* 2018;1(3):100-5.

13. Yamaguchi T, Kagawa R, Takahashi H, Takeda R, Sakata S, Nishizaki D, et al. Diagnostic implications of MR Imaging for mucinous adenocarcinoma arising from fistula in ano. *Tech Coloproctol.* 2009;13(3):251-3.
14. Deruyter L, Venken R, Maetens M. Perianal mucinous adenocarcinoma arising from a chronic fistula-in-ano. *Acta Chir Belg.* 2014;114(6):410-13.
15. Leal RF, Ayrizono MLS, Coy CSR, Fagundes JJ, Góes JR. Mucinous adenocarcinoma derived from chronic perianal fistulas: Report of a case and review of the literature. *Tech Coloproctol.* 2007;11(2):155-7.