

Case Report

Bilateral Septic Cavernous Sinus Thrombosis Resulting in Bilateral Blindness: Case Report

Houda Brarou^{1*}, Taoufik Abdellaoui², Manal Bouggar¹, Yasmine Bensaoud¹, Soundouss Sebbata¹, Soukaina Laaouina¹, Yassine Mouzari¹ and Abdelbarre Oubaaz¹

¹Department of Ophthalmology, Military hospital Mohammed-V, Mohammed V University -Rabat, Morocco

²Sidi Mohamed Ben Abdellah University, Morocco

Abstract

Cavernous septic thrombosis is a rare condition that requires immediate medical attention due to its potential for serious complications. Prompt medical intervention is crucial in treating cavernous septic thrombosis. The present study is a case report of bilateral septic cavernous sinus thrombosis in a 16-years-old boy leading to total blindness. Findings of laboratory tests and Magnetic Resonance Imaging (MRI) confirmed the clinical diagnosis. Clinical-based medical care limited the disease progression. But regrettably, our patient sustained bilateral blind eyes and residual cranial nerve palsies due to his late presentation.

Keywords: Cavernous septic thrombosis; MRI; Painkillers; Computed tomography; Bilateral periorbital

Introduction

Cavernous Sinus Thrombosis (CST) in its septic form arises from an infection in the face, sphenoid, ethmoidal sinuses, or oral cavity. Infrequently, otitis media or orbital sinuses may be the underlying cause. Reported incidence of cavernous sinus thrombosis as a complication of orbital cellulitis is 1%. Before the availability of antimicrobial agents, the mortality from CST was 100%, however, it markedly reduced to 20% to 30% during the antibiotic era [1]. Despite this improvement, the persistent risk of death and severe morbidity underscores the importance of early recognition, diagnosis, and treatment of CST to mitigate potential harm to the patient. Here, we present a case involving bilateral CST leading to bilateral blindness.

Case Presentation

We present the case of a 16 years old male patient of African origin, with no past medical history who presented to the emergency room of a tertiary care center with bilateral periorbital and mid-facial swelling and spiking fever. Ten days earlier, he began having severe headaches and fever for which he took painkillers to control the pain.

At the hospital, his inflammatory markers were markedly raised (white cell count $13 \times 10^9/L$ 91% neutrophils, C-reactive protein 260 mg/L), with a normal renal function. Computed Tomography (CT) brain revealed a frontal abscess, a right periorbital cellulitis, pansinusitis, a frontal bone osteitis and a left thrombosed cavernous sinus. He was treated empirically with high-dose Intravenous (IV)

flucloxacillin ceftriaxone and gentamycine. The patient was then transferred to the military hospital Mohamed V of Rabat for further tests and investigations.

At presentation, the patient was alert and fully oriented to person, place and time with no neurological deficits. His vital signs and temperature were normal. He had marked facial and periorbital swelling. A body CT scan and cerebral angio-MRI revealed subdural and extradural empyemas, fronto-orbital abscess measuring 9×5 cm; bilateral thrombosed cavernous sinuses associated to a thrombus of the right internal jugular vein (Figures 1 and 2), along with a pansinusitis. A body CT-scan showed multiple pulmonary abscesses and a small pericardial effusion.

The patient underwent drainage of his fronto-orbital abscess. Blood cultures were taking and he was transferred to the Intensive Care Unit (ICU) at this stage. The ophthalmological examination was performed at the patient's bed. His visual acuity was no light perception in both eyes. The patient had bilateral periorbital edema, which was worse on the right side. He also had a bilateral ptosis and a bilateral purulent chemosis along with bilateral corneal hypoesthesia (Figures 3 and 4). A sluggish pupillary reflex and an ophthalmoplegia

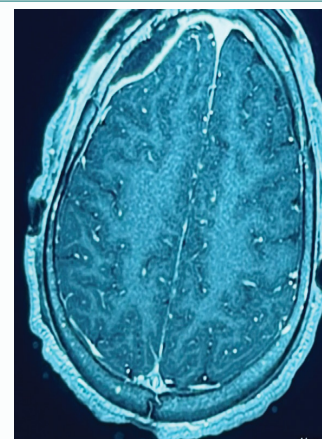


Figure 1: Coronal T1 brain MRI showing subdural and extradural empyemas.

Citation: Brarou H, Abdellaoui T, Bouggar M, Bensaoud Y, Sebbata S, Laaouina S, et al. Bilateral Septic Cavernous Sinus Thrombosis Resulting in Bilateral Blindness: Case Report. *Ann Med Case Rep.* 2024;6(1):1046.

Copyright: © 2024 Houda Brarou

Publisher Name: Medtext Publications LLC

Manuscript compiled: Feb 26th, 2024

***Corresponding author:** Houda Brarou, Department of Ophthalmology department, Military hospital Mohammed-V, Mohammed V University-Rabat, Morocco, Tel: +212-673721525

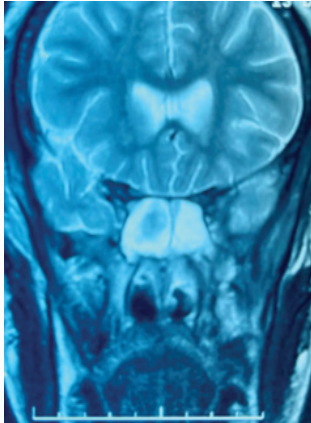


Figure 2: Axial T2 MRI showing bilateral cavernous sinus thrombosis.

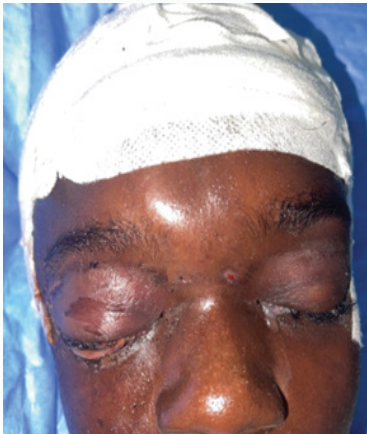

Figure 3: Image of the patient's face showing bilateral periorbital edema and a bilateral ptosis.

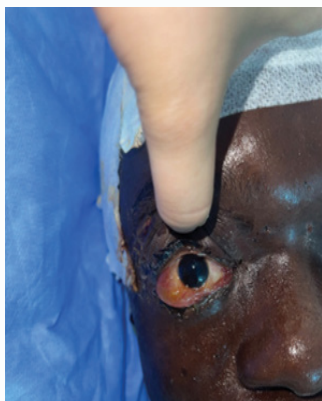


Figure 4: Purulent chemosis on the right eye.

were also found on both eyes. Intra ocular pressure seemed to be normal based on bi digital palpation. Fundoscopy was performed using a 20D lens and showed no signs of papilloedema nor vasculitis (Figure 5).

Laboratory studies showed a WBC of $15.5 \times 10^9/L$, CRP of 10⁷ mg/dL, procalcitonine of 5. Microscopic examination of urine came back aseptic. A lumbar puncture was performed and analysis of cerebrospinal fluid revealed pleocytosis (46 white cells/ μL) with

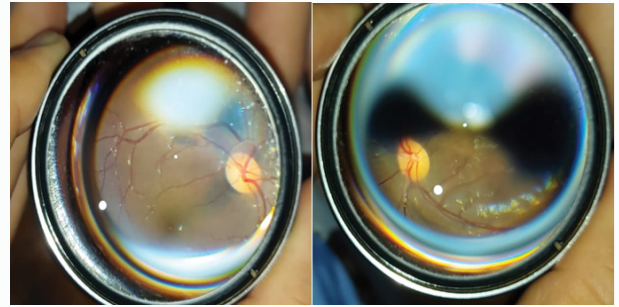


Figure 5: A view of the fundus exam of both eyes using a 20 dpt lens by indirect ophtalmoscopy using a smartphone camera showing no signs of papilloedema nor vasculitis.

neutrophilic predominance of 70%, 5 erythrocytes/ μL , glycorrachia of 57 mg/dL. Gram stain revealed the presence of gram-positive cocci.

Pending blood cultures results, and considering the critical condition of the patient, infectious serology tests were conducted and came back negative, and a trans-thoracic echocardiography was performed and showed no signs of infective endocarditis. He was placed on long term intravenous antibiotic therapy (Vancomycin and Imipenem) based on positive blood cultures for Methicillin-Resistant Staphylococcus Aureus (MRSA). Heparin was started.

Discussion

The cavernous sinus, located in the middle cranial fossa, serves as a crucial bilateral interconnected channel for draining the head and neck. It maintains close proximity to cranial nerves III, IV, V1, and V2 along the lateral wall, as well as cranial nerve VI, sympathetic fibers, and the internal carotid artery within its confines. Given the cerebral venous system is valveless, infections from the head and neck, such as sinusitis, otitis media, dental abscess, or orbital cellulitis, have the potential to rapidly disseminate to the cerebral venous sinuses [2-4].

The ocular manifestations associated with Cavernous Sinus Thrombosis (CST) can resemble conditions such as orbital cellulitis, superior ophthalmic vein thrombosis, orbital apex syndrome, carotid-cavernous fistula, and superior orbital fissure syndrome. Therefore, clinicians should maintain a heightened awareness of the possibility of CST in patients presenting with oculomotor palsies, ptosis, fever, and sensory disturbances in the ophthalmic and maxillary divisions [5,6]. The definitive diagnosis necessitates confirmation through CT or Magnetic Resonance Imaging (MRI) of the brain. Our patient had a cavernous sinus thickening and filling defect suggestive of thrombus.

Although the disease mortality is lowered in the era of antibiotics, close monitoring is also crucial to prevent the infection from spreading to the contralateral cavernous sinus and brain. In our case, the thrombus rapidly spreads to the contralateral cavernous sinus leading to a complete blindness. The use of anticoagulation is the mainstay in the treatment of CST as it can halt the thrombus propagation and minimize complications [7-9]. Regrettably, our patient sustained bilateral blind eyes and residual cranial nerve palsies due to his late presentation. Nevertheless, the immediate treatment has successfully halted the disease progression and mitigated potential systemic complications.

Vision loss in CST may arise from various factors such as central retinal artery occlusion, ophthalmic vein occlusion, emboli, carotid artery thrombosis, ischemic optic neuropathy, toxic neuritis, or keratitis exposure [10]. Our hypothesis is that the patient experienced

posterior ischemic optic neuropathy, considering the normal optic disc and the absence of tortuous or dilated vessels.

References

1. Clune JP. Septic thrombosis within the cavernous chamber Review of The Literature With Recent Advances In Diagnosis And Treatment. *Am J Ophthalmol.* 1963;56:33-9.
2. Cannon ML, Antonio BL, McCloskey JJ, Hines MH, Tobin JR, Shetty AK. Cavernous sinus thrombosis complicating sinusitis. *Pediatr Crit Care Med.* 2004;5(1):86-8.
3. Zanoletti E, Cazzador D, Faccioli C, Sari M, Bovo R, Martini A. Intracranial venous sinus thrombosis as a complication of otitis media in children: critical review of diagnosis and management. *Int J Pediatr Otorhinolaryngol.* 2015;79(12):2398-403.
4. Ann J K, Sreedhar A, Jacob MC. A case of cavernous sinus thrombosis complicating orbital cellulitis. *Kerala J Ophthalmol.* 2016;28(1):61-4.
5. Ebright JR, Pace MT, Niazi AF. Septic thrombosis of the cavernous sinuses. *Arch Intern Med.* 2001;161(22):2671-6.
6. Visvanathan V, Uppal S, Prowse S. Ocular manifestations of cavernous sinus thrombosis. *BMJ Case Rep.* 2010;2010:bcr0820092225.
7. Saposnik G, Barinagarrementeria F, Brown RD, Bushnell CD, Cucchiara B, Cushman M, et al. Diagnosis and management of cerebral venous thrombosis: a statement for healthcare professionals from the American Heart Association/American Stroke Association. *Stroke.* 2011;42(4):1158-92.
8. Coutinho J, de Bruijn SE, Deveber G, Stam J. Anticoagulation for cerebral venous sinus thrombosis. *Cochrane Database Syst Rev.* 2011;2011(8):CD002005.
9. Misra UK, Kalita J, Chandra S, Kumar B, Bansal V. Low molecular weight heparin versus unfractionated heparin in cerebral venous sinus thrombosis: a randomized controlled trial. *Eur J Neurol.* 2012;19(7):1030-6.
10. Topazian RG, Goldberg MH, Hupp JR. *Textbook of oral and maxillofacial infections*, 4th ed. Philadelphia: W.B. Saunders; 2002.p.328-46.