

Clinical Image

Brain Cysticercosis

Fan Chen^{1*} and Dawei Chen²

¹Department of Neurosurgery, University Medicine Greifswald, Germany

²Department of Neurosurgery, First hospital of Jilin university, China

Clinical Image

A 63-year-old man presented to the Department of Emergency with epileptic seizures and a 2-month history of headache. Laboratory results showed an indirect hemagglutination test for cysticercosis antibodies was positive. Computed tomography of the brain revealed Left frontal temporal lobe multiple cyst, bilateral ventricle enlargement, paraventricular edema (Figure 1A). In this patient, left total resection and extraventricular drainage was performed, release the colorless transparent liquid inside and completely remove the vesicle wall (Figure 1B and C). The vesicle wall after HE staining. Microscopic examination revealed: the inner layer is the hyaline degeneration tissue, the middle layer is the inflammatory cell infiltration layer, and the outer layer is the neuroglial fiber and glial cell proliferation layer. The disease occurs by ingesting its eggs from contaminated food or, most often, directly from a Taenia carrier by the fecal-oral route. Brain Cysticercosis is a leading cause of acquired epilepsy worldwide.

After the operation, oral albendazole treatment was performed. At a 6-month follow-up visit, the patient had no further symptoms.

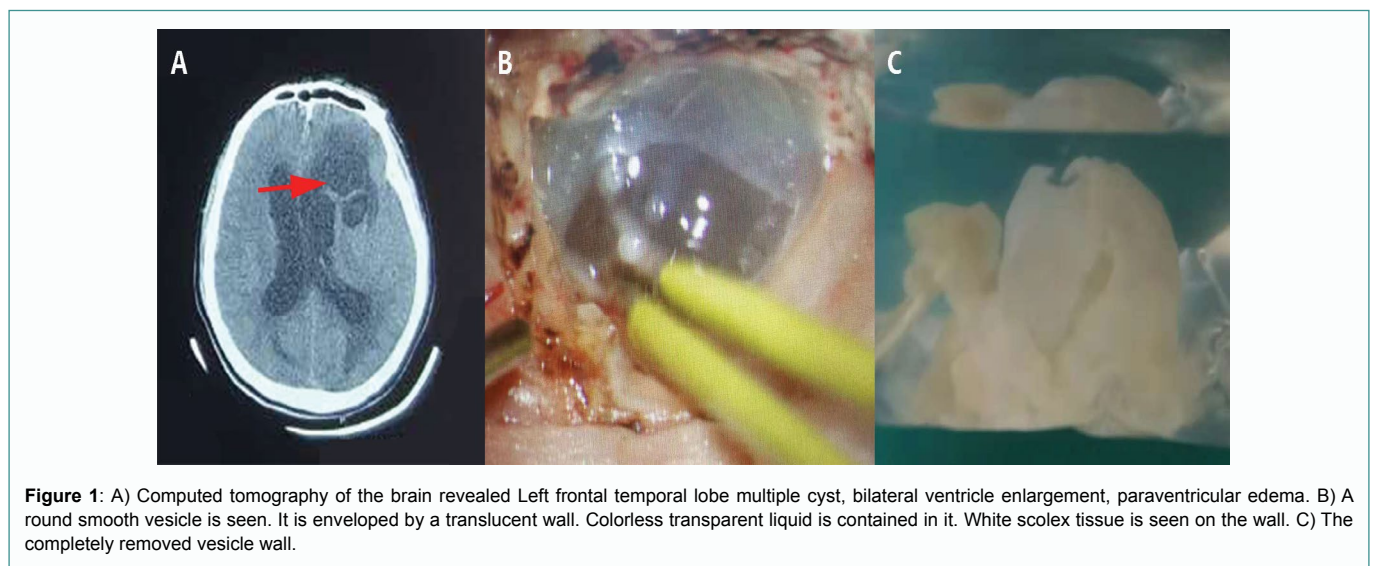


Figure 1: A) Computed tomography of the brain revealed Left frontal temporal lobe multiple cyst, bilateral ventricle enlargement, paraventricular edema. B) A round smooth vesicle is seen. It is enveloped by a translucent wall. Colorless transparent liquid is contained in it. White scolex tissue is seen on the wall. C) The completely removed vesicle wall.

Citation: Chen F and Chen D. Lushington GH. Brain Cysticercosis. *Ann Oper Surg.* 2019; 1(1): 1001.

Copyright: © 2019 Fan Chen

Publisher Name: Medtext Publications LLC

Manuscript compiled: March 25th, 2019

***Corresponding author:** Fan Chen, Department of Neurosurgery, University Medicine Greifswald, Germany, Tel: +4915172071230, E-mail: professorchen@foxmail.com