

Case Report

Cardiac Involvement Resulting from Thoracic Endometriosis

Hossein Sarmast¹, Ahmad Takriti² and Zahra Sepehrmanesh^{3*}

¹Department of Cardiovascular Surgery, Damascus University, Damascus, Syria

²Department of Cardiac Surgery, Damascus University, Damascus, Syria

³Department of Psychiatry, Kashan University of Medical Sciences, Iran

Abstract

Endometriosis usually occurs in the pelvis and the most commonly involved sites are the ovaries, the uterosacral and broad ligaments and the parietal pelvic peritoneum. However, involvement of extra-pelvic organs is not uncommon. Much more uncommon sites for extrapelvic endometriosis are lungs, heart and brain involvement. It has been hypothesized that retrograde menstruations can lead to metastatic peritoneal implantations or the serous cells may be stimulated towards a metaplastic differentiation. We reported a 28-years old woman who suffered from thoracic endometriosis syndrome accompanied by cardiac involvement. Also our patient is the third report of surgically documented thoracic endometriosis syndrome, involving right side pleura and pericardium. She was urgently taken to operation room. Right side thoracotomy was carried out and complicated regions were resected and repaired.

Keywords: Endometriosis; Hemothorax; Hemopericardium; Thoracic endometriosis syndrome; Infertility; Dyspareunia; Dysmenorrhea; Major depressive disorder; Endometrial nodule

Abbreviations

TES: Thoracic Endometriosis Syndrome; OCPs: Oral Contraceptives; MDD: Major Depressive Disorder; MD: Major Depression; TCAs: Tricyclic Antidepressants; SSRIs: Selective Serotonin Reuptake Inhibitors; CXR: Chest X Ray; TAH: Total Abdominal Hysterectomy; BSO: Bilateral Salpingo-ophorectomy

Introduction

Endometriosis is defined as the presence of a normal endometrial tissue, including the stroma and glands, implanted outside the uterine cavity [1]. It affects as many as 10%-20% of fertile females and approximately 50% of infertile woman [2]. Carl von Rokitansky was the first one to identify endometriosis histologically under microscope. It commonly occurs in the genital organs (uterus, ovaries, vaginal fornix, posterior portion of cervix) leading to symptoms like dyspareunia, dysmenorrhea and dysuria [3]. It is presence in sites other than in genital organs is termed extra genital endometriosis and it can be subdivided into pelvic and extra pelvic endometriosis. The most frequently involved pelvic structures are the uterosacral ligaments (70%), vagina (14%), rectum (10%) and rectovaginal septum or bladder (6%). Extrapelvic endometriosis is a rare condition occurring in 8.9% of cases of endometriosis and may be seen in the abdominal wall and diaphragm. Much more uncommon sites for

extrapelvic endometriosis are lungs, heart and brain involvement [4]. Thoracic Endometriosis Syndrome (TES) is an extremely rare condition that involves around the lungs such as pleura, pulmonary Parenchyma, diaphragm, air ways and pericardium. Most frequently involved mechanism accounting for the extragenital endometriosis is unclear. It has been hypothesized that retrograde menstruations can lead to metastatic peritoneal implantations or the serous cells may be stimulated towards a metaplastic differentiation. Despite extraperitoneal localizations could be owing to vascular or lymphatic dissemination [5,6].

Case Presentation

Our case was a 28 - years old, nulliparous female who had carried the past medical history of dysmenorrhea and infertility as well as Major Depressive Disorder (MDD) for almost 5-years. She had taken GNRH and OCPs for infertility also antidepressants (TCAs and SSRIs) for treatment of Major Depression (MD). 8-Months before her recent presentation, she experienced right upper quadrant abdominal pain and distention with high pitched bowel sounds. Abdominal ultrasound evaluation was unremarkable and the pain eventually resolved spontaneously. Two months after aforementioned history, she presented to the emergency ward of surgical department because of the left sided cramping abdominal pain accompanied by non bilious emesis. Abdominal CT scan and laparoscopic findings demonstrated extrinsic compression on the mid portion of the sigmoid due to peritoneal mass with adhesion in the pelvis. After that the patient underwent laparotomy and resection of sigmoid and appendectomy. The biopsy of the mass and its histopathology evaluation demonstrated the endometriosis. She was admitted to our center (cardiovascular surgery center) last week because of chest pain, breathlessness, palpitation, weaknesses, fatigue, feeling sick and faintness lasting 2-hours. She complained from severe sharp stabbing chest pain behind the breast bone. The pain intensified with coughing, lying down and deep inspiration and subsided with leaning forward. CXR showed pleural effusion on the right side and one liter of hemorrhagic fluid was drained from the pleural cavity (Figure 1).

Citation: Sarmast H, Takriti, Sepehrmanesh Z. Cardiac Involvement Resulting from Thoracic Endometriosis. Cardiovasc Surg Int. 2019; 1(1): 1002.

Copyright: © 2019 Hossein Sarmast

Publisher Name: Medtext Publications LLC

Manuscript compiled: August 07th, 2019

***Corresponding author:** Zahra Sepehrmanesh, Department of Psychiatry, Kashan University of Medical Sciences, Iran, Tel: 00963112133000, 00963112133020; Fax: 00963112121620; E-mail: z.sepehrmanesh@gmail.com

After that the overall symptoms apparently subsided. Chest CT scan which was done on the next day demonstrated heterogenic fluid in the right pleural cavity as well as in the pericardial cavity. The patient collapsed on the same day whereas it was the third day after onset of menstruation. She was urgently taken to operation room. Right side thoracotomy was carried out that revealed multiple bleeding nodules involving the right parietal pleura, the diaphragmatic central tendon and infiltrating through the diaphragm to the pericardium. One of the pericardial lesions was in significant size: 1.5 cm × 1.3 cm (Figure 2). The wide area of the left and right diaphragm, base of the right parietal pleura also approximately (3.5 cm × 1.5 cm) of the parietal pericardium at the level of its insertion on the central tendon was rejected. This pericardial window was made with meticulous care of phrenic nerve fibers (nerve -sparing). Then the pericardial window was closed with a tension-free single layer non-absorbable suture (2-0 polypropylene). We didn't use any pericardial patch due to the good compliance of the pericardial tissue. As well as because of the elasticity of the tissue and the mobilization of the patient's diaphragm, it was not necessary to repair the diaphragmatic gap with artificial patch. Accordingly, a double layer non-absorbable running suture (2-0 polypropylene) was performed in each side and placement of two chest tubes (right pleural cavity and retro pericardium) was carried out for preventing of pneumothorax.

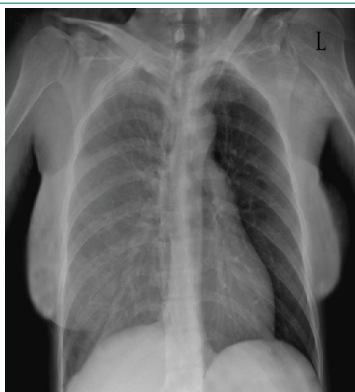


Figure 1: Chest x-ray of the 28-years old female with thoracic endometriosis demonstrated pleural effusion on the right side.

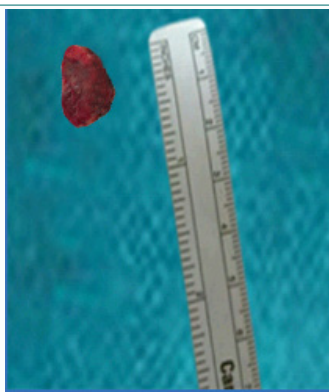


Figure 2: Excised endometrial nodule of pericardium from the 28-years old female with thoracic endometriosis.

Discussion and Conclusion

Based on a review of the literature, our patient is the third report of surgically documented TES, involving right side pleura and pericardium. With reference to the worldwide reports diaphragmatic endometriosis especially TES is a rare condition with a specific surgical

indication. The consideration with regard to the consequence of the symptoms and course of the condition in our patient (initially with genital then pelvic and abdominal endometriosis and eventually with TES) maybe related to the primary theory of etiology, for which the retrograde " regurgitation " of the endometrial tissue passes through the oviducts into the peritoneal cavity and the implantation followed by the proliferation occurs in ectopic sites. Endometriosis affects an estimated 89 million women of reproductive age worldwide. In other words, it affects 6% to 10% of all women. The thoracic diaphragm and visceral diaphragm is the most commonly involved sites of TES (38.8% and 29.6%) [7]. The distribution of endometrial implant through the diaphragm seems to be asymmetric with the right being affected more than the left. This can be explained by transportation of viable cells by the intra abdominal current flowing in a clockwise manner coming down from the left peritoneal gutter and flowing across the pelvic floor and up along the right peritoneal gutter, once they reach the right upper quadrant, they are stuck by falciform ligament [8]. This phenomenon facilitates the seeding of endometrial implants to the right diaphragm and ultimately to the thoracic cavity through fenestrations in diaphragm. The diffusion of endometrial cells through fenestrations is evident in the literature due to impressive and almost identical preponderance of right - sided lesions of diaphragm, pleura and pericardium. This asymmetry in distribution argues against the theory of coelomic metaplasia, however due to embryonic origin of pleura, pericardium and peritoneum from coelomic epithelium, this theory can't be entirely rejected [9]. Patients usually have intensive symptoms, occurring within 24 to 48 hours of onset of menses. The most frequent symptoms are chest pain (90%), followed by dyspnea (31%), hemoptysis (7%) and cough (rare). Although it is an uncommon condition, TES is the most frequent extrapelvic manifestation of endometriosis and encompasses clinical presentations such as pneumothorax, hemothorax, hemoptysis, lung nodules as well middle mediastinal involvements such as catamenial pericardial effusion, pericardial nodules, hemopericardium accompanied by sudden and excruciating chest pain due to parietal pericardial irritation. Successful treatment of thoracic endometriosis with OCPs, GnRH agonists and Danazol has been reported [10,11]. High recurrence rates have also been reported. If the pulmonary disease is recurrent or progressive, thoracotomy, excision of lesions or pleurodesis may be necessary. Pleurodesis has been shown to be associated with lower recurrence rates than has hormonal treatment [12]. Pneumothorax or haemothorax requires immediate treatment. Long - term treatment of the endometriosis is medical and /or surgical. Definitive therapy in the form of TAH and BSO is an option in patients who have advanced pelvic disease, in whom medical management has failed and who have completed childbearing. Lobectomy is rarely indicated [13].

References

1. Woodward PJ, Sohaey R, Mezzetti TP Jr. Endometriosis: Radiologic-Pathologic Correlation. *Radio Graphics*. 2000;21(1):193-216.
2. Bennett GL, Slywotzky CM, Cantera M, Hecht EM. Unusual Manifestations and Complications of Endometriosis - Spectrum of Imaging Findings: Pictorial Review. *AJR Am J Roentgenol*. 2010;194(6):34-46.
3. Machairiotis N, Stylianaki A, Dryllis G, Zarogoulidis P, Kouroutou P, Tsiamis N, et al. Extrapelvic endometriosis: a rare entity or an under diagnosed condition? *Diagn Pathol*. 2013;8:194.
4. Azizad-Pinto P, Clarke D. Thoracic endometriosis syndrome: case report and review of the literature. *Perm J*. 2014;18(3):61-5.
5. Nair SS, Nayar J. Thoracic endometriosis syndrome: a veritable Pandora's box. *J Clin Diagn Res*. 2016;10(4):4-8.

6. S. Alwadhi, S. Kohli, B. Chaudhary, k. Gehlot. Thoracic endometriosis - A Rare Cause of Haemoptysis. *J Clin Diagn Res.* 2016;10(4):1-2.
7. Agha RA, Fowler AJ, Saetta A, Barrai I, Rajmohan S, Orgill DP. The SCARE statement: consensus-based surgical case report guidelines. *Int J Surg.* 2016;34:180-6.
8. Nwiloh J. Diaphragmatic patch: a useful adjunct in surgical treatment of recurrent catamenial hemothorax. *Rev Port Pneumol.* 2011;17(6):278-80.
9. Inoue T, Chida M, Inaba H, Tamura M, Kobayashi S, Sado T. Juvenile catamenial pneumothorax: institutional report and review. *J Cardiothorac Surg.* 2015;10:83.
10. Joseph J, Sahn SA. Thoracic endometriosis syndrome: new observations from an analysis of 110 cases. *Am J Med.* 1996;100(2):164-70.
11. Carter EJ, Ettensohn DB. Catamenial pneumothorax. *Chest.* 1990;98(3):713-6.
12. Espanella J, Armengol J, Bella F, Lain JM, Calaf J. Pulmonary endometriosis: conservative treatment with GnRH agonists. *Obstet Gynecol.* 1991;78(3 Pt 2):535-7.
13. Joseph J, Reed C, Sahn SA. Thoracic endometriosis: recurrence following hysterectomy with bilateral salpingo-oophorectomy and successful treatment with talc pleurodesis. *Chest.* 1994;106(6):1894-6.