

Case Series

Case Series of Left Atrial Myxoma Presenting as Rare Complication Myocardial Infarction

Natesh BH, Arun Kumar Ullagaddi, Santhosh Jadhav*, Ashalatha B, Ravi Math, Laxshmi Shetty and Manjunath CN

Department of Cardiology, Sri Jayadeva Institute of Cardiovascular Sciences and Research, India

Abstract

Atrial myxoma accounts for approximately 50% of all benign cardiac tumors. The majority of myxoma are located in the left atrium and present with variable clinical manifestation. We report a case series of left atrial myxoma, presenting with myocardial infarction and embolization including peripheral arteries. The patients underwent evaluation, coronary angiography and surgery. Cases presenting as ST elevation myocardial infarction could be embolic complication of LA myxoma. In summary, early diagnostic identification of LA myxoma presenting as myocardial infarction is important and immediate surgical removal of myxoma is required as the probability of thromboembolic complications increases with time.

Keywords: Left atrial myxoma; Rare cases; Series; Coronary embolization; Myocardial infarction

Abbreviations

LA: Left Atrium; ECHO: Echocardiography; ANGIO: Angiography; TTE: Trans Thoracic Echocardiography; TEE: Trans Esophageal Echocardiography; HPE: Histopathology Evaluation; MI: Myocardial Infarction; LAD: Left Anterior Descending; LCX: Left Circumflex; CT: Computerised Tomography; HB: Hemoglobin; TC: Total Count; LV EF : Left Ventricular Ejection Fraction; ECG: Electrocardiography; LA: Left Atrium; LV: Left Ventricle ; RA: Right Atrium; LMCA: Left Main Coronary Artery; PDA: Posterior Descending Artery; PLV: Posterolateral Branch; CPB: Cardio Pulmonary by pass

Introduction

Myxomas are the most common (50%) benign primary tumour of the heart. It is commonly located in the left atrium and mainly originates from an area in the atrial septum near the fossa ovalis. More common on left side than right side. Patients with atrial myxoma present with clinical features due to intra cardiac obstruction, like as in mitral stenosis, coronary embolization, systemic embolization, or constitutional symptoms like fever, myalgia and weight loss. Trans thoracic Echocardiography is the method of choice for the diagnosis of LA myxoma and surgical resection is the only effective treatment to prevent its mechanical and embolic complications. Herein, we report series of three rare cases of a large atrial myxoma presenting with

extensive systemic embolization and coronary embolization causing Myocardial Infarction (MI) [1-5].

Case Series

Series of cases presenting as rare presentation of LA myxoma is described here.

Case 1

A 38 year old female presented to us in Emergency Room with 5 days history of chest pain, dyspnea on exertion grade II. No comorbidities were noted. She had no past history of breathlessness, fever, perspiration. On examination her Heart Rate was 102/minute, BP was 100/70 mm hg [6]. Respiratory rate 23/min and oxygen saturation 96%, on cardiovascular examination there was no murmur. Respiratory system evaluation showed bilateral crepitations. Investigation showed Hemoglobin 12.4%, C.R.P. negative, Serum creatinine s0.90%, Total count 9500/cu.mm, Platelet count 4.46 lacks/cuu.mm, Troponin T hs 0.128 ng/ml [7].

The ECG showed tachycardia with ST elevation in lateral leads V3-V5 (Figure 1). As patient continued to have chest pain, patient was taken up for emergency coronary angiography. Her angiogram showed acute occlusion after Diagonal 2 in distal LAD (Figure 2). As it was distal occlusion with no lesion it was decided to go with conservative medical management. Since it was suggestive of embolization of distal vessel it was decided to evaluate for source of emboli. Her Trans thoracic ECHO in coronary care unit showed Ischemic Heart Disease with regional wall motion abnormality at mid anteroseptal, mid anterior, apico anterior, apico septal, apico lateral segments thin and akinetic with LVEF of 50%. It also revealed a large LA myxoma seen attached to Inter Atrial Septum at Patent Foramen Ovale site (Figure 3), protruding into Left Ventricle in diastole, causing mild mitral obstruction.

After preoperative evaluation patient underwent 5 cm × 5 cm left atrial myxoma excision. The approach was median sternotomy. Right lateral pericardiotomy was done. Aortic, Superior Vena Cava, Inferior Vena Cava and cardioplegia purse strings were taken. Under systemic heparinisation, Cardio Pulmonary By pass was established after aortic and bicaval cannulation. Ascending aorta cross clamped. Heart arrested with ante-grade cardioplegia. RA was opened and an

Citation: Natesh BH, Arun Kumar U, Santhosh J, Ashalatha B, Ravi M, Laxshmi S, et al. Case Series of Left Atrial Myxoma Presenting as Rare Complication Myocardial Infarction. *Cardiovasc Surg Int.* 2020;1(1):1005.

Copyright: © 2020 Natesh BH

Publisher Name: Medtext Publications LLC

Manuscript compiled: May 20th, 2020

***Corresponding author:** Santhosh Jadhav, Department of Cardiology, Sri Jayadeva Institute of Cardiovascular Sciences and Research, Bangalore, 560069, India, Tel: +919844583583; E-mail: santoshj99@yahoo.com

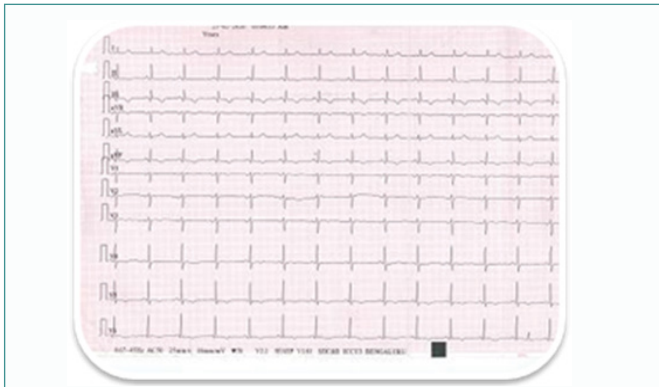


Figure 1: Showing ST elevations in lateral leads.

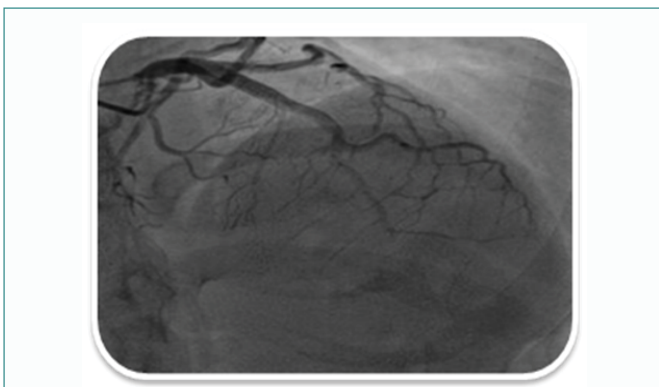


Figure 2: CAG showing distal LAD occlusion.

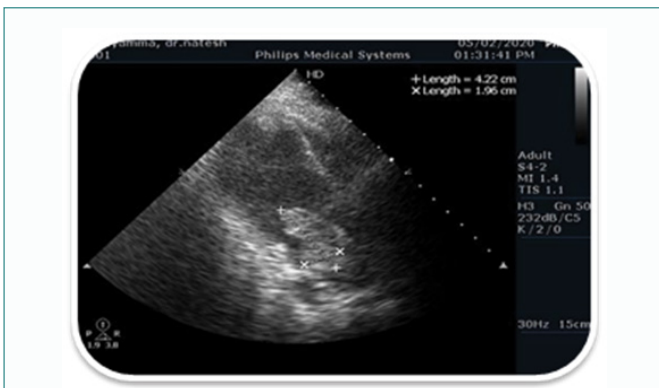

Figure 3: ECHO showing LA myxoma.

with history of Loss of consciousness 7 hours back where in patient had recovered in 10 minute. There was no history of chest pain, breathlessness, palpitation. However, Troponin T done outside was positive [9]. On examination she had heart rate of 72/min, BP 130/90 mmhg in Killip class I. Blood investigation disclosed Hemoglobin 11.6 gms/dl, Total count 13,900 /cu mm, Platelet count 3.98 lacks/cu mm, serum creatinine 1.1 mgs/dl, Troponin T hs 0.153 ng/ml. Her ECG showed ST elevations in lead II, III and AVF. As patient had continuous pain with giddiness, was taken for emergency angiography which showed complete occlusion of distal PDA in RCA with rest of LAD, LCX being normal. Distal occlusion of RCA was suggestive of embolic occlusion. Trans thoracic ECHO with HP SONOS ECHO machine showed intra cardiac mass suggestive of Large LA myxoma (54 mm × 36 mm) attached to the inter atrial septum, mild mitral regurgitation, IHD with RWMA and normal LV function with LVEF 60%. The mass was prolapsing through the mitral valve into LV during diastole. Doppler showed Trans mitral flow acceleration. A chest x-ray showed clear lung fields, CT abdomen; hematological evaluation did not show any evidence of malignancy.

After preoperative evaluation and written consent patient was operated for LA myxoma resection. Incision was made in RA exposing 50 mm × 30 mm slimy layer covered mass which was attached to left side of inter atrial septum. It was not easy to avoid fragmentation of tumour [10]. Large mass of LA myxoma was attached to part of inter atrial septum, so a part of IAS was resected, to allow manipulation. A bovine pericardial patch was used to reconstruct the inter atrial septum. Mass was inspected to look for involvement of LV and mitral valve, none was found. The resected mass was sent for Histopathology and benign cardiac tumour Myxoma was confirmed. The tumour showed inflammatory cells, myxoma cells and basophilic mucoid substance. Post op ECHO did not show residual mass and mitral regurgitation. Patient had uneventful recovery, discharged and followed up (Figures 5 and 6).

Case 3

A 41 year old female presented to emergency department with sudden onset of chest pain with pain in left leg. Patient was referred from local hospital with peripheral Doppler showing occlusion of artery of lower left leg extremity. Outside Troponin T was positive. Patient continued to have chest pain on presentation. On examination heart rate was 74/min with BP of 116/72 mm hg. Other general parameters being normal. On auscultation systolic murmur at mitral area of grade 2 was found with tumour plop. Left lower limb extremity was cold to touch with decreased pulsation. ECG showed mild ST

incision was made in the fossa ovalis to approach the myxoma. Total excision of mucoid myxoma was done measuring around 5 cm × 5 cm, generous wash given in LA, LV and RA (after closing the defect). Fossa ovalis defect was closed using a pericardial patch. RA closed using 5-0 continuous sutures in two layers. Heart filled and de-aired. Aortic cross clamp removed. Patient gradually weaned off CPB and serially de-cannulated. Protamine reversal was given, Hemostasis achieved [8]. Retro-cardiac, retro sternal and right pleural drainage tubes and RV epicardial pacing wire placed. Sternum and chest closed. Patient recovered with stable hemodynamics. Histopathology of excised tumour showed myxoid proliferation with lymphoid cells. Patient was followed up for 3 months (Figure 4).

Case 2

A 50 year old female patient was referred from local practitioner

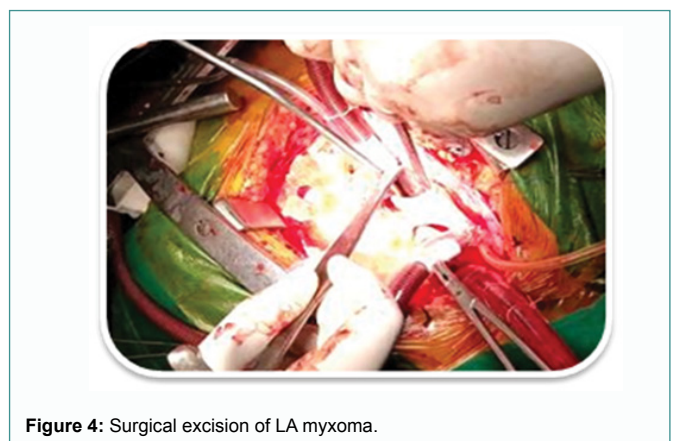

Figure 4: Surgical excision of LA myxoma.

elevation in lead II, III & AVF. Chest X-ray was normal. In view of continuous chest pain on and off patient was taken for emergency angiography which showed normal LMCA, LAD, and LCX. Distal PLV had total occlusion [11-15]. Trans thoracic ECHO was performed in CCU showed 32 mm × 24 mm mass in left atrium attached to inter atrial septum protruding into LV. The mass was moving into LV with diastole. To avoid further peripheral complication after evaluation and consent Patient was operate by Cardio thoracic team. Patient underwent median sternotomy under general anesthesia, CPB, hypothermia, cross clamping. The tumour of size 28 mm × 20 mm was resected. Embolectomy conducted in left femoral artery through Fogarty catheter, removed red colour material which was sent for Histopathology. Histopathology report confirmed it was embolised myxoma material with stellate cells, spindle cells with inflammatory surrounding cells. After recovery patient was discharged and followed up for 2 months (Figure 7 and 8).

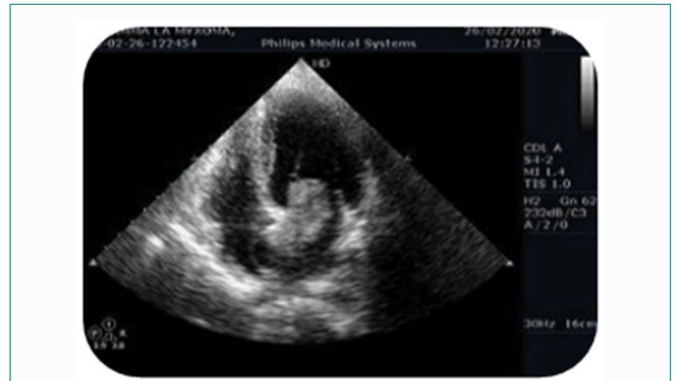

Figure 8: ECHO 4C showing LA myxoma protruding into LV.

Discussion and Conclusion

The calculated prevalence of primary cardiac tumours according to autopsy study is 0.3%. Nearly 75% of cardiac tumours are benign. Cardiac myxomas are tumours by mesenchymal origin. Myxoma account for 50% of cardiac tumours. Majority is found in women and are sporadic. Myxomas are 3 to 5 times more common in left atrium than right atrium. Left atrial myxomas usually are attached to inter atrial septum near fossa ovalis by pedicle or body of tumour. Nearly 90% are attached by peduncle. There are two morphological types, polypoid or round. They are common between 3rd and 6th decade, though can present at any age.

The clinical manifestations of LA myxoma are distinct. They produce symptoms by obstruction similar to mitral stenosis, embolization to coronary artery, systemic embolization as embolization to Aorta or branches of Aorta or systemic constitutional symptoms. They can present with constitutional symptoms (35% cases) like fever, myalgia and weight loss. Auscultation character is tumour plop, typical low pitched sound audible during early and mid diastole. Many a times cerebral artery, renal artery, kidney, spleen, even peripheral artery are affected. Systemic emboli can occur in 30% to 40% of left atrial myxoma. Cardiac myxoma has to be kept as one of differential diagnosis as source of embolism in otherwise healthy subject presenting as thrombo-embolism. Factors determining presentation of LA myxoma are size, location, pedicle, mean platelet volume and platelet count. Embolization can present as stroke, limb ischemia, and renal infarction or rarely as myocardial infarction.

The incidence of coronary embolization is only 0.06%, of which The RCA (Right Coronary Artery) is most often affected. However, embolization to the LAD (Left Anterior Descending) and LCX (Left Circumflex Coronary) arteries has also been reported. Reviews have shown that inferior myocardial infarction is seen in 63.6%, anterior wall MI in 22.7%, posterior wall in 9.1%. In myxoma related Myocardial infarction; right coronary artery was most commonly involved and up to one third angiograms can be normal. Suggested hypothesis is high rate of spontaneous re-canalisation after myxomatous embolization.

Investigations for diagnosis of LA myxoma are Transthoracic Echocardiography (TTE), Trans Esophageal Echocardiography (TEE), Cardiac Magnetic Resonance (CMR), and CT scan. Coronary angiography is considered as necessary test for patients with chest pain, ST elevation or age more than 40. Tran's thoracic echocardiography gives reasonable diagnosis in majority of cases, though use of other investigations like is CT scan is increasing. Surgical excision is curative though low rate of recurrence are known.

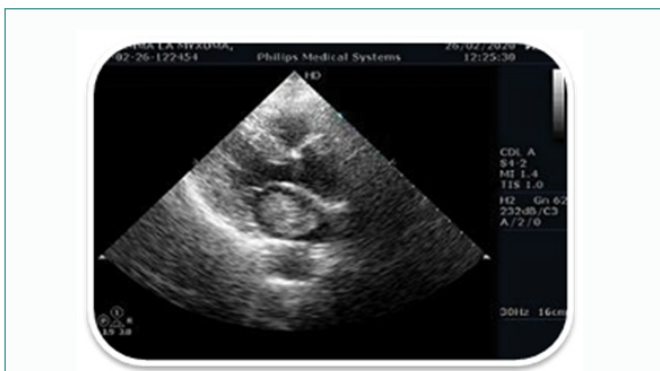

Figure 5: ECHO plax showing LA myxoma.

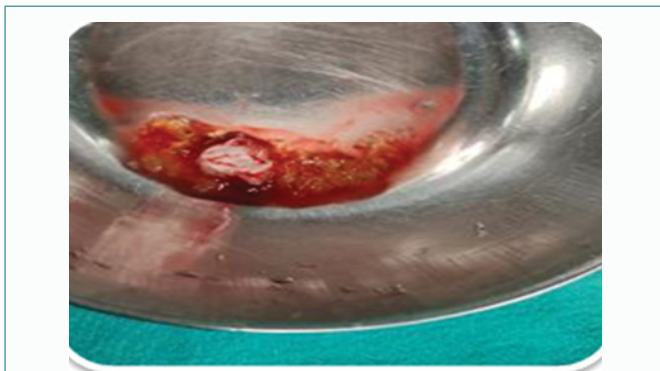

Figure 6: Surgical excision of LA myxoma.

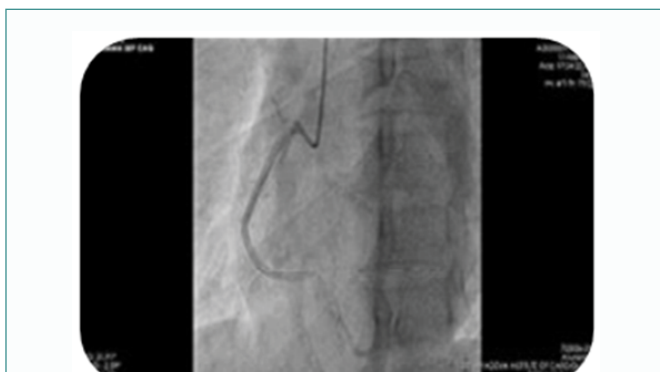


Figure 7: CAG showing distal RCA occlusion.

Excision has to be done carefully, sometimes along with portion of attached Inter Atrial Septum (IAS) to prevent fragmentation and recurrence. Timely Surgery has to be done to avoid complications like mechanical obstruction and systemic embolization. Histopathology post operative will confirm diagnosis of myxoma.

Conclusion

Here, we present case series of unusual presentation of left atrial myxoma as myocardial infarction and peripheral embolization. All three cases presenting with an ST-segment-elevation myocardial infarction caused by coronary embolization of LA myxoma. This sends a message that LA myxoma as embolic source of acute myocardial infarction has to be kept in mind (especially with no florid changes in ECG and distal occlusions of coronary artery in coronary angiography). It reiterates the routine screening by Tran's thoracic ECHO examination before taking up for emergency coronary angiography, even when patient presents with ST elevation myocardial infarction. Surgery is treatment of choice with less chance of recurrence.

References

- Zhang RD, Zeng ZH, Zheng JY, Li TD, Zhao YQ, Liu YH, et al. Left atrial myxoma complicated with multi system embolization. *Thorac Cardiovasc Surg.* 2017;12:76.
- Pineda AM, Mihos CG, Nascimento FO, Santana O, Lamelas J, Beohar N. Coronary embolization from a left atrial myxoma Containing Malignant Lymphoma Cells. *Tex Heart Inst J.* 2015;42(6):565-8.
- Latifi AN, Ibe U, Gnanaraj J. A case report of atrial myxoma presenting with systemic embolization and myocardial infarction. *Eur Heart J Case Rep.* 2019;3(3):1-5.
- Britta V, Dierk T, Derliz M, Wolfgang R, Hugo AK. Systemic embolization and myocardial infarction due to clinically unrecognized left atrial myxoma. *Case Rep Med.* 2011;2011:159024.
- Reynen K. Frequency of primary tumors of heart. *Am J Cardiol.* 1996;77(1):107.
- Rath S, Har-Zahav Y, Battler A, Agranat O, Neufeld HN. Coronary arterial embolus from left atrial myxoma. *Am J Cardiol.* 1984;54(10):1392-3.
- Li AH, Liau CS, Wu CC, Chien KL, Ho YL, Huang CH, et al. Role of coronary angiography in myxoma patients: a 14-year experience in one medical center. *Cardiol.* 1999;92(4):232-5.
- Reynen K. Cardiac myxomas. *N Engl J Med.* 1995;333(24):1610-7.
- Castells E, Ferran V, Octavio de Toledo MC, Calbet JM, Benito M, Fontanillas C, et al. Cardiac myxomas surgical treatment, long term results and recurrence. *J Cardiovasc Surg.* 1993;34(1):49-53.
- Leja MJ, Shah DJ, Reaedon MJ. Primary cardiac tumors. *Tex Heart Inst J.* 2011;38(3):261-2.
- Lehrman KL, Prozan G, Ullyot D. Atrial myxoma presenting as acute myocardial infarction. *AM Heart J.* 1985;110(6):1293-5.
- Erdil N, Ates S, Cetin L, Demirkilic U, Sener E, Tatar H. Frequency of left atrial myxoma with concomitant coronary artery disease. *Surg Today.* 2003;33(5):328-31.
- Abad C. Cardiac tumors general considerations, benign primary tumors. *Rev Esp Cardiol.* 1998;51(1):10-20.
- Al Zahrani IM, Alraqtan A, Rezk A, Almasswary A, Bella A. Atrial myxoma related myocardial infarction case report and review of literature. *J Saudi Heart Assoc.* 2014;26(3):166-9.
- Braun S, Schrötter H, Reynen K, Schwencke C, Strasser RH. Myocardial infarction as complication of left atrial myxoma. *Int J Cardiol.* 2005;101(1):115-21.