

## Case Report

# Cesarean Scar Pregnancy Complicated by Uterine Wall Sequestration

Rybka J, Woźniak S, Paszkowski T and Szkodziak PR

Department of Gynecology, Medical University of Lublin, Poland

## Abstract

The first description of the conservative CSP treatment complication in the form of uterine wall sequestration. This case presents the failure of the CSP conservative treatment with extremely rare outcome in the form of uterine wall sequestration at the site of cesarean scar.

**Keywords:** Cesarean scar pregnancy; Uterine artery embolization; Uterine wall sequestration; Cesarean scar

## Introduction

Pregnancy (CSP) is a potentially life-threatening rare type of ectopic gestation [1-3]. In most of the cases, the uterus-sparing methods are the first-line treatment options for the management of CSP.

This case presents the failure of the CSP conservative treatment with extremely rare outcome in the form of uterine wall sequestration at the site of cesarean scar.

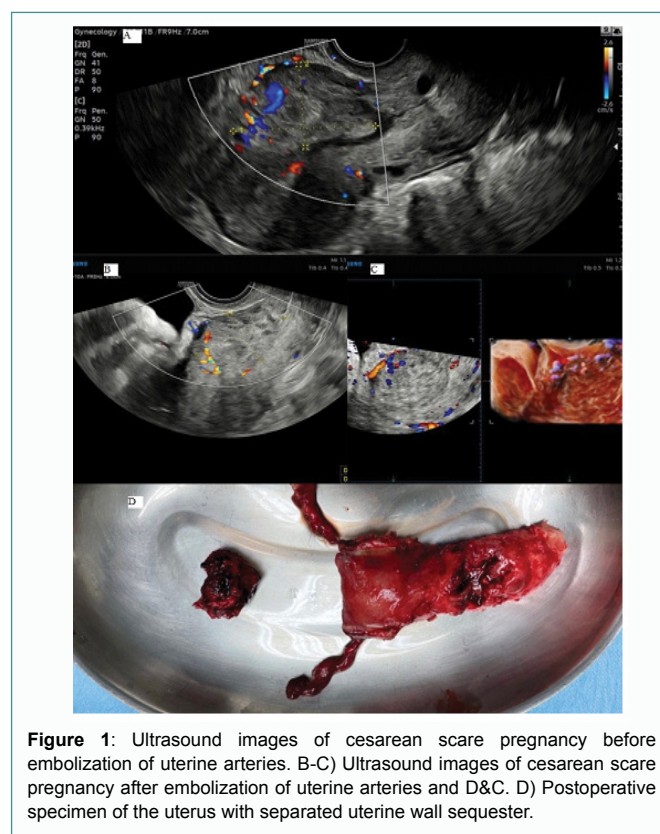
## Case Presentation

A 36-year-old patient with the history of three cesarean sections and hyperthyroidism was transferred from the other hospital to the 3<sup>rd</sup> Chair and Department of Gynecology (University Hospital No. 4, Lublin, Poland) due to suspected incomplete miscarriage at a gestational age of 9 week. Patient was previously treated with Dilation and Curettage (D&C) followed by 100 mg of I.V. methotrexate. Persistent bleeding was noted on admission and beta-hCG level was 4844 mIU/ml. Transvaginal ultrasound showed a highly vascularized structure with dimensions 68 mm × 39 mm within the lower segment of anterior uterine wall. The persistent cesarean scar pregnancy was diagnosed (Figure 1A and B).

The patient was qualified for Uterine Arteries Embolization (UAE) and Subsequent Suction Curettage (SC) under I.V. general anesthesia. On the 1<sup>st</sup> day after the embolization beta-hCG level was 2568 mIU/m and the patient was stable. As suction curettage appeared ineffective, the D&C was performed. Immediately after the curettage patient presented the signs of thyrotoxic crisis, which was successfully pharmacologically treated. On the 8<sup>th</sup> day after embolization, due to persistent bleeding and beta-hCG level of 1618 mIU/ml, the patient was qualified for the subsequent attempt of the products of

conception removal by D&C. Due to profuse bleeding during and after the procedure (decrease in hemoglobin from 13.7 mg/dl to 11.2 mg/dl), the Foley catheter balloon tamponade was used. After six hours the tamponade was removed-the bleeding stopped and beta-hCG decreased to 230 mIU/ml (Figure 1C and D).

The patient was discharged from the hospital on the 13<sup>th</sup> day after UAE with light vaginal bleeding, decreasing hCG levels and normalized thyroid function. Clinical and biochemical monitoring was continued on the out-patient basis. Due to abundant growth of *E.coli* found in vaginal swab, the patient was treated with ciprofloxacin. Due to the persistent vascularized uterine lesion on ultrasound, increased bleeding and plateaued hCG level, the patient was readmitted to the hospital and qualified for surgical treatment (total abdominal hysterectomy with bilateral salpingectomy). The



**Figure 1:** Ultrasound images of cesarean scar pregnancy before embolization of uterine arteries. B-C) Ultrasound images of cesarean scar pregnancy after embolization of uterine arteries and D&C. D) Postoperative specimen of the uterus with separated uterine wall sequestrum.

**Citation:** Rybka J, Woźniak S, Paszkowski T, Szkodziak PR. Cesarean Scar Pregnancy Complicated by Uterine Wall Sequestration. Med Life Clin. 2022; 4(2): 1043.

**Copyright:** © 2022 Justyna Rybka

**Publisher Name:** Medtext Publications LLC

**Manuscript compiled:** Dec 22<sup>nd</sup>, 2022

**\*Corresponding author:** Justyna Rybka, Department of Gynecology, Medical University of Lublin, Poland, E-mail: justyna.rybka@icloud.com

surgery was performed on the 44<sup>th</sup> day after the embolization. After opening the abdominal wall, sequestrum of the anterior uterine wall, approximately 30 mm in diameter, was revealed. At the site of the sequestrum, perforation of the uterine wall was found (Figure 1). The surgery was uneventful. The patient was discharged home in a good general condition on the 3<sup>rd</sup> day after the surgery.

Postoperative histopathological examination of the lower uterine segment revealed necrosis and purulent inflammation of the mucosa and foci of chronic inflammation in the myometrium. Single clusters of trophoblast cells around the vessels and necrotic masses with the signs of perifocal organization suggestive of abnormally adherent placenta were found.

## Conclusion

This to our knowledge the first description of the conservative CSP treatment complication in the form of uterine wall sequestration at the site of cesarean scar. Management of CSP should be individualized and all possible outcomes have to be considered while monitoring the effectiveness of therapy.

## References

1. Timor-Tritsch IE. Cesarean scar pregnancy: a therapeutic dilemma. *Ultrasound Obstet Gynecol.* 2021;57(1):32-3.
2. Yin X, Huang S. Clinical characteristics and treatment of different types of cesarean scar pregnancy. *Ginekol Pol.* 2020;91(7):406-11.
3. Stepniak A, Paszkowski T, Jargiełło T, Czuczwar P. Effectiveness, complications and reproductive outcome of selective chemoembolization with methotrexate followed by suction curettage for cesarean scar pregnancy - A prospective observational study. *Eur J Obstet Gynecol Reprod Biol.* 2019;241:56-9.