

Clinical Image

Chromomycosis - A Clinical Image

Luciano Zogbi*, Camila Juliano and Fábio Andrade

Federal University of Rio Grande (FURG), Brazil

A 76-year-old Caucasian male patient, a farmer, presented with pruritic cutaneous lesions on the right forearm and elbow, which had increased in size over a period of 10 years, without other symptoms. Upon examination, they presented as crusty papules and plaques, erythematous, of different sizes; some were confluent (Panel A). A direct examination and sample culture were negative for fungi and mycobacteria. However, on a biopsy stained with hematoxylin-eosin, the upper and mid-dermis contained a mixed diffuse granulomatous inflammatory infiltrate, with neutrophils, lymphocytes, histiocytes, and multinucleated giant cells granulomas with brown spores (“copper cents”) within (Panel B). These spots consisted of round to polyhedral golden brown fungal cells measuring 5 µm to 12 µm in diameter, divided by septation, classic of chromomycosis. This finding allowed for the diagnosis and treatment with oral itraconazole.

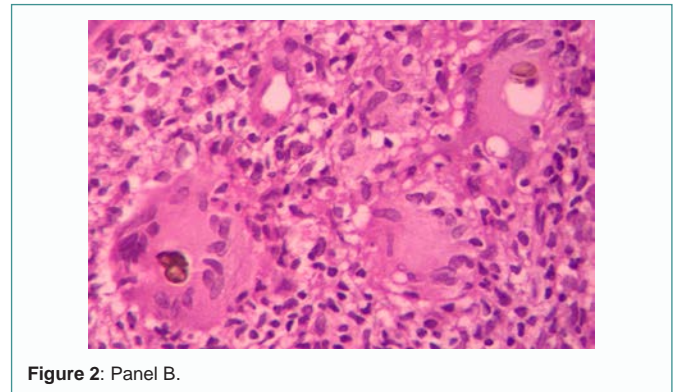


Figure 2: Panel B.

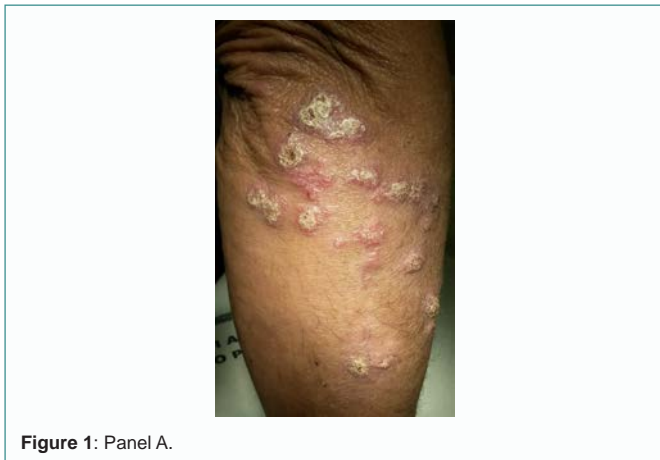

Figure 1: Panel A.

Citation: Zogbi L, Juliano C, Andrade F. Chromomycosis - A Clinical Image. *Ann Clin Image Short Rep.* 2018; 1(2): 1007.

Copyright: © 2018 by the Medtext Publications LLC

Publisher Name: Medtext Publications

Manuscript compiled: April 02nd, 2018

***Corresponding author:** Luciano Zogbi, Federal University of Rio Grande, Visconde de Paranaguá Street, 102. Zip Code: 96203900, Rio Grande City, RS, Brazil, Tel: 55 53 984173416; E-mail: zogbi@furg.br