

Research Article

Colostomy in Children in Maiduguri: An Audit of the Outcome

Wabada S¹, Adamu S², Usman B¹, Abubakar AM¹, Chinda JY¹ and Obiano SK²

¹Department of Surgery University of Maiduguri Teaching Hospital, Nigeria

²Department of Surgery, Federal Teaching Hospital, Nigeria

Abstract

Background: Colostomy is one of the common emergency surgical procedures performed in the paediatric age group. Anorectal malformation and Hirschsprung's disease are common indications for colostomy in children.

Aims and objectives: To determine post operative morbidity and mortality associated with colostomy and colostomy reversal in children in our environment.

Patients and methods: A 9-year retrospective study of all cases of colostomy in children aged ≤ 15 -years. The outcome variables were indications for colostomy, complications associated with colostomy and outcome after reversal. Results were presented as percentages, charts and frequency tables. Fisher's exact test analyzes relationship between categorical variables with P-value of less than 0.05 as significant.

Results: A total 58 patients were reviewed. There were 33 (56.9%) girls and 25(43.1%) boys, ratio 1.3:1. The average duration of the colostomy was 29-months, ranged 1-48 months. Anorectal malformation 40(68.9%) was the commonest indications for colostomy followed by Hirschsprung's disease 13(22.4%) and Intussusception 2(3.4%). Others were perineal burns, sigmoid volvulus, and anastomotic leak. Fifty-five (55.2%) percent had a left transverse colostomy. Common complications associated with colostomy were skin excoriations 45.0% and prolapse 32.5%. No colostomy related death. No significant correlation between duration of colostomy and colostomy related complications, $P=0.095$, $\chi^2=31.263$. Intra peritoneal colostomy closure was performed in all the cases. About 82.8% patients developed superficial surgical site infections, 1.7% died after colostomy reversal.

Conclusion: Skin excoriation and prolapse are the common colostomy related complications, while surgical site infection was the common complication after intra peritoneal colostomy reversal.

Keywords: Colostomy closure; Skin excoriations; Prolapse; Intra peritoneal colostomy reversal

Introduction

A colostomy is the surgical opening between the colon and the anterior abdominal wall for the purpose of diversion of faeces. Since it was first performed in 1710 by Littre in children with anesthesia, colostomy has remained an important life-saving emergency procedure in children [1]. Colostomy is generally indicated in children with congenital conditions such as anorectal malformations and Hirschsprung's diseases and seldom in acquired conditions such as bowel injuries, heavy peritoneal contamination where primary anastomosis may not be feasible [2]. Congenital anomalies usually accounted for about 73.7% of colostomies performed in the paediatric age group and acquired conditions accounted for about 26.3% of cases [3].

This is a single institution retrospective audit of all cases of colostomy, its related morbidity and mortality and the post operative

outcome after reversal in children aged less or equal to 15-years in northeastern Nigeria.

Patients and Methods

A retrospective review of all colostomy cases in children aged ≤ 15 -years between January 2001 and August 2010 was carried out. Only children that had their colostomy done and reversed by us in University of Maiduguri Teaching Hospital (UMTH) were considered for this review. University of Maiduguri Teaching Hospital is a second-generation tertiary referral center in northeast Nigeria that serves a population of about 5.8 million (2016 projection) people. The major outcome variables were indications for colostomy, site and type of colostomy, surgeon's cadre, duration of colostomy, colostomy related complications, type of colostomy reversal and outcome after reversal. Data were obtained from patients' case notes and the operation register. Categorical variables are presented as percentages, charts, and frequency tables. Relationship between categorical variables is analyzed with Fisher's exact test, with P value ≤ 0.05 regarded as significant association. The data were analyzed using SPSS version 23 for windows 10 (SPSS Armonk, NY: IBM Corp).

Results

Overall, about 58 cases of colostomy in children aged 2-days to 7-years were analyzed. All were temporary colostomies. The study had about 33 (56.9%) girls and 25(43.1%) boys, ratio of 1.3:1. The average duration of colostomy was 29-months, ranged 1-48-months. The common indication for colostomy was anorectal malformations 40(68.9%), followed by Hirschsprung's disease 13(22.4%) and Intussusception 2(3.4%). Others were perineal burns, sigmoid

Citation: Wabada S, Adamu S, Usman B, Abubakar AM, Chinda JY, Obiano SK. Colostomy in Children in Maiduguri: An Audit of the Outcome. *Int J Pediatr Surg.* 2022;3(1):1024.

Copyright: © 2022 Wabada S

Publisher Name: Medtext Publications LLC

Manuscript compiled: Apr 14th, 2022

***Corresponding author:** Wabada S, Department of Surgery University of Maiduguri Teaching Hospital, Nigeria, Tel: +234-8052461926; E-mail: wabzigu@yahoo.co.uk

volvulus, and anastomotic leak (Figure 1). Thirty-two (55.2%) patients had a left transverse colon colostomy and 26(44.8%) had a sigmoid colon colostomy. Forty-eight (82.8%) cases of the colostomies were performed by residents, out of which 29(60.4%) were on the left transverse colon. While 10(17.2%) were done by the consultants, of which all were on the sigmoid colon but 1(1.0%). Regarding the type of colostomy, 42 (72.4%) patients had a divided colostomy. Out of which 28(66.7%) were divided left transverse colostomy and 14(33.3%) divided sigmoid colostomy. While 16(27.6%) patients had a loop colostomy. Out of which 12(75.0%) were sigmoid loop colostomy and 4(25.0%) left transverse loop colostomy. Intra-peritoneal colostomy reversal was performed in all cases. The peritoneum was opened through an elliptical skin incision around the colostomy stoma to open the peritoneum before and an end-end anastomosis was performed in one-layer under direct vision. At the time of colostomy reversal about 8(13.8%) patients limited adhesiolysis *via* same incision.

Regarding colostomy related morbidity, about 40(68.9%) cases

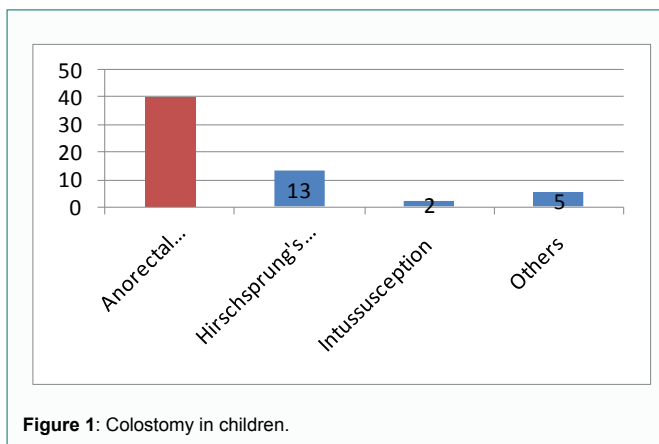


Figure 1: Colostomy in children.

developed various sorts of colostomy related morbidities. These included 18(45.0%) cases of skin excoriations, 13 (32.5%) colostomy prolapses, 7(17.5%) colostomy wound dehiscence, 2(5.0%) para colostomy hernia, and 1(2.5%) intestinal obstruction. No colostomy related mortality. In terms morbidity based onsite of the colostomy, 16(50.0%) cases of skin excoriations, 13(40.6%) of prolapsed, and 7(21.9%) of wound dehiscence respectively occurred in patients that had left transverse colostomy. Which further confirms that colostomy related morbidity is common with left transverse colostomy than sigmoid colostomy (Table 1)? Again, when considering morbidity based on type of the colostomy, about 9(56.3%) cases and 2(12.5%) of loop colostomies respectively prolapsed and dehisced. No significant statistical correlation was found between duration of colostomy and colostomy related morbidities $P=0.095$, $\chi^2=31.263$ (Table 2).

After colostomy reversal, 48(82.8%) patients had superficial surgical site infections that were conservatively managed with saline and honey dressing. While 1(1.7%) patient that had post-operative adhesive acute intestinal obstruction died of aspiration.

Discussion

Colostomy is one of the common surgical procedures performed in children in developing countries [4]. It account for about 4.9%, 5.9% and 2.0% of all surgical procedures performed in children in South Africa, India, and Brazil respectively [5-7]. In the West African sub region colostomy account for about 83.3% of all surgical procedures performed in children [8-11]. And anorectal malformation followed

by Hirschsprung's disease were responsible for about 89.4% and 9.8% of all cases of colostomy performed in these children [12,13]. In our report anorectal malformations and Hirschsprung's were equally responsible for about 68.9% and 22.4% for all cases of colostomies in children in our environment.

There was more 52.2% of cases transverse than sigmoid colostomy in our report, which we observed may be due to experience of the surgeon. As 60.4% of all the 82.8% colostomy cases done by the residents were transverse colostomies. Furthermore, we also observed many of the transverse colostomy cases were done in patients that had Hirschsprung's disease, probably due to long segment aganglionosis. Hence, further accounting for increased numbers of transverse colon colostomies in our report.

In terms of colostomy related morbidity, our report showed many cases of skin excoriations 50.0% and colostomy prolapse 40.6% that was commonly associated with the transverse colostomy and loop colostomy. As like other studies which showed that colostomy related morbidity is commonly associated with transverse colon colostomy and loop colostomy than with sigmoid colon [14-17]. Sheikh et al. [18] had 80.0%cases of skin excoriations and 60.0% colostomy prolapse in children with left transverse colostomy. Acidic nature of the loose transverse colon stools often causes skin irritation attributing to increased risk skin excoriations. Furthermore, certain technical faults in siting colostomy, such as cutting through the muscles instead of muscle-splitting, not narrowing the distal stoma, not hitching the stomas to a fascial plane may also increases the risk of colostomy related complications like colostomy prolapse [19-21].

Overall, our report had a colostomy related morbidity rate of 68.9%, which was higher than similar a report in Lagos, Nigeria that had colostomy related morbidity rate of 40.9%, 22 but lower than the morbidity rate of 81.4% reported by Massenga et al. [23] in Tanzanian Children. This difference between these previous reports and ours could be attributed to differences in sample sizes. Unlike others [24,25], we found no significant difference of association between duration colostomy and colostomy related morbidity.

The outcome of colostomy related morbidities in this report was good. They were no mortality from colostomy related morbidity in our report. No patient warranted admission for the management of colostomy related morbidity. And our cases of skin excoriations improved significantly when the mothers were asked to use Vaseline blue or zinc oxide cream as skin barriers. Coupled with dietary modifications, nutritional rehabilitation, and maternal education on improving personal hygiene. While we manage cases with significant prolapsing colostomies with reduction under sedation and application of thiersch stitch.

The timing for colostomy reversal is highly subjective, depending on indication colostomy in children is usually reversed between 3 to 12 months by then the colon would have been safe for the colostomy to be reversed [26-28]. Nevertheless, in our environment this maybe longer than necessary as observed in this report and of others [29]. Poverty, lack of manpower and long patient waiting operating list were responsible for delayed colostomy reversal in our report.

As a protocol intra-peritoneal approach was our technique of colostomy reversal. This approach allows for anastomosis to be done under direct vision and allows for additional intra operative maneuvers such as adhesiolysis. As observed in our report. Previous reports have associated technique of colostomy reversal with significant

Table 1: Colostomy related complications according to site and type of colostomy.

Variables	Transverse colostomy	Sigmoid colostomy	Divided colostomy	Loop colostomy
	N (%)	N (%)	N (%)	N (%)
Skin excoriation	16(50.0)	2(7.7)	15(35.7)	2(12.5)
Prolapse	13(40.6)	-	4(9.5)	9(56.3)
Wound dehiscence	7(21.9)	-	-	2(12.5)
Para colostomy hernia	-	2(7.7)	-	-
Intestinal obstruction	-	1(2.4)	-	-

Table 2: Comparison of duration of colostomy and colostomy related complications.

Variables	Duration of colostomy in months								df	p-value	χ^2
	6	17	18	24	32	36	38	48			
Complications (N)									21	0.095	27.738
Prolapse	2	-	-	-	-	2	9	-			
Skin excoriations	3	-	1	1	3	4	5	1			
Wound dehiscence	2	1	-	-	-	3	-	1			
Paracolostomy hernia	-	-	-	1	-	1	-	-			

df: degree of freedom; χ^2 : Fisher's exact test

post-operative morbidity and mortality [30]. We have not found major post-operative morbidity following intra-peritoneal reversal in our report. All our cases of superficial surgical site infections after colostomy reversal were conservatively managed as outpatients. Even though about 84.2% of our cases developed surgical site infections, which is high when compared to other studies in the sub region [31]. But our mortality rate of 1.7% is equally like that of others both in the sub region and beyond. Nmadu [32] had a mortality rate of 2.8%, Rosen and Friedman [33] had a mortality rate of 1.4%.

Conclusion

Anorectal malformation and Hirschsprung's disease are the common congenital indications for colostomy in children in our environment and colostomy related morbidity is unrelated to the duration of colostomy. Furthermore, intra-peritoneal colostomy reversal is equally cost effective in terms of morbidity and mortality in children in our environment.

References

- Scharli WF. The history of colostomy in childhood. *Prog Pediatr Surg.* 1986;20:188-98.
- Akiyama H, Ishii K, Kodaira Y, Saeki M. Colostomy in children--with special reference to indication, position and complications. *Nihon Daicho Komonbyo Gakkai Zasshi.* 1971;23(3):32-3.
- Devens K, Pompino HJ. [Colostomy in childhood. Indications, technics, complications]. *Langenbecks Arch Chir.* 1969;325:135-41.
- Osifo OD, Osaigbovo EO, Obeta EC. Colostomy in children: Indications and common problems in Benin City, Nigeria. *Pak J Med Sci.* 2008;24(2):199-203.
- Botchway MT, Kruger D, Manful CA, Grieve A. The scope of operative general paediatric surgical diseases in South Africa- the Chris Hani Baragwanath experience. *Ann Pediatr Surg.* 2020;16:44.
- Bhosale MN, Soni V. Audit of paediatric surgical services in a Tertiary Care Hospital in Maharashtra, India. 2019;7(7):415-24.
- Rosalino R, Martelli N, Novo NF, Franca WM. Epidemiological study of paediatric surgery at Regional Hospital of Sorocaba between 2008 and 2012 by a single surgeon. *Surg Sci.* 2017;8(8):375-83.
- PaedSurg Africa Research Collaboration. Paediatric surgical outcomes in sub-Saharan Africa: a multicenter, international, prospective cohort study. *BMJ Global Health.* 2021;6:e004406.
- Ameh EA, Mshelwala PM, Sabiu L, Chirdan LB. Colostomy in children--an evaluation of acceptance among mothers and care givers in a developing country. *S Afr J Surg.* 2006;44(4):138-9.
- Anyanwu LJ, Mohammed A, Oyebanji T. A descriptive study of commonly used postoperative approaches to paediatric stoma care in a developing country. *Ostomy Wound Manage.* 2013;59(12):32-7.
- Ekenze SO, Agugua-Obianyo NEN, Amah CC. Colostomy for large bowel anomalies in children: A case-controlled study. *Int J Surg.* 2007;5(4):273-7.
- Wiersma R. HIV-positive African children with rectal fistulae. *J Pediatr Surg.* 2003;38(1):62-4.
- Ameh EA, Chirdan LB, Dogo PM, Nmadu PT. Hirschsprung's disease in the newborn: experience in Zaria, Nigeria. *Ann Trop Paediatr.* 2001;21(4):339-42.
- Mollitt DL, Malangoni MA, Ballantine TV, Grosfeld JL. Colostomy complications in children. An analysis of 146 cases. *Arch Surg.* 1980;115(4):445-58.
- Millar AJ, Lakhoo K, Rode H, Ferreira MW, Brown RA, Cywes S. Bowel stomas in infants and children. A 5-year audit of 203 patients. *S Afr J Surg.* 1993;31(3):110-3.
- Shabbir J, Britton DC. Stoma complications: a literature overview. *Colorectal Dis.* 2010;12(10):958-64.
- Oda O, Davies D, Colapinto K, Gerstle JT. Loop versus divided colostomy for the management of anorectal malformations. *J Pediatr Surg.* 2014;49(1):87-90.
- Sheikh MA, Akhtar J, Ahmed S. Complications/problems of colostomy in infants and children. *J Coll Physicians Surg Pak.* 2006;16(8):509-13.
- Ameh EA. Colostomy in the newborn: Technical pitfalls. *Niger Postgrad Med J.* 2002;9(4):240-2.
- Kholer A, Athanasiadis S, Nafe M. [Postoperative results of Colostomy and ileostomy closure: a retrospective analysis of three different closure techniques in 182 patients]. *Chirurg.* 1994;65(6):529-32.
- Cigdem MK, Onen A, Duran H, Ozturk H, Otçu S. The mechanical complications of colostomy in infants and children: analysis of 473 cases of a single center. *Pediatr Surg Int.* 2006;22(8):671-6.
- Dode CO, Gbobo LI. Childhood colostomy and its complications in Lagos. *East and Central Afr J Surg.* 2001;6(1):25-9.
- Massenga A, Chibwae A, Nuri AA, Bugimbi M, Munisi YK, Mfinanga R, et al. Indications for and complications of intestinal stomas in the children and adults at a tertiary care hospital in a resource-limited setting: a Tanzanian experience. *BMC Gastroenterol.* 2019;19(1):157.
- Chandramouli B, Srinivasan K, Jagdish S, Ananthakrishnan N. Morbidity and mortality of colostomy and its closure in children. *J Pediatr Surg.* 2004;39(4):596-9.
- Chirdan LB, Uba FA, Ameh EA, Mshelwala PM. Colostomy for high anorectal malformation: an evaluation of morbidity and mortality in a developing country. *Pediatr Surg Int.* 2008;24(4):407-10.
- Sola JE, Bender JS, Buchman TG. Morbidity and timing of colostomy closure in trauma patients. *Injury.* 1993;24(7):438-40.

27. Freund HR, Raniel J, Muggia-Sulam M. Factors affecting the morbidity of colostomy closure: a retrospective study. *Dis Colon Rectum*. 1982;25(7):712-5.
28. Doberneck RC. Revision and closure of the colostomy. *Surg Clin North Am*. 1991;71(1):193-201.
29. Adejuyigbe O, Abubakar AM, Sowande OA, Olayinka OS, Uba AF. Experience with anorectal malformations in Ile-Ife, Nigeria. *Pediatr Surg Int*. 2004;20(11-22):855-8.
30. Chalya PL, Mabula JB, Kanumba ES, Giiti G, Chandika AB, Gilyoma JM. Experiences with childhood colostomy at a tertiary hospital in Mwanza, Tanzania. *Tanzania J Health Res*. 2011;13(3):224-35.
31. Adeyemo A, Gaillard WE, Ali SD, Calhoun T, Kurtz LH. Colostomy, Intra peritoneal or extraperitoneal closure? *Am J Surg*. 1975;130(3):273-4.
32. Nmadu PT. Complications of colostomy closure in Zaria, Nigeria A report of 70 cases. *Cent Afr J Med*. 1990;36(11):287-91.
33. Rosen L, Friedman IH. Morbidity and mortality following intra peritoneal closure of transverse loop colostomy. *Dis Colon Rectum*. 1980;23(7):508-12.