

## Case Report

# Conservative Treatment with Anastomotic Leakage

**Haitham Saimeh\***

Department of General Surgery and Oncology, King Faisal Specialty Hospital, Jeddah, Saudi Arabia

## Abstract

Despite the great advances encountered in the medical field, yet anastomotic leaks remain the major cause of morbidity and mortality post colorectal surgeries. Anastomotic leaks still remain as major threat that surgeons tend to encounter frequently, it is associated with several risk factors as patients' history, underlying comorbidities, as well as the surgical procedure done. There are no fixed criteria on anastomotic leak management yet early diagnosis and interventions are considered to be the main treatment plan strategy followed. A case that was presented and treated as with postoperative anastomotic leakage dealt with conservative intervention including postoperative drainage, antibiotics administration in order to prevent any further peritoneal spread.

**Keywords:** Postoperative anastomotic leakage; Conservative approach; Postoperative complication management; Surgical complications; CT scan

## Introduction

Colorectal anastomotic leak is still the most feared gastrointestinal complication, although great interventions taken in the preoperative and postoperative field. Although anastomotic leaks are a major complication yet there is no set agreement and consensus on a specific treatment and management protocol [1]. Anastomotic leak complication is linked to hospital burden, as well as increasing the number of days a patient will be hospitalized postoperatively, thereby increasing the risk of encountering other source of infection. Colorectal anastomotic leaks are defined as a defect in the intestinal wall at the anastomotic site leading to a communication between intra and extraluminal compartments, for a clinical decision making process; anastomotic leaks should be graded in order to manage the severity of the complication [2]. Surgeons should set a clear diagnostic criterion involving both radiologic as well as clinical features in order to have a clear treatment plan.

Based on a previous research conducted results showed that the incidence of anastomotic leak among 190 patients was 7.9% which corresponds to 15 patients [3]. Variations among patients occur depending on their national status, physical activity, body weight, and age. Currently, the clinical picture of the patient postoperatively guides the surgeon on what approach to follow so if the patient is showing unstable vital signs, immediate operative procedures should be done, but if the patient is vitally stable then conservative interventions is done.

## Case Presentation

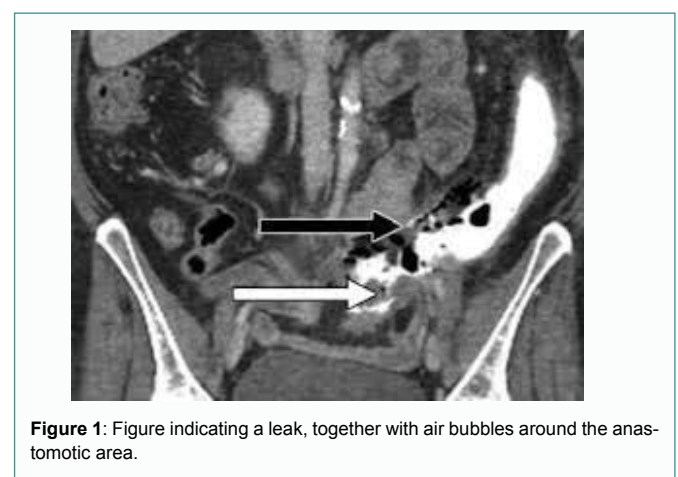
At the Colorectal Surgery Department of a tertiary hospital we reported a unique case of 69 years old, gentleman, was fully investigated and diagnosed in a tertiary hospital as left colon cancer,

splenic flexure in 2018. The patient underwent lap left hemicolectomy converted to open due to adhesions. In the post-operative course, the patient had the symptoms and signs of anastomotic leak tachycardia, with abdominal tenderness. CT Abdomen and pelvis showed contrast outside the colon, and collection around the anastomosis, as shown in Figure 1.

The patient was treated conservatively, NPO, TPN, and covered with IV antibiotics for almost 10 days, as the patient was not septic with stable vital signs. The patient improved on conservative management, and he did not need further surgery for the anastomotic leak. He was discharged in a good general condition. On regular clinic follow-up, the clinical examination is normal. Repeated CT scan abdomen was normal without collection and no signs of intra-abdominal leak, scope were done for the patient, and it was normal, intact anastomotic area, as indicated in Figure 2.

## Discussion

Based on studies conducted, anastomotic leaks incidence ranges from 1.8% to 10.4% [4]. Therefore, it greatly impacts the patient's well being postoperatively. Several case reports exist in the literature of anastomotic leak, however, it varies from one case to another what approach should be followed in order to treat the leakage. Methods of treating postoperative anastomotic leaks vary based on the patients' history and presenting clinical symptoms, but always strict follow up postoperatively is highly recommended to avoid any source of further



**Figure 1:** Figure indicating a leak, together with air bubbles around the anastomotic area.

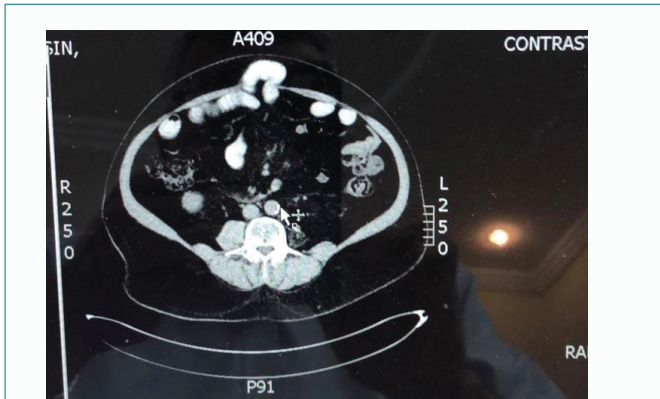
**Citation:** Saimeh H. Conservative Treatment with Anastomotic Leakage. Am J Surg Tech Case Rep. 2020;1(2):1007.

**Copyright:** © 2020 Haitham Saimeh

**Publisher Name:** Medtext Publications LLC

**Manuscript compiled:** July 21<sup>st</sup>, 2020

**\*Corresponding author:** Haitham Saimeh, Department of General Surgery and Oncology, King Faisal Specialty Hospital, Jeddah, Saudi Arabia, E-mail: haithamsaimeh@yahoo.com



**Figure 2:** This figure was taken after the leak was treated conservatively, no airbubbles, nor collection was found.

contamination that may further lead to encountering a septic shock that greatly deteriorates the patient's well-being.

In my case, the patient was operated with laparoscopic left hemicolectomy, because of multiple intraperitoneal adhesions, anastomosis was done by GIA without torsion, with adequate good blood supply. The patient profile showed that he was not anemic, Hemoglobin level =12 mg/dl with normal albumin level of 40 mg/dl, and no any previous cardiac problems. Day two postoperatively, the patient presented with tachycardiac {heart rate 110-115 beats per minute}, abdominal pain and nausea.

CT scan was done, and it revealed anastomotic leak plus collection. In Figure 1 Patient blood profile showed that the patient was aseptic, stable vital signs, afebrile, WBC count of 12. When abdominal examination was conducted, the abdomen showed tenderness in the left side of the abdomen, no rigidity. Therefore, after diagnosing the patient both clinically and with advanced CT scan the decision was to choose the conservative treatment approach, keep NPO, TPN and strict fill. Following conservative approach the patient is given broad spectrum antibiotics.

After fifteen days postoperatively, CT scan was repeated (Figure 2) and showed minimal collection, together with abdominal drain was almost null, therefore the TPN was stopped gradually, tachycardia improved {heart rate 90 beats per minute}, afebrile, and the patient no longer complained of abdominal pain, physical abdominal examination revealed no abdominal tenderness. Drainage was removed, and the patient was discharged in a general good condition, without any surgical intervention. The patient had OPD follow up, scope was done one year postoperatively, showed normal anastomosis without any masses.

## Conclusion

Not every anastomotic leak needs surgery. We must depend on the clinical examination of the patient. If the patient is not septic, with stable vital signs, we can offer him all the best of conservative treatment, which will help in avoiding another surgery. We do not depend only on radiological findings; clinical examination of the patient is the most important and valid point in deciding to go for surgery or not.

## References

1. Blumetti J, Abcarian H. Management of low colorectal anastomotic leak: Preserving the anastomosis. *World J Gastrointest Surg.* 2015;7(12):378-83.
2. Sparreboom CL, Wu ZQ, Ji JF, Lange JF. Integrated approach to colorectal anastomotic leakage: Communication, infection and healing disturbances. *World J Gastroenterol.* 2016;22(32):7226-35.
3. Tai JD, Liu YS, Wang GY. Risk factors and the management of anastomotic leakage after anus-preserving operation for rectal cancer. *Zhonghua Wei Chang Wai Ke Za Zhi.* 2007;10(2):153-6.
4. Hayden DM, Mora Pinzon MC, Francescatti AB, Saclarides T. Patient factors may predict anastomotic complications after rectal cancer surgery: Anastomotic complications in rectal cancer. *Ann Med Surg (Lond).* 2015;4(1):11-6.