

Case Report

Endoperiodontal Lesion: Clinical Case Report

Bruna Genari¹, Rayara dos Santos Goncalves², Breno Dias do Vale², Roberto Carlos Abadia de Oliveira², Felipe Weidenbach Degrazia¹ and Bruna Frizon Greggianin^{1*}

¹Department of Dentistry, University of Brasilia, Brazil

²Dentist, Brazil

Abstract

Background: The term endoperiodontal lesion or endo-perio is used to describe lesions which inflammatory products are found both in the periodontium and in the pulp. Due to this endodontic and periodontal interrelation, several classifications of endo-periodontal lesion changes have been described, and for years the one that was most used were based on the disease's etiological sequence. The current "Classification of Periodontal and Peri-implant Diseases and Conditions (2017)" stands out for reflecting the current clinical condition of the lesion, overcoming the problem of using the "history of the disease" as the main criterion.

Objective: To evaluate the healing of an endoperiodontal lesion with periodontal treatment prior to endodontics treatment.

Case report: Treatment of an endoperiodontal lesion in lower molar performed through supra and subgingival basic non-surgical periodontal therapy initially. After, endodontic treatment including three sessions of intracanal medication and subsequent obturation of root canal were performed.

Results: It was possible to observe regression of periodontal probing depth, dental mobility and radiographic bone repair of the endoperiodontal lesion.

Conclusion: There was clinical success when periodontal treatment was performed prior to endodontic treatment since the aim of therapy is to treat the two origins of injury.

Keywords: Periapical periodontitis; Periodontitis; Regenerative endodontics

Introduction

Endoperiodontal lesion or endo-perio is used to describe lesions which inflammatory products are found both in the periodontium and in the pulp. This interrelation between periodontal disease and pulpal diseases was first described by Simring and Goldberg [1].

Periodontal and pulpal structures are anatomically related through apical foramina, dentinal tubules, apical foramen, lateral, accessory, and secondary canals. These means of communication are responsible for the transmission of pathological processes from one structure to another, thus giving rise to the possibility of a pulpal disease having its periodontal origin, as well as occurring inversely, since its microbiota is variable and mixed, with a predominance of microorganism's strict aerobes. In addition to the interrelation of microorganisms, factors such as trauma, root resorption, dental malformations and perforations can trigger endo-periodontal lesions [1].

Due to this interrelationship between root canals and the periodontium, several classifications of endoperiodontal alterations have been described. For years, the most used was based on the etiological sequence of the disease. Based on this concept, lesions were classified as primary endodontic lesion, primary periodontal

lesion, primary endodontic lesion with secondary periodontal involvement, primary periodontal lesion with secondary endodontic involvement and true endoperiodontal lesion [2]. This classification was widely used, but many of the clinical characteristics of each type overlap with endodontic and periodontal lesions, which make the differential diagnosis difficult and, consequently, its treatment and prognosis [2]. In a study with the purpose of evaluating the knowledge of endodontists, it was observed that the lowest rate of correct answers was true endo-periodontal lesion (35%) followed by primary endodontic lesion with secondary periodontal involvement (40%) and primary endodontic lesion (68%) [3].

The current Classification of Periodontal and Peri-implant Diseases and Conditions (Chicago Classification, 2017) [4] defines endoperiodontal lesions as a pathological communication of pulpal and periodontal tissues in a given tooth, which can occur acutely or chronically. This condition is characterized by deep periodontal pockets extending to the root apex and/or by a negative or altered response to the pulp vitality test. Other possible signs and symptoms include evidence of radiographic bone loss in the apical or furcation region, pain spontaneously or on palpation/percussion, purulent exudate/suppuration, tooth mobility, fistula, color changes in the crown of the tooth and/or gingiva. In this classification, endoperiodontal lesions are now classified into endoperiodontal lesions with root damage (perforation of the root canal or pulp floor, root fracture, and external root resorption), endoperiodontal lesions in patients with periodontitis, and endoperiodontal lesions in patients without periodontitis. Lesions in patients with or without periodontitis can still be divided into grade 1, 2 and 3, in which grade 1 is equivalent to the clinical situation of a narrow and deep periodontal pocket on a root surface, grade 2 with a wide and deep periodontal pocket on a root surface and grade 3 corresponds to the presence of deep periodontal pockets on two or more root surfaces.

From this perspective, anamnesis and thorough clinical

Citation: Genari B, dos Santos Goncalves R, do Vale BD, Abadia de Oliveira RC, Degrazia FW, Greggianin BF. J Clin Pharmacol Ther. 2023;4(2):1041.

Copyright: © 2023 Bruna Genari

Publisher Name: Medtext Publications LLC

Manuscript compiled: Apr 28th, 2023

***Corresponding author:** Bruna Frizon Greggianin, Department of Dentistry, Faculty of Health Sciences, University of Brasilia, Brasilia, 7036306, Brazil, Tel: +55-61-99830-3335; E-mail: bruna.greggianin@gmail.com

examinations are indispensable for the correct diagnosis. The main factors to be observed are the pulp vitality, the type and extension of the periodontal defect [5]. Radiographic examination is essential as a complement to clinical examinations, as it allows checking the integrity of periodontal and periapical tissues and their long-term preservation. The correct diagnosis is essential in determining the etiological factors of the disease, as well as in choosing the appropriate modality and sequence of treatment to eliminate the bone defect caused by it. As well as the adequacy of the classification of endoperiodontal lesions, with reflection on the current state of the condition, studies are needed to evaluate different alternatives for the treatment of endoperiodontal lesions.

The objective of this article is to evaluate the healing of an endoperiodontal lesion with periodontal treatment prior to endodontic treatment. The hypothesis is that the established order of treatment may not be decisive in the healing of endoperiodontal lesions.

Case Presentation

The clinical case was approved by the Research Ethics Committee of the Centro Universitário do Distrito Federal UDF under number CAAE 18070319.3.0000.5650.

Female patient, 25 years old, attended the dental clinic of the University Center of Federal District (UDF) for dental care, complaining of having felt pain in a tooth in the lower left area for some time. During the anamnesis, the patient denied systemic alterations and allergy to medications and reported having poor oral hygiene, which was verified at the clinical examination, with an O'Leary stained plaque index (1972) [6] of 84.2% performed with a plaque (Eviplac®, Ibioporá, Paraná, Brazil) and generalized gingivitis (bleeding on probing above 30%) [4]. Periodontal examination showed mobility grade [2], when the crown of the tooth moves up to one millimeter in any direction [7-10], subgingival calculus, bleeding rate on probing of 52.56%, and probing depth of 5 mm located on the mesiobuccal surfaces and disto-vestibular of tooth 36 (Table 1) and diagnosis, according to the Classification of Periodontal and Peri-implant Diseases and Conditions, of Stage II, Localized Periodontitis, Grade A. A buccal fistula was observed in tooth 36 accompanied by an amalgam restoration on the occlusal surface (Black Class I) and negative response to the thermal test with refrigerated gas (ENDO-ice®, Maringá, Paraná, Brazil). In the radiographic examination, an extensive radiolucent area was observed involving the mesial and distal roots of tooth 36 (Figure 1). From the clinical and radiographic findings, the presence of an endoperiodontal lesion was confirmed in a patient with periodontitis, grade 3-deep periodontal pockets on two or more root surfaces (Probing Depth of 5 mm at the mesio-buccal and distobuccal sites) [4].

Given the diagnosis, the planning of the clinical case was initiated by adapting the oral environment with prophylaxis and individualized oral hygiene instructions, supragingival scaling with ultrasound (Dabi

Table 1: Periogram tooth 36.

	MB	B	DB	ML	L	DL
Probing Depth	5	4	5	5	4	4
Clinical Attachment Loss	7	5	6	7	5	5
Bleeding on Probing	yes	yes	yes	yes	yes	yes
Furca Lesion	-	II	-	-	II	-
Mobility	2					

MB: Mesiobuccal; B: Buccal; DB: Distobuccal; ML: Mesiolingual; L: Lingual; DL: Distolingua

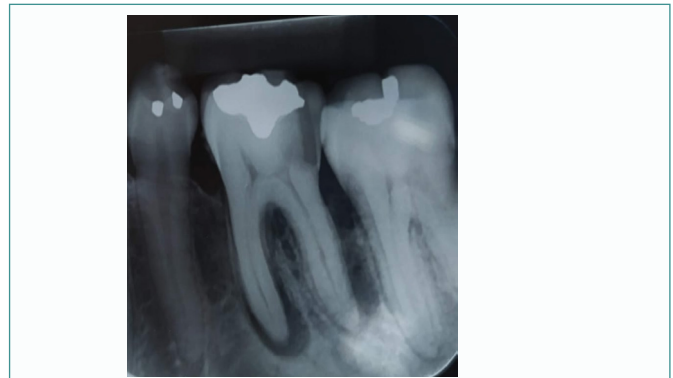

Figure 1: Initial radiograph of tooth 36 with extensive radiolucent area involving the roots.

Atlante®, Londrina, PR, Brazil) and Gracey curettes (Golgran®, São Caetano do Sul, São Paulo, Brazil). After treatment of gingivitis, subgingival scaling was performed with Gracey curettes under local anesthesia, Mepivacaine HCl 2% with epinephrine 1:100,000 (DFL®, RJ, Brazil).

Fourteen days after completion of subgingival scaling, endodontic treatment of tooth 36 was started. Purulent exudate drained from the coronal opening. Odontometry was performed (distobuccal canals: 23 mm, mesiobuccal canals: 21 mm, distolingual canals: 21 mm and mesiolingual canals: 21 mm), followed by chemical-mechanical preparation using irrigation with 2.5% hypochlorite (Asfer®, São Caetano do Sul, SP, Brazil) and instrumentation with Protaper rotary system (Dentisply®, Petrópolis, RJ, Brazil) up to F2 in all conduits. The intracanal medication used was a paste composed of PA calcium hydroxide (Biodinam®, Ibioporá, PR, Brazil), propylene glycol (Medalha Milagrosa compounding pharmacy, Cristalina, GO, Brazil) and iodoform (Biodinam®, Ibioporá, PR, Brazil) (Figure 2A), taken to the conduits with the help of lentulo files (Dentisply®, Petrópolis-RJ, Brazil). Then, the cavity was temporarily sealed with zinc oxide and eugenol (IRM®, Dentisply, Petrópolis, RJ, and Brazil). After 14 and 21 days, the medication was changed with PA calcium hydroxide paste, propylene glycol and iodoform and temporary sealing of the cavity with zinc oxide and eugenol (Figure 2B).

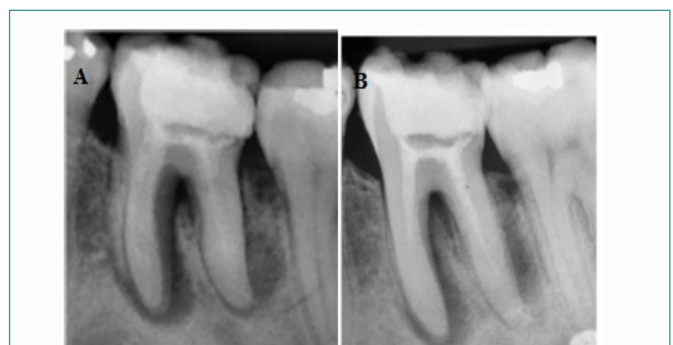

Figure 2: (A). Radiograph of tooth 36 after intracanal medication (14 days). (B). Change of intracanal medication (21 days).

The patient returned after 4 months with no fistula and no symptoms. Tooth mobility went from grade 2 to grade 1, and considerable regression of the lesion was observed on radiography (Figure 3A). The root canals were filled with gutta-percha F2 by Protaper (Dentisply®, Petrópolis, RJ, Brazil) and MTA Fillapex cement (Angelus®, Londrina, PR, Brazil), in addition to provisional restoration

with glass ionomer (FGM®, Joenville, SC, Brazil) (Figure 3B).

The follow-up consultation at 6 months showed no fistula and any symptoms, reduced mobility to grade 1, reduced probing depth from 5 mm and 4 mm to 2 mm, and radiographically observed bone gain.

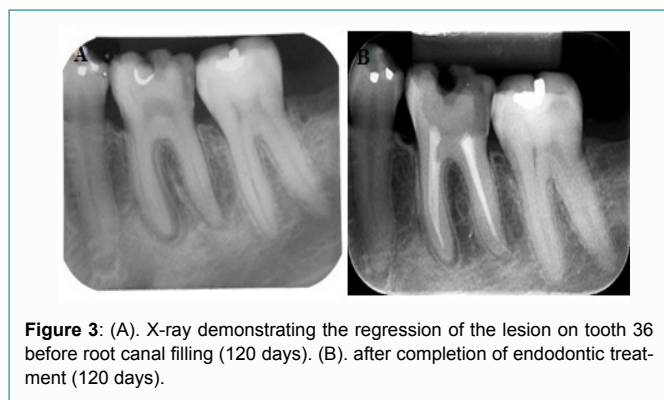


Figure 3: (A). X-ray demonstrating the regression of the lesion on tooth 36 before root canal filling (120 days). (B). after completion of endodontic treatment (120 days).

Discussion

The present clinical case demonstrates the therapeutic success of a lesion of endo-perio genesis given by periodontal treatment followed by root canal. One scope complements the other in order to achieve the disinfection and repair of the entire system involved.

Endoperiodontal lesions need to be classified with reference to signs and symptoms, such as the presence of fractures, perforations and periodontitis, which directly influences their treatment and prognosis. These lesions have a low frequency in clinical practice, but still pose a great test of knowledge for the dental surgeon, and these lesions occupy a category that should be discussed because they affect the prognosis of the tooth. Therefore, this clinical condition is considered one of the greatest challenges in the clinical routine, as it requires meticulous care, from diagnosis to treatment, since the correct diagnosis associated with the relevant treatment are the factors responsible for the success of the therapy [10].

In this condition, the individualized and thorough diagnosis of these lesions of endodontic and periodontal origin is a challenge, and at the same time, the fundamental key to establishing an adequate treatment. The differentiation of a lesion solely of endodontic or periodontal origin can be seen in pulp vitality tests or in periodontal examinations, probing depth and extension of the periodontal pocket, which may be allied to the percussion test [11]. The primary signs associated with this lesion are deep periodontal pockets extending to the root apex and/or negative or altered response to pulp vitality tests. Other signs and symptoms may include radiographic evidence of bone loss in the apical or furcation region, pain spontaneously or on palpation or percussion, purulent exudate or suppuration, tooth mobility, sinus tract or fistula, and changes in color of the crown and/or gingiva. It is necessary to choose the correct diagnostic tests, as well as to accurately interpret the results, ensuring a good treatment prognosis [12].

Combined endodontic and periodontal therapy promote successful healing of an endo periodic lesion [13,14]. This is because, if there are bacteria in the root canal, there may be an inflammatory resorption, resulting in exposure of periodontal tissues, putting them in contact with toxic medications used in the canal. Early endodontic treatment in endo-perio therapy allows the cementum layer to be kept intact, reducing the chances of possible root resorption. In an

acute situation, treatment must mandatorily be initiated by the system causing the pain or edema, that is, the primary disease must be treated initially and then proceed with the treatment of the secondary lesion. There is also the possibility of simultaneous treatment, when there is a diagnosis of combined lesion [11].

In the present study, the medication of choice for the treatment was calcium hydroxide, which has the ability to activate tissue enzymes such as alkaline phosphatase, which favor tissue restoration by mineralization. The pH value for activating this enzyme ranges from 8.6 to 10.3, which facilitates the release of organic phosphate (phosphate ions), which react with circulating calcium ions, creating a sediment of calcium phosphate in the organic matrix [11]. In this range, the high pH of calcium hydroxide with values reaching 12.6, which is caused by the release of hydroxyl ions, is capable of altering the integrity of the bacterial cytoplasmic membrane, resulting in the antimicrobial effect associated with mineralization. It is necessary to allow time for the calcium hydroxide paste to perform its action potential in endodontic infections [11,15]. Guimaraes, et al. [16] advocates that the ideal use of the delay dressing with calcium hydroxide in teeth with pulp necrosis should be carried out after at least 15 days, as performed in the present study.

With regard to periodontal treatment, supra and subgingival coverage must be performed. Periodontal treatment aims at restoring health and periodontal reconstruction, and may use bone graft and reconstruction of papillary aesthetics as a device [17].

Conclusion

With the treatment and follow-up of the present case, it is possible to conclude that there is clinical success when periodontal treatment is performed before endodontic treatment, since the primary need for therapy of an endoperiodontal lesion is to treat the two origins of the lesion.

References

1. Simring M, Goldberg M. The pulpal pocket approach: retrograde periodontitis. *J Period.* 1964;35:22-48.
2. Santos ACB, Lins CCdSA. Decision-making in the diagnosis and treatment of endoperiodontal lesions by endodontists in the city of Maceió-2007. *Int J Dent.* 2008;6(3):80-5.
3. Storrer CM, Bordin GM, Pereira TT. How to diagnose and treat periodontal-endodontic lesions? *RSBO.* 2012;9(4):427-33.
4. Steffens JP, Marcantonio RAC. Classification of Periodontal and Peri-implant Diseases and Conditions 2018: Practical Guide and Key Points. *Rev Odontol UNESP.* 2018;47(4):189-97.
5. Dahlen G. Microbiology and treatment of dental abscesses and periodontal-endodontic lesions. *Periodontol 2000.* 2002;28:206-39.
6. O'Leary TJ, Drake RB, Naylor JE. The plate control record. *J Periodontol.* 1972;43(1):38.
7. Miller CC, Dyes AB, Hutchinson CA Jr. The Estimation of Permeability and Reservoir Pressure from Bottom Hole Pressure Build-Up Characteristics. *J Pet Technol.* 1950;2(04):91-104.
8. Gomes BPFA, Berber VB, Kokaras AS, Chen T, Paster BJ. Microbiomes of endodontic-periodontal lesions before and after chemomechanical preparation. *J Endod.* 2015;41(12):1975-84.
9. Xia M, Qi Q. Bacterial analysis of combined periodontal-endodontic lesions by polymerase chain reaction denaturing gradient gel electrophoresis. *J Oral Sci.* 2013;55(4):287-91.
10. Al Attas MA, Edrees HY, Sammani AMN, Madarati AA. Multidisciplinary management of concomitant pulpal and periodontal injury: A case report. *J Taibah*

- Univ Med Sci. 2017;12(5):455-60.
11. Estrela C, Holland R. Calcium hydroxide: study based on scientific evidences. *J Appl Oral Sci.* 2003;11(4):269-82.
 12. Sartori S, Silvestri M, Cattaneo V. Endoperiodontal lesion: A case report. *J Clin Periodontol.* 2002;29(8):781-3.
 13. Christie WH, Holthuis AF. The endo-perio problem in dental practice: diagnosis and prognosis. *J Can Dent Assoc.* 1990;56(11):1005-11.
 14. de Lima Dantas LTB, Carvalho IF, Lima DVdSC, da Silva Ribeiro M, Martins ÂG, Cerqueira JDM. Current approaches to the diagnosis and treatment of endoperiodontal lesions. *J Dent Public Health.* 2019;10(2):135-146.
 15. Holland R, Merida Delgado RJ, Souza Vd. Are tunnel-shaped defects in dentin bridges exclusive to the use of calcium hydroxide? *Rev Ciênc Odontol.* 2001:51-56.
 16. Guimaraes KB, Post LK, Bezerra MF, Isolan CP, Hosni ES. Parendodontic surgery with simultaneous obturation of root canals: case report. *Rev Ciênc Méd Biol.* 2006;5(2):188-94.
 17. Miao H, Chen M, Otgonbayar T, Zhang SS, Hou MH, Wu Z, et al. Papillary reconstruction and guided tissue regeneration for combined periodontal-endodontic lesions caused by palatogingival groove and additional root: a case report. *Clin Case Rep.* 2015;3(12):1042-9.