

Research Article

Eplerenone in the Central Serous Chorioretinopathy Chronic Experience of the Military Teaching Hospital, Rabat

Mehdi Khamaily*, Joumany Brahim Salem, Imane Tarib, Dahi Sidi, Salma Bajjouk, Rachid Zerrouk, Yassine Mouzari, Fouad El Asri, Karim Reda and Abdelbarre Oubaaz

Department of Ophthalmology, Mohammed V Military Teaching Hospital, Morocco

Abstract

Central serous chorioretinitis is a relatively common eye condition. It is a maculopathy of the young subject, characterized by the presence of a retinal serous detachment, usually located at the posterior pole, associated with changes in the pigment epithelium.

Materials and methods: A prospective study was conducted between Mars 2018 and Mars 2020 at the Mohammed V military hospital in Rabat, in 11 patients treated with Eplerenone for a chronic CRSC evolving for at least 3 months with repercussions on visual acuity, at the dose of 25 mg per day the first week, then 50 mg per day for an average treatment duration of 15 weeks. For each patient, visual acuity and macular OCT (central thickness of the retina) were evaluated before treatment and at 1, 3 and 6 months.

Results: The mean age of the patients was 32.54 ± 6.78 . 11 men. All patients were under stress, and just two patients reported the notion of taking corticosteroids. The average duration of progression of the pathology before treatment was 20 weeks. A clear improvement in visual acuity (logMAR) was observed in 9 patients: mean visual acuity increased from 0.7 at admission to 0.69 at 1 month ($p=0.014$), 0.4 at 3 months ($p=0.013$) and 0.28 at 6 months ($p=0.025$).

The mean central macular thickness decreased from $423 \pm 91 \mu\text{m}$ before treatment, $317 \pm 82 \mu\text{m}$ at 1 month and $292 \pm 73.6 \mu\text{m}$ at 3 months and $251 \pm 94 \mu\text{m}$ at 6 months ($p=0.026$, 0.01 and 0.038 respectively). 5 patients had a complete disappearance of SRF at 3 months. 1 other patient had a complete disappearance of the DSR at 6 months. The treatment was stopped for 3 patients, including 1 at 4 weeks for severe muscle cramps, and hyperkalemia for the 2 others at 10 weeks and 11 weeks of treatment.

Conclusion: In our study, the introduction of Eplerenone resulted in significant improvement in both anatomical and functional outcomes in patients with chronic CSCR.

Keywords: Chronic central serous chorioretinitis; Eplerenone; Sub-retinal fluid; Mineralocorticoid receptor

Introduction

Central serous chorio-retinopathy was first described in 1866 by Von Graefe, under the name of "recurrent central retinitis" [1]. With the fluorescein angiography, Gass showed in 1967 that there was a vanishing point in the Retinal Pigment Epithelium (RPE) and a diffusion of the contrast agent in the sub-retinal space from the choroid [2]. He therefore hypothesized that RPE and the choroid were the tissues responsible for the disease, and used for the first time the term "central serous chorio-retinitis" to define it.

It was only later, once the hypothesis of inflammatory etiology was formally abandoned, that the term "central serous Chorioretinopathy" was used to designate this pathology.

Many recent works have been interested in highlighting the probability of the role of hyper activation of Mineralocorticoid receptors at the level of the choroid vessels in the Pathophysiology of central serous Chorioretinopathy, based on this theory, we were interested in Eplerenone, an anti aldosterone, a drug class widely used in cardiology, which inhibits the Mineralocorticoid pathway, and therefore according to this theory act directly on one of the Pathophysiological pathways.

Material and Methods

We conducted a prospective study in the ophthalmology department of the military instruction hospital Mohammed V of Rabat, including 11 cases of chronic central serous Chorioretinopathy, between March 2018 and March 2020.

The Eplerenone or INSPRA® is a Mineralocorticoid receptor antagonist used off-label for this indication; informed consent was signed by all of our patients after explaining the entire protocol, alternatives, benefits and risks of this treatment.

We analyzed the data of the consultations at inclusion, 1 month (M1), 3 months (M3) and 6 months (M6) for each patient. During

Citation: Khamaily M, Salem JB, Tarib I, Sidi D, Bajjouk S, Zerrouk R, et al. Eplerenone in the Central Serous Chorioretinopathy Chronic Experience of the Military Teaching Hospital, Rabat. Clin Ophthalmol J. 2020;1(2):1009.

Copyright: © 2020 Mehdi Khamaily

Publisher Name: Medtext Publications LLC

Manuscript compiled: June 18th, 2020

***Corresponding author:** Mehdi Khamaily, Department of Ophthalmology, Mohammed V Military Teaching Hospital, Faculty of Medicine and Pharmacy, Mohammed V University Rabat, Morocco, E-mail: mehdi.khamaily@gmail.com

each of these consultations, we listed for each patient, the tolerance to treatment, the best visual acuity corrected by far on the Monoyer scale converted to Log MAG, the foveal thickness in high definition OCT (in microns), the size of the serous retinal detachment in OCT (in microns).

The first endpoint was primarily functional, namely the improvement of the corrected visual acuity, as well as from an anatomical point of view, in particular the central macular thickness, the size of the SRF and the choroidal thickness at the OCT. not to mention tolerance to Eplerenone.

We included in our study, any central serous Chorioretinopathy that exceeds 3 months with a SFR and a significant visual impact. We first excluded the contraindications of Eplerenone, namely the pregnant woman, and any patient with a history of renal failure or serum potassium disorder.

Patients with associated macular pathology

History of previous treatments (focal laser, PDT dynamic phototherapy, injection of anti-VEGF).

On optical coherence tomography, we measured two parameters:

- On a high resolution line: the central macular thickness integrating the space between the retinal pigment epithelium and the internal limiting membrane, performed automatically by the OCT software
- On a high resolution line: the height of the retinal serous detachment, measured manually with a caliper between the pigment epithelium and the line of external articles of photoreceptors.

Results

We studied 11 eyes of 11 patients who presented with clinically

significant central serous Chorioretinopathy more than 3 months.

Our 11 patients were male, with an average age of 32.54 years +/- 6.78 (26 to 47 years). In all the patients in our series, the state of professional or personal stress was present, with the corticotherapy taken in 2 patients as well as the active smoking in 6/11 (Figure 1).

The decrease in acuity was the common symptom of all the patients with an initial mean on the Monoyer scale of 2.18/10 (LogMAR=+0.7 ± 0.21) with extremes of 1/10 (LogMAR+1) to 4/10 (LogMAR+0.4), metamorphopsia was found in 5 patients, a micropsy in 2 patients with a central scotoma in 5 patients, with an average duration of symptoms of 20 weeks (5 month) (Figure 2).

Eplerenone (INSPRA®), which is available as a 25 mg tablet, was prescribed at a dose of 25 mg/day for the first week, then 50 mg/day for a minimum duration of 1 month, with an average duration of treatment. 15 weeks (between 1 month and 4 months).

The treatment was prolonged according to the anatomical and functional evolution, the tolerance of the side effects and the results of the serum potassium which was measured on Day 0, D7, at 1 month and then every month while the patient is under treatment of a systematically, and each time the side effects worsen in the patient.

The average duration of treatment was 15 weeks (between 1 month and 4 months), Side effects to treatment were noted, including diarrhea in 6 patients, tolerable muscle cramps in 5 patients, followed by low back pain in 3 with one case of insomnia. Suppressed by symptomatic treatment (Figure 3).

In addition, immediate discontinuation of treatment was necessary in 3 patients, including 1 to 4 weeks of treatment for severe muscle cramps, and Hyperkalemia in the other 2 at 10 weeks and 11 weeks of treatment.

Risk factors	Patients
corticosteroid therapy	2/11 (19%)
State of Stress	11/11 (100%)
Castro esophageal reflux disease	0/11 (0%)
Active smoking 6/11 (55%)	6/11 (55%)
High blood pressure 0/11 (0%)	0/11 (0%)

Figure 1: Risk factors in the patients in our study.

Symptoms	Patients
Impaired visual acuity	11/11 (100%)
Metamorphopsis	5/11 (46%)
Micropsis	2/11 (19%)
Central scotoma	5/11 (46%)

Figure 2: The most encountered symptoms in our study.

Side effects	Patients	
diarrhea	6/11	(55%)
Muscle cramps	5/11	(46%)
Lower back pain	3/11	(28%)
Insomnia	1/11	(91%)
<i>Hyperkaliemia</i>	<i>2/11</i>	<i>(19%)</i>

Figure 3: The main side effects in patients in our study.

Our results concern the best visual acuity corrected in far vision on the Monoyer scale, covert in LogMAR, the central foveal thickness and the size of the SFR at macular OCT.

There was a statistically significant improvement in the M1 AVCM (0.62 ± 0.19 LogMAR; $p=0.014$), M3 (0.41 ± 0.14 LogMAR; $p=0.013$) and M6 (0.28 ± 0.14 LogMAR, $p=0.025$) (Figure 4).

Concerning the RSD, the central mean central macular thickness in a non-statistically significant manner at M1 (317 ± 82 microns; $p=0.066$) then statistically significant at M3 (292 ± 73.6 microns; $p=0.01$) and M6 (251 ± 94 microns; $p=0.038$) (Figure 5). Similarly, there was a non-statistically significant decrease in its size at M1 (109 ± 80.9 microns; $p=0.059$) and which became significant at M3 (73 ± 33.4 microns; $p=0.009$) and M6 (24 ± 18.2 microns; $p=0.006$) (Figure 6).

The total drying of the SRF was noted that from the 3rd month of treatment in 5 patients, to 6 months in 1 patient, as for 1 patient, it kept a discreet SRF.

We report a case from our series, a 36-year-old patient, who presented with a well-developed chronic CRSC on Eplerenone (Figure 7).

Discussion

We were interested in Eplerenone in our study, an anti-aldosterone that binds and inhibits the Mineralocorticoid receptors. This molecule is better tolerated than spironolactone according to Rubiano [3] it is used mainly in cardiology in heart failure and myocardial infarction. A first pilot study in 2013 by Bousquet evaluates Eplerenone in the treatment of refractory CRSCs [4]. Of the 13 patients treated, 69% had a complete resolution of the DSR at 3 months, with no major side effect reported. This study was an extension of work on the eyes of rats carried out by the same team [5].

All the patients in our series were male with an average age of 32.5 years. In the various series in the literature, a clear predominance of men was noted with an average age which varied between 40.7 [6] years and 54.2 [4] years depending on the studies.

In most studies, taking corticosteroid therapy is known as a major risk factor whatever its dosage form, sometimes even at low doses, Asensio-Sánchez VM published in January 2020 a case of bilateral central serous Chorioretinopathy, 1 month after a Intra-tarsal injection of Triamcinolone for a chalazion, the CRSC spontaneously resolved well 3 months after diagnosis [7].

Nowadays, the definition of persistent CSCR is debatable, but it is most often defined as a DSR lasting more than 3 months or recurrence

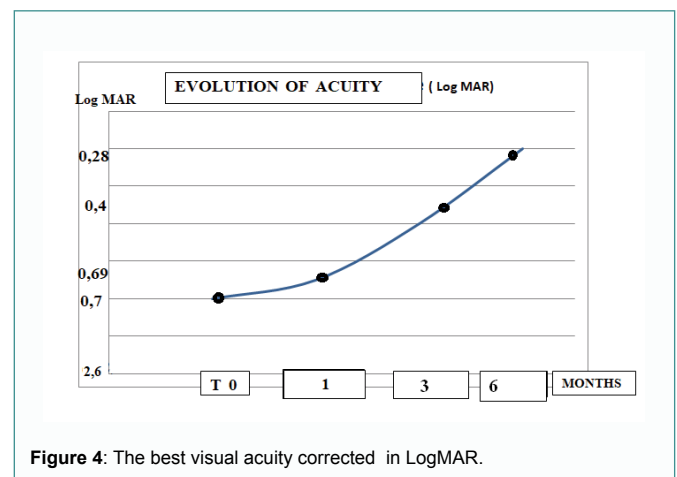


Figure 4: The best visual acuity corrected in LogMAR.

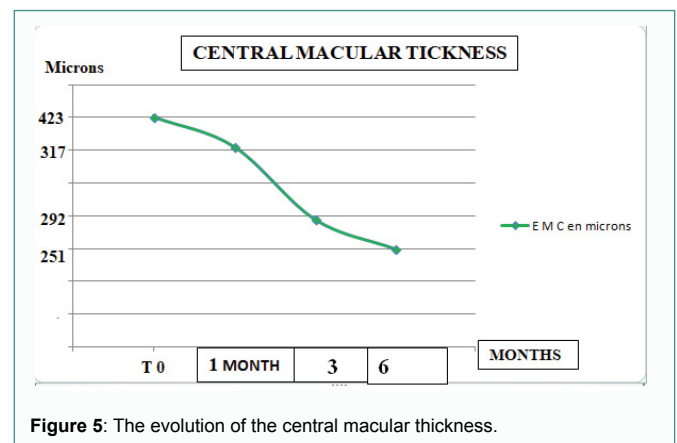


Figure 5: The evolution of the central macular thickness.

of the disease within one year [8]. The period of persistence is variable according to the authors (between 3 and 6 months), but the most cited periods are 3 and 4 months.

In the Lotery study, the overall incidence of events described with Eplerenone (53%) was similar to that observed with placebo (54%). The rate of discontinuation due to adverse events was 4.4% in patients treated with Eplerenone and 4.3% in patients treated with placebo. The common (>1/100) or serious adverse events observed in this study for which a relationship with treatment was suspected and whose incidence was greater than that observed with placebo [9].

Another prospective study in Boston conducted in 2019 also by Moein et al. [8] on 13 patients with the diagnosis of chronic CSCR. All patients received 50 mg/day Eplerenone for 4 weeks. The best

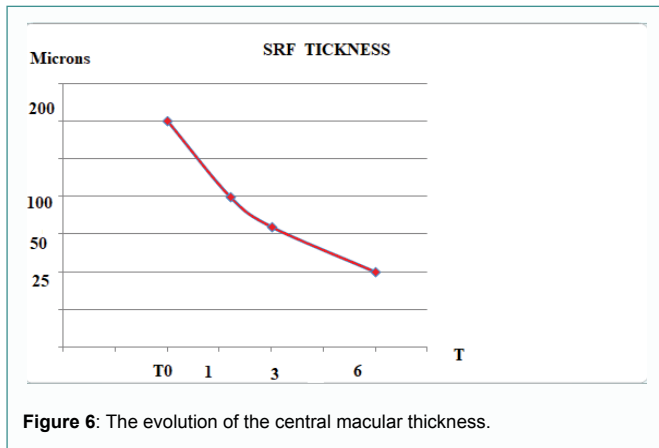


Figure 6: The evolution of the central macular thickness.

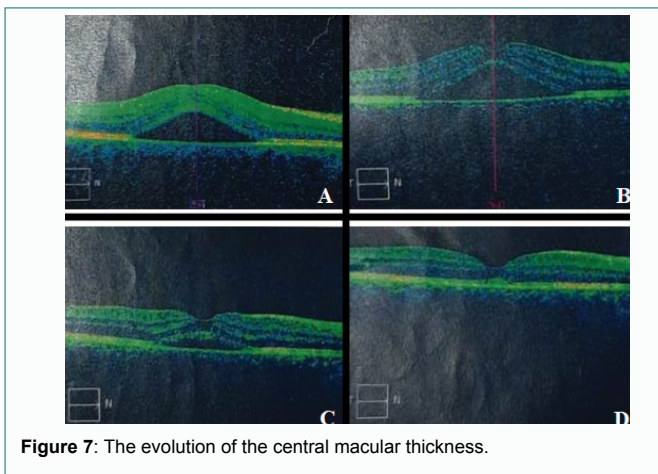


Figure 7: The evolution of the central macular thickness.

corrected visual acuity and OCT parameters, including subretinal fluid, choroidal thickness and central macular thickness, were measured manually. The mean height of the DSR decreased slightly after one month's follow-up from the initial value, but the change was not statistically significant (94.18 ± 17.53 versus 113.15 ± 18.69 ; $p=0.08$). The subfoveal choroidal thickness and the central macular thickness were significantly reduced compared to the baseline (6.6% [$p=0.002$] and 7.05% [$p=0.04$], respectively). The final corrected visual acuity did not change significantly ($20/28$ versus $20/30$ [$p=0.16$]) [8].

Conclusion

These encouraging results allow us to integrate Eplerenone into the already existing therapeutic arsenal; however, randomized double-blind studies remain necessary in order to establish a standardized therapeutic protocol specifying the dosage and the optimal duration of treatment.

References

1. Von Graefe A. Ueber zentrale recidivierende Retinitis. Graefes Arch Clin Exp Ophthalmol. 1866;12: 211-5.
2. Gass JD, Norton EW, Justice J. Serous detachment of the retinal pigment epithelium. Trans Am Acad Ophthalmol Otolaryngol. 1966;70(6):990-1015.
3. Fusi-Rubiano W, Saedon H, Patel V, Yang YC. Oral medications for central serous Chorioretinopathy: a Literature Review. Eye (Lond). 2020;34(5):809-24.
4. Bousquet E, Beydoun T, Zhao M, Hassan L, Offret O, Behar-Cohen F. Mineralocorticoid receptor antagonism in the treatment of chronic central serous chorioretinopathy: a pilot study. Retina. 2013;33(10):2096-102.
5. Daruich A, Matet A, Dirani A, Bousquet E, Zhao M, Farman N, et al. Central serous chorioretinopathy: Recent findings and new physiopathology hypothesis. Prog Retin Eye Res. 2015;48:82-118.
6. Farooq O, Habib A, Shah MA, Ahmed N. Effect of oral Eplerenone in anatomical and functional improvement in patients with chronic central serous Chorioretinopathy. Pak J Med Sci. 2019;35(6):1544-7.
7. Asensio-Sánchez VM, Pareja-Aricó L, Valentín-Bravo J. Bilateral and multifocal central serous chorioretinopathy after injecting triamcinolone into a chalazion. Arch Soc Esp Oftalmol. 2020;95(3):141-5.
8. Moein HM, Bierman LW, Novais EA, Moreira-Neto C, Baupal CR, Rogers A, et al. Short-term eplerenone for treatment of chronic central serous chorioretinopathy; a prospective study. Int J Retin Vitre. 2019;5:39.
9. Lotery A, Sivaprasad S, O'Connell A, Harris RA, Culliford L, Ellis L, et al. Eplerenone for chronic central serous Chorioretinopathy in patients with active, previously untreated disease for more than 4 months (VICI): a randomised, double-blind, placebo-controlled trial. Lancet. 2020;395(10220):294-303.