

Clinical Image

Fever of Unknown Origin: A Crohn's Disease Challenge

Laisa Socorro Briongos-Figuero* and Miriam Gabella-Martín

Internal Medicine Service, Rio Hortega University Hospital, Spain

Clinical Image

A 14-years-old woman presented to an outpatient clinic with a 7-months history of daily fever and abdominal pain. Six week before presentations, she had been evaluated at another clinic without findings in common laboratory test and abdominal ultrasonography. Physical examination only revealed dull pain in lower left abdomen, not radiated. Computed tomography and colonoscopy were normal as well as an infectious disease investigation and a complete vasculitides and autoinflammatory diseases tests. Because of fever of unknown origin presentation, radiolabelled white blood cell Single Photon Emission Computed Tomography/Computed Tomography (SPECT/CT) was performed, which revealed the presence of a 6 cm area of active inflammation at the left ileum (arrow) (Figure 1). No other lesions were identified, so a diagnosis of Crohn's disease was made. The patient was referred to Inflammatory Bowel Disease Clinic.

Fever of unknown origin in immunocompetent youngest people could become a diagnostic challenge, especially in this COVID-19 pandemic time and it is important to remember that the cause is more likely a subtle or atypical manifestation of a common disease rather than a rare disease.

Keywords: Inflammatory bowel diseases; Fever of unknown origin

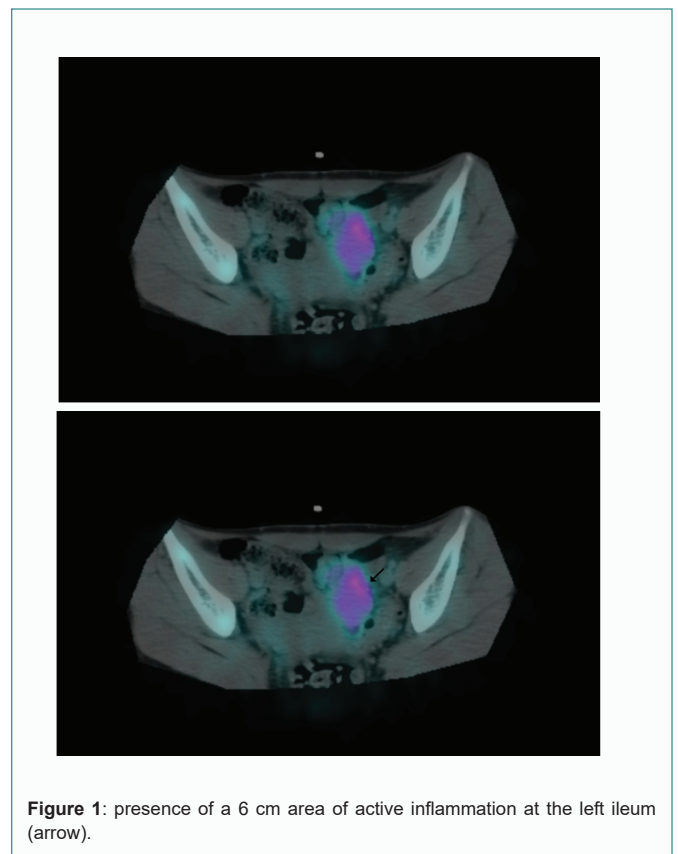


Figure 1: presence of a 6 cm area of active inflammation at the left ileum (arrow).

Citation: Briongos-Figuero LS, Gabella-Martín M. Fever of Unknown Origin: A Crohn's Disease Challenge. *Am J Hepato Gastroenterol.* 2021;1(1):1002.

Copyright: © 2021 Laisa Socorro Briongos-Figuero

Publisher Name: Medtext Publications LLC

Manuscript compiled: Jun 09th, 2021

***Corresponding author:** Laisa Socorro Briongos-Figuero, Internal Medicine Service, Rio Hortega University Hospital, C/Dulzaina 2, 47012 Valladolid, Spain, Tel: +34-983420400; E-mail: laisadoc@hotmail.com