

## Clinical Image

# Headache – Ocular or Neurological Origin???- A Diagnostic Dilemma

Tharini Senthamizh\*

Department of Ophthalmology, Jawaharlal Postgraduate Medical Education and Research, India

## Clinical Image

A 41 year old obese female presented to our ophthalmology clinic with infrequent headache for five years which did not respond to any local treatment. Her distant vision was 6/6 and near vision N12 in both eyes. Anterior segment examination revealed clear cornea, shallow anterior chamber with a depth of Vanherick grade 1 by slit lamp examination (Figure 1 and 2). Gonioscopy by Shaffer's grading showed closed angles in two quadrants with no peripheral anterior synechiae. Pupils were normal with brisk reaction. Undilated fundus examination of both eyes showed optic disc hyperemia and edema. Laser peripheral iridotomy was done in both eyes on separate sittings, a week apart. Deepening of anterior chamber was clinically confirmed by post laser gonioscopy which showed open angles. Dilated fundus examination revealed clear media, hyperemic disc, margins blurred, cup obliterated and absence of spontaneous venous pulsation. A diagnosis of papilloedema was made which was confirmed by measuring Retinal Nerve fibre Layer thickness around the disc by stratus Optical Coherence Tomography (Figure 3). An urgent neurological evaluation and radio imaging of the brain ruled out space occupying lesion and cerebral venous thrombosis. Cerebrospinal fluid examination by lumbar puncture was normal except for opening pressure of 290 mm of H<sub>2</sub>O. Hence diagnosis of idiopathic intracranial hypertension was made. Patient was started on oral acetazolamide 250 mg four times a day and the patient improved dramatically. Subacute angle closure glaucoma is predominantly seen in females. The condition has also been called intermittent, prodromal or subclinical [1]. The main presenting symptom is headache and coloured halos. Gonioscopy shows occludable angle which opens in two-thirds of patients after YAG iridotomy. Fundus examination reveals a normal disc or might show features of glaucomatous cupping. But the presence of disc edema in subacute angle closure has not been reported till now. Hyperemic and swollen optic disc may occur during acute attack of angle closure glaucoma which is presumably from impaired axoplasmic flow or hypotony following the attack [2]. This patient has given us a surprise of disc edema with no features of acute angle closure attack, posing a diagnostic challenge between subacute angle closure with disc edema and papilloedema. Fundus

**Citation:** Tharini Senthamizh. Headache – Ocular or Neurological Origin???- A Diagnostic Dilemma. Ann Short Rep Clin Image. 2020; 2(1): 1014.

**Copyright:** © 2020 Tharini Senthamizh

**Publisher Name:** Medtext Publications LLC

**Manuscript compiled:** Dec 31<sup>st</sup>, 2020

**\*Corresponding author:** Tharini Senthamizh, Department of Ophthalmology, Jawaharlal Postgraduate Medical Education and Research, Puducherry, India, E-mail: drtharini88@gmail.com




Figure 1: Slit lamp image of right eye showing very shallow anterior chamber

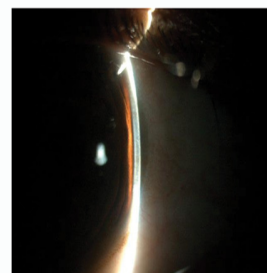


Figure 2: Slit lamp image of left eye showing very shallow anterior chamber with Van Herick grade 1.

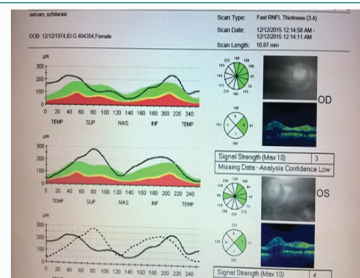


Figure 3: RNFL thickness by stratus OCT above normal range confirming disc edema.

examination for assessment of cupping of the disc is a must in such cases, either undilated or dilated after prophylactic laser if gonioscopy reveals an occludable angle. A combined approach by neurologists and ophthalmologists can be helpful in alleviating the symptoms in patients presenting with headache and sometimes be life saving too.

## References

1. R Ramakrishnan, Saurabh Mittal, SonalAmbatkar, Mohideen A Kader. Retinal nerve fibre layer thickness measurements in normal Indian population by optical coherence tomography. Indian J Ophthalmol. 2006;54(1);11-5.
2. Becker- Shaffer's Diagnosis And Therapy Of The Glaucomas - 8 Th Edition. Mosby Elsevier: 2010;189- 98.