

## Case Report

# Hyperprolactinemia Leading to Mammary Duct Ectasia in a Pre-Menopausal Female

Noreen Samad<sup>\*</sup> and Kinza Hafeez

Department of Biochemistry, Bahauddin Zakariya University, Pakistan

## Abstract

Mammary duct ectasia is described by persistent inflammation and changes of fibrosis which directs to blockage of debris within the mammary duct. Its characteristics imitates to that of invasive carcinoma. It mostly occurs in females at menopause or after menopause, but rare in children and men. Here we present a case report 37 years old lady having hyperprolactinemia, who came with complain of stiffness of breast and nipple discharge of milk since 12 to 13 years. Bilateral mammography showed increased density under the left nipple without calcification and/or dominant mass. Ultrasound of breast evidenced few abnormally dilated ducts in the retroareolar region of left than right nipple. Therefore, the patient was diagnosed with duct ectasia. It is concluded that hyperprolactinemia can also lead to mammary duct ectasia even in women even at a pre menopausal age.

**Keywords:** Mammary duct actesia; Hyperprolactinemia; Nipple discharge

## Introduction

Mammary duct ectasia is an inflammatory disorder in breast [1]. The pathology behind this includes expansion of the main ducts related with intraluminal blocks of histocytes and periductal inflammation [2]. The rate of occurrence of mammary duct ectasia can varies from 1.1% to 75%, according to the investigative methods utilized which can be clinical, histopathological or based on necropsy [3]. Mammary duct ectasia mainly influences those females who are undertaking menopause or about to start menopause but canal so take place in younger females, males and infants [1].

Smoking is a dangerous feature for duct ectasia. It was discovered that smokers were three times more likely to develop the state of duct ectasia than non-smokers [4]. This ailment is main cause among other common reasons of bloody nipple discharge and sub-areolar masses, radiologically and medically imitating persistent carcinoma, while Nipple discharge in turn is the third major frequent sign nearing to breast health centers, chasing lumps and pain [5-7].

Here, we present a case report of a female who developed duct actesia before menopausal age with hyperprolactinemia.

## Case Presentation

A 37 year old woman known case of hypertension came at Doctors Hospital and Medical Centre Lahore Punjab, Pakistan with a history of hypertension and stiffness of breast along with discharge of milk since last 12 to 13 years. On compression of her breast, nipple discharge of milk more on the left side was also observed. The nipple

discharge was often drenching through shirts within a few minutes of throwing on them. The menarche of the patient took place at a normal age, but with irregular menstrual periods. The patient married at the age of 21-year. The patient had two children. Among those children, the elder child had breast feed properly, but the younger child had not been breast fed properly. The younger child breast feeding was stopped due to increased prolactin level and bloody nipple discharge. The patient had never been smoked and did not have a family history of cancer.

On examination endocrinology report for prolactin levels was first done. Report showed prolactin level was 79.5 ng/ml (reference range: 5.18 ng/ml to 26.53 ng/ml for female). Mammography was performed and evidenced of increased density under the left nipple. However, no dominant mass or suspicious calcification was seen. There was no architectural distortion of the parenchyma, while, lymph nodes were noted in both axilla (Figure 1). Ultrasound of breast exhibited few dilated ducts in the retroareolar region of both breasts, however abnormally dilated under the left nipple, largest measuring about 8 mm (Figure 2). On the basis of clinical signs and symptoms and clinical tests findings, patient was diagnosed to have duct actesia.

## Discussion

Mammary duct ectasia is a seditious (causing inflammation) syndrome in breast which is linked with inflammation and periductal fibrosis of differing extent [8]. This illness is also recognized as comedomastitis, plasma cell mastitis and cholesterol granuloma. Duct dilatation is generally not indicative in the early stages [9]. When it is indicative, mainly general medical appearance is mammary discharge [10]. In the most of incidences, no clear abnormalities are present, but in afterward phases, tender sub-areolar masses along with skin renunciation happen, which can be detected as infiltrative carcinoma, which is wrong. The identification of Mammary Duct Ectasia is generally medical. The irregular thickening of the sub-areolar breast tissue and micro-calcifications is mostly identified via mammography. These thickenings can be imitated as carcinoma [11]. The diameter of ducts greater than 5 mm can be identified and assessed with the help of ultrasonography [12]. Ductography is frequently performed for recognizing ductal dilatation with multifocal luminal barrier in a dropped way, but it is bound as an investigative way for Mammary


**Citation:** Samad N, Hafeez K. Hyperprolactinemia Leading to Mammary Duct Ectasia in a Pre-Menopausal Female. *Clin J Pharmacol Pharmacother.* 2019; 1(2): 1007.

**Copyright:** © 2019 Noreen Samad

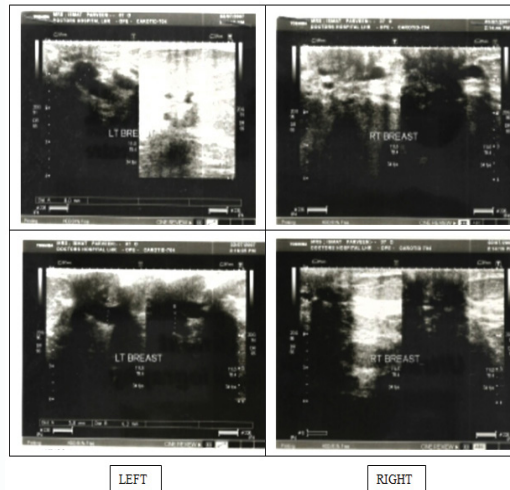
**Publisher Name:** Medtext Publications LLC

**Manuscript compiled:** June 20<sup>th</sup>, 2019

**\*Corresponding author:** Noreen Samad, Department of Biochemistry, Bahauddin Zakariya University, 60800, Multan, Pakistan, E-mail: noreen.samad@bzu.edu.pk; noreensamad80@gmail.com



**Figure 1:** (A) Mammography of right breast (B) Mammogram of left breast illustrating increased density under the left nipple without suspicious calcification and architectural distortion of the parenchyma.



**Figure 2:** Ultrasound showing dilated ducts in the retroareolar region of both breasts, however abnormally dilated under the left nipple, largest measuring about 8 mm.

Duct Ectasia [13]. Histopathologically, the periductal inflammation is analyzed. The lymphocytes, plasma cells or foamy histiocytes are present more often. The early stage of Mammary Duct Ectasia is illustrated through the existence of expansion of terminals of duct [14].

Afterwards the inflammation is substituted with fibrosis. Duct ectasia rarely gets better devoid of cure or by means of utilization of temperate antibiotics and compresses. If the warnings of ectasia do not go biopsy is frequently needed and the anomalous duct would be eliminated *via* surgery [9]. Constant or repeated disorders are handled with centered surgical removal of the abnormal ducts below the nipple [15,16]. A good way of surgery for duct ectasia is image guided surgery by ductal endoscopy [17]. There are two theories with respect to the pathology of Mammary Duct Ectasia [18].

First, the main pathological route is believed to be unclear with degeneration of the ducts and glands, pursued via ducts expansion, directing to the apathy of secretion, duct burst and inflammation. The second contributing incident is offered to exist as an inflammatory progression; periductal inflammation being the primary anomaly, pursued by duct sclerosis, obliteration and duct ectasia. Alternatively, the etiology of duct ectasia is still unidentified. Other influencing

factors consist of squamous metaplasia of the terminal duct epithelium, phenothiazine treatment, cigarette smoking, bacterial growth and hyperprolactinemia. Tobacco smoking is also a hazardous cause for ductal ectasia. While another study revealed that bacterial infection also leads to duct ectasia [19-21]. But these evidences are not enough as a cause of this disorder. An earlier study illustrated a relationship involving odd prolactin discharge and Mammary Duct Ectasia [22]. Shousha et al., [23] also analyzed that there is a linkage between certain hypothalamic/pituitary ailments, likely correlated with prolactin secretion and progress of mammary duct ectasia in postmenopausal patients. It is suggested that, hyperprolactinemia may also leads to mammary duct ectasia. However, further studies are needed to elucidate the process, so that such kind of disorders can be prevented.

### Conclusion

It is concluded that, there is a strong relationship between hyperprolactinemia and mammary duct ectasia in a pre menopausal age also. Increased prolactin level induces the various stages of mammary duct ectasia. Hyperprolactinemia increases the inflammation in mammary ducts. As a result different signs and symptoms of mammary duct ectasia develop.

## References

1. McHoney M, Munro F, Mackinlay G. Mammary duct ectasia in children: report of a short series and review of the literature. *Early Human Development*. 2011;87:527-30.
2. Haagensen CD. Mammary-Duct Ectasia; A Disease That May Simulate Carcinoma. *Cancer*. 1951;4(4):749-61.
3. Thomas WG, Williamson RC, Davies JD, Webb AJ. The clinical syndrome of mammary duct ectasia. *Br J Surg*. 1982;69(7):423-5.
4. Rahal RM, de Freitas-Júnior R, Paulinelli RR. Risk factors for duct ectasia. *Breast J*. 2005;11(4):262-5.
5. Dogan BE, Ceyhan K, Tukul S, Saylisoy S, Whitman GJ. Ductal dilatation as the manifesting sign of invasive ductal carcinoma. *J Ultrasound Med*. 2005;24:1413-7.
6. Duchesne N, Skolnik S, Bilmer S. Ultrasound appearance of chronic mammary duct ectasia. *Can Assoc Radiol J*. 2005;56(5):297-300.
7. Beechey-Newman N, Kulkarni D, Kothari A, D'Arrigo C, Culora G, Hamed H, et al. Breast duct microendoscopy in nipple discharge: micro brush improves cytology. *Surg Endosc*. 2005;19:1648-51.
8. Leung AK, Kao CP. Mammary duct ectasia: a cause of bloody nipple discharge. *J Natl Med Assoc*. 2004;96(4):543-5.
9. Browning J, Bigrigg A, Taylor I. Symptomatic and incidental mammary duct ectasia. *J R Soc Med*. 1986;79(12):715-6.
10. Rahal RM, Júnior RF, Reis C, Pimenta FC, Netto JC, Paulinelli RR. Prevalence of bacteria in the nipple discharge of patients with duct ectasia. *Int J Clin Pract*. 2005;59(9):1045-50.
11. Sweeney DJ, Wylie EJ. Mammographic appearances of mammary duct ectasia that mimic carcinoma in a screening programme. *Australas Radiol*. 1995;39:18-23.
12. Rizzato G, Chersevani R. Breast ultrasound and new technologies. *Eur J Radiol*. 1998;27:S242-9.
13. Sakorafas GH. Nipple discharge: current diagnostic and therapeutic approaches. *Cancer Treat Rev*. 2001;27:275-82.
14. Ying T, Li Q, Xu L, Liu F, Hu B. Three-dimensional ultrasound appearance of pelvic floor in nulliparous women and pelvic organ prolapse women. *Int J Med Sci*. 2012;9:894-900.
15. Zervoudis S, Iatrakis G, Economides P, Polyzos D, Navrozoglou I. Nipple discharge screening. *Womens Health (Lond)*. 2010;6:135-51.
16. Jung Y, Chung JH. Mammary duct ectasia with bloody nipple discharge in a child. *Ann Surg Treat Res*. 2014;86(3):165-7.
17. Lanitis S, Filippakis G, Thomas J, Christofides T, Al Mufti R, Hadjiminis DJ. Microdochectomy for single-duct pathologic nipple discharge and normal or benign imaging and cytology. *Breast*. 2008;17(3):309-13.
18. Wang Z, Leonard MH, Khamapirad T, Castro CY. Bilateral extensive ductitis obliterans manifested by bloody nipple discharge in a patient with long-term diabetes mellitus. *Breast J*. 2007;13:599-602.
19. Rahal RM, de Freitas-Júnior R, Paulinelli RR. Risk factors for duct ectasia. *Breast J*. 2005;11(4):262-5.
20. Dixon JM, Ravisekar O, Chetty U, Anderson TJ. Periductal mastitis and duct ectasia: different conditions with different aetiologies. *Br J Surg*. 1996;83(6):820-2.
21. Kitahara S, Wakabayashi M, Shiba T, Nonaka K, Nonaka H, Kobayashi I. Mammary duct ectasia in children presenting bloody nipple discharge: a case in a pubertal girl. *J Pediatr Endocrin Met*. 1996;9:419-21.
22. Peters F, Schuth W. Hyperprolactinemia and nonpuerperal mastitis (duct ectasia). *JAMA*. 1989;261(11):1618-20.
23. Shousha S, Backhouse CM, Dawson PM, Alaghand-Zadeh J, Burn I. Mammary duct ectasia and pituitary adenomas. *Am J Surg Pathol*. 1988;12(2):130-3.