

Case Report

Lateral Periodontal Cyst in a Pediatric Patient - Report of a Rare Case

Nagaveni NB*

Garike Dental Care, Davangere, Karnataka, India

Abstract

Lateral Periodontal cyst is a rarely occurring non-inflammatory odontogenic cyst most commonly encountered in adults. Most of the time, it is found asymptomatic, and usually found on routine radiographic examination of the teeth. The aim of this article is to present development of a lateral periodontal cyst in a pediatric patient. The article also briefly reviews the literature concerning the cyst.

Keywords: Odontogenic cyst; Non-inflammatory; Lateral periodontal cyst; Pediatric patient; Enucleation

Introduction

Lateral Periodontal Cyst (LPC) is a relatively uncommon but well recognized type of developmental odontogenic cyst that accounts for 0.8% to 2.3% of all odontogenic cysts [1]. It is a non-inflammatory and intra-osseous type of cyst usually found on the lateral surface of the root of a vital tooth. Radiographically it appears as an oval, tear drop shape with well-defined sclerotic border. It was first described by Nordquist in 1947 and is commonly found in adults aged 30 to 50 years. However, it can also occur in children, but the frequency is very less. Therefore, with the intention of presenting report on rare occurrence of asymptomatic lateral periodontal cyst in an Indian patient the present article is published. The paper also provides information about LPC including its incidence, diagnosis, treatment, and prognosis.

Case Presentation

A 15-year-old female patient who is already taking orthodontic treatment subjected to orthopantomograph radiograph for planning of extraction of premolars and third molars. Patient did not have any signs and symptoms of dental pain or any other intro oral findings. On radiographic examination a well-defined unilocular, oval shaped radiolucent cystic lesion surrounded by well-defined radiopaque (sclerotic) border was observed in between roots of mandibular left first and second premolars. The radiopaque lining of the cyst appeared to originate from the periodontal ligament of the two teeth. Based on the literature search the pathology was diagnosed as a case of Lateral Periodontal Cyst. Patient was informed about the condition and as the cyst was small in size a treatment plan of enucleation of the cyst under local anaesthesia was planned.

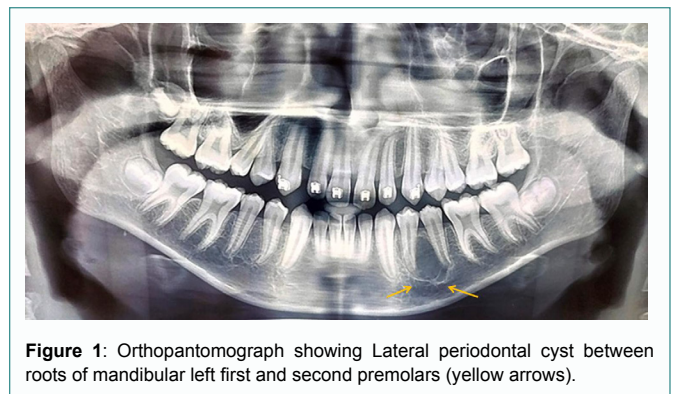


Figure 1: Orthopantomograph showing Lateral periodontal cyst between roots of mandibular left first and second premolars (yellow arrows).

Discussion

Incidence

The incidence of LPC in children is relatively low compared to adults. According to a study by Anand et al. [2] in 2020, LPC accounted for only 1.9% of all odontogenic cysts in children. Another study by El-Naggar et al. [3] (2013) found that LPC accounted for only 1.2% of all odontogenic cysts in a pediatric population. However, these studies have shown that LPC can occur in children as young as 5 years old, with a peak incidence between the ages of 11 to 20 years old.

Clinical features

LPC has shown predilection of occurrence in males compared to females and age ranges from 22 to 85 in adults and in children it varies from 11 to 20 years [4]. LPC is usually found adjacent to the roots of vital mandibular teeth, especially premolars and canines, and is often asymptomatic [5]. The cyst may cause root resorption or displacement of teeth, leading to clinical symptoms such as pain or swelling [6]. Thirty three percent also accounts for maxillary lateral incisor areas. Most of the time it remains to be asymptomatic and usually discovered during routine radiographic examination. When cyst becomes infected it may resemble a lateral periodontal abscess and in such cases drainage of cystic content is essential [4].

Etiology

The etiology of LPC is not yet fully understood, but it is believed to arise from the epithelial remnants of the dental lamina, which

Citation: Nagaveni NB. Lateral Periodontal Cyst in a Pediatric Patient - Report of a Rare Case. J Pediatr Dent Hyg. 2023;2(1):1008.

Copyright: © 2023 Nagaveni NB

Publisher Name: Medtext Publications LLC

Manuscript compiled: May 25th, 2023

***Corresponding author:** Nagaveni NB, Garike Dental Care, Davangere, Karnataka, India, E-mail: nagavenianurag@gmail.com

may be stimulated to proliferate by various stimuli such as trauma, inflammation, or infection [7]. Various theories concerning etiology and pathogenesis of lesion have been reviewed by Standish and Shafer. These cysts appear to arise in association with lateral root surface of an erupted tooth. They are believed to originate from proliferation of rests of Malassez, as a primordial cyst of supernumerary tooth germ or originated from rests of dental lamina [4]. In addition, some genetic factors have been implicated in the development of LPC [8].

Diagnosis

The diagnosis of LPC is based on clinical and radiographic findings, and histopathological examination is necessary to confirm the diagnosis. The diagnosis of LPC can be challenging due to its asymptomatic nature and radiographic similarity to other cystic lesions. Therefore, a biopsy is necessary for the definitive diagnosis of LPC [4]. Radiographically, the cyst usually appears as a well-defined radiolucency, in apposition to lateral surface of a tooth root. Border is definitive and may be surrounded by thin layer of sclerotic bone [4]. And histologically, it is lined by a non-keratinized epithelium with a corrugated or hobnail appearance [3] with one to five cell layers lining. Many of the lining cells have a clear, vacuolated, glycogen-rich cytoplasm. The connective tissue exhibits zone of hyalinization, consisting of a thick fibrous non-inflamed cyst wall. Differential diagnosis can be made with Botryoid Odontogenic cyst as both show distinct histologic features. This name reflects similarity to that of cluster of grapes [4].

Treatment

The treatment of LPC typically involves enucleation or marsupialization of the cystic lesion, followed by the removal of any associated tooth or root fragment [9]. The choice of treatment depends on the size of the lesion, location, and patient's age. Conservative management may be considered for small LPCs, while more aggressive treatment may be required for larger cysts. Surgical treatment of LPC has shown to have a high success rate with a low recurrence rate [10]. Additionally, long-term follow-up is necessary to monitor for any potential recurrence or development of new cystic lesions [11].

Conclusion

In conclusion, LPC is a rare odontogenic cyst that typically occurs adjacent to the roots of vital mandibular teeth, especially premolars and canines. The etiology of LPC is not fully understood, but it is believed to arise from epithelial remnants of the dental lamina. Diagnosis is based on clinical and radiographic findings, and histopathological examination is necessary to confirm the diagnosis. Surgical excision is the treatment of choice, and recurrence is rare.

References

1. Neville BW, Damm DD, Allen CM, Chi AC. Oral and maxillofacial pathology. 4th ed. St. Louis, Elsevier; 2016. p. 694.
2. Anand R, Gupta N, Gupta R. Odontogenic cysts in pediatric patients: a clinicopathological study. *J Indian Soc Pedod Prev Dent.* 2020;38(3):279-83.
3. El-Naggar AK, Al-Sebaei MO, Al-Samadani KH. Lateral periodontal cyst in a Saudi Arabian pediatric population: a retrospective study. *Saudi Dent J.* 2013;25(2):51-4.
4. Shafer WG, Hine MK, Levy BM. Shafer's textbook of oral pathology. 7th ed. Amsterdam: Elsevier; 2018. p. 334.
5. Shahoon H, Ferreira J, Souza LN, Soares AB, de Oliveira PT, de Melo WM. Lateral periodontal cyst in a 12-year-old boy: a case report. *J Can Dent Assoc.* 2011;77:b75.
6. Bodner L, Bar-Ziv J. Radiographic features of lateral periodontal cysts. *Oral Surg Oral Med Oral Pathol.* 1987;63(6):688-92.
7. El-Naggar AK, Chan JK, Grandis JR, Takata T, Slootweg PJ. WHO classification of head and neck tumours. 4th ed. Lyon: International Agency for Research on Cancer; 2017. p. 218-9.
8. Kantaputra PN, Gorlin RJ. Lateral periodontal cyst: a reappraisal. *J Oral Pathol Med.* 2001;30(8):481-7.
9. Yu SF, You M, Zheng M, Gao Y, Zhu JH, Zhao YF. Clinical features and long-term outcomes of the lateral periodontal cyst: a systematic review. *J Oral Pathol Med.* 2018;47(7):626-31.
10. Gupta B, Anand V, Garg R, Gupta S. Lateral periodontal cyst: a case report. *J Clin Diagn Res.* 2013;7(11):2672.
11. Bhowate R, Khiste S, Puranik R, Pawar R. Lateral periodontal cyst: report of two cases. *J Int Oral Health.* 2014;6(2):103.