

Case Report

Limited Gastric Pull-up in Pure Esophageal Atresia - A Case Report

Saad Al Hamidi, Khaled Alfifi, Abdullah Ahmad Twair*, Muhammad Azhar, Ali Abdullah Alzunaydi, Essa Ahmad Khudhayr and Abdulaziz Khalid Aldosari

Department of Pediatric Surgery, King Saud Medical City, Saudi Arabia

Abstract

A two-day-old male infant was diagnosed with pure esophageal atresia after birth. The patient underwent an initial gastrostomy followed by a partial gastric pull-up at the age of 3 months. An esophageal stricture developed postoperatively, which was managed with endoscopic dilation. This is an unconventional technique for this type of esophageal atresia, involving a limited gastric pull-up that resulted in a positive outcome. Here, we highlight this surgical technique and the issues that arose during the postoperative period.

Keywords: Pure esophageal atresia; Partial Gastric Pull-up (PGP); Long Gap Esophageal Atresia (LGEA)

Introduction

A two-day-old male infant was diagnosed with pure esophageal atresia after birth. The patient underwent an initial gastrostomy followed by a partial gastric pull-up at the age of 3 months. An esophageal stricture developed postoperatively, which was managed with endoscopic dilation. This is an unconventional technique for this type of esophageal atresia, involving a limited gastric pull-up that resulted in a positive outcome. Here, we highlight this surgical technique and the issues that arose during the postoperative period.

Case Presentation

This is a case of a male baby born at 32 weeks of gestation with a weight of 1.18 kg. On the initial clinical assessment, the patient was non-syndromic and hemodynamically stable. Examination of the abdomen showed a scaphoid and soft abdomen on palpation; the systematic assessment was unremarkable. The patient had normal male genitalia and a patent anus. At birth, excessive oral frothing was noted; therefore, an 8FR orogastric tube was inserted, and resistance was encountered at 7 cm from the incisors, indicating the presence of esophageal atresia.

The patient underwent a routine workup for esophageal atresia according to the established protocol. X-rays of the chest and abdomen showed a gasless abdomen and a gas-filled upper esophageal pouch with an orogastric tube terminating at the third thoracic vertebrae (T3) (Figure 1). Therefore, a diagnosis of pure esophageal atresia was established. The echocardiogram showed a left-sided aortic arch, a small Atrial Septal Defect (ASD), and mild pulmonary hypertension.

On the 5th day of life, gastrostomy tube insertion was performed,

and enteral feeding was started along with continued intensive care. At one and a half months of age, a gapogram was performed to assess the gap between the upper esophageal pouch and the highest point of the stomach. The gap was estimated to be 7 cm. Due to the wide gap; the definitive surgical procedure was further delayed. The patient remained intubated and continued to receive care in the intensive care unit.

At 3 months of age, the patient was prepared for surgery. Intra-operatively, once again, a gap assessment was performed, showing the upper esophageal pouch terminating at the lower border of the 4th thoracic vertebrae (T4). Additionally, when a metabolic bougie was introduced into the stomach *via* gastrostomy, about a 1.5 cm segment of the lower esophageal segment was seen protruding into the chest. Based on this assessment, the decision to perform a thoracotomy was made to approach the upper and lower pouches to achieve end-to-end anastomosis. Intra-operatively, the upper pouch was mobilized. The mobilization of the lower pouch was attempted *via* the trans-hiatal route. However, it was difficult to bring the two ends together to achieve anastomosis due to the fixation of the stomach to the abdominal wall by the pre-existing gastrostomy. Consequently, the decision was made to perform a laparotomy to dismantle the gastrostomy. By dividing the short gastric vessels, the stomach was partially mobilized and then brought into the chest *via* the trans-hiatal route, and end-to-end anastomosis was performed between the two ends. No pyloroplasty was performed.

The patient remained intubated in the intensive care unit. Due to the patient's unstable condition, the contrast assessment was postponed until the 19th postoperative day. When eventually conducted, the results indicated no evidence of a leak, but there was delayed gastric emptying, with partial retention of contrast in the pulled-up part of the stomach for up to 12 hours (Figure 2).

The patient was subsequently extubated, and feeding was initiated; however, it was later discontinued due to recurrent episodes of vomiting. The patient was started on Omeprazole and Domperidone, based on the recommendation of a gastroenterologist. An endoscopic assessment was performed by a gastroenterologist, which identified a stricture measuring 2 cm in length, 5 mm in diameter, and about 10 cm distal to the incisors. The stricture was dilated using a 7 cm Savary

Citation: Hamidi S, Alfifi K, Twair AA, Azhar M, Alzunaydi AA, Khudhayr EA, et al. Limited Gastric Pull-up in Pure Esophageal Atresia - A Case Report. *Int J Pediatr Surg.* 2024;5(1):1039.

Copyright: © 2024 Saad Al Hamidi

Publisher Name: Medtext Publications LLC

Manuscript compiled: Feb 28th, 2024

***Corresponding author:** Abdullah Ahmad Twair, Department of Pediatric Surgery, King Saud Medical City, Riyadh, Saudi Arabia

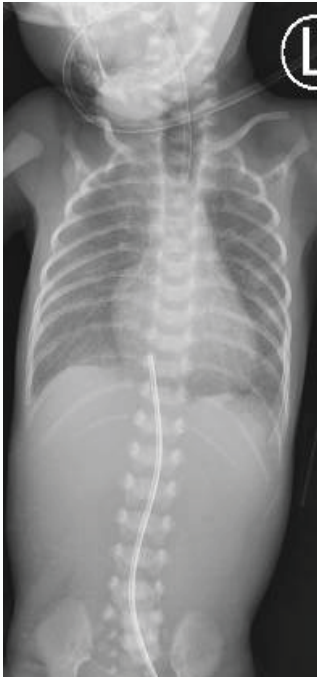

Figure 1: Showing a gas-filled and dilated upper esophageal pouch with a tube terminating at the T3 level and a gasless abdomen. The umbilical venous catheter is also visible.

Gilliard dilator. Following endoscopic dilation, the patient's condition improved, began to tolerate oral feeding, and was subsequently discharged. Three additional endoscopic dilation sessions were performed on the patient, with the last dilation caliber measuring up to 9 cm.

Currently, the patient is thriving well. He is mainly on a liquid and semi-solid diet which he is tolerating well. The last documented weight was 8 kilograms.

Discussion

Pure esophageal atresia is considered a variety of long gaps of esophageal atresia and accounts for 7% to 8% of all EA [1]. Preserving the native esophagus and achieving end-to-end anastomosis are the main objectives of surgery in the case of EA [2]. However, due to the long gap between the upper and lower esophageal pouches, this is not always feasible in cases of pure esophageal atresia [3]. Thus, the recommended course of treatment is initial feeding gastrostomy

followed by delayed primary anastomosis [4]. The gastrostomy lowers the need for TPN and TPN-related complications by permitting the start of enteral feeding and also provides an appropriate period for the baby to gain weight before a major surgical procedure. According to studies, if an adequate amount of time is given, both the upper and lower esophageal pouches tend to grow [5]. Swallowing reflux, accumulation of saliva, and the stretching caused by the upper pouch tube stimulate the growth of the upper pouch. Similarly, it has been shown that the reflux of milk-fed through the gastrostomy into the lower pouch also lengthens the lower esophageal pouch and facilitates end-to-end anastomosis [6]. Studies show that 12 weeks is the appropriate duration after which an attempt at primary anastomosis between the two esophageal ends can be made [7]. Although a variety of other surgical options exist to bridge this long gap, including intra and extra-thoracic lengthening techniques as well as the use of small and large bowel conduit, gastric pull-up has remained a popular choice in the surgical management of long-gap esophageal atresia [8].

The standard approach for definitive surgical management of pure esophageal atresia is total gastric pull-up. This procedure entails the mobilization of the stomach through a laparotomy and its passage through a trans-hiatal route into the neck [8]. This approach includes resecting the lower esophageal segment, which is typically small and underdeveloped, followed by end-to-end anastomosis between the upper esophageal pouch and the fundus of the stomach. This technique offers the benefit of eliminating the need for a thoracotomy. Additionally, the anastomosis is performed in the neck. Therefore, any anastomotic leaks that may arise are typically easily managed and well-controlled. Pyloroplasty is routinely added to prevent delayed gastric emptying [9]. In our case, we adopted an alternative approach after discovering intraoperatively that the upper esophageal pouch had elongated, and a substantial portion of the lower esophageal pouch was also identified extending into the chest. Hence, we opted for a thoracotomy approach to identify the upper and lower esophageal pouches and facilitate the primary anastomosis between the two ends. The presence of the gastrostomy was limiting the mobilization of the stomach. Therefore, a laparotomy was performed, focusing on the limited mobilization of the stomach by dividing only the short gastric vessels. Subsequently, the stomach was partially brought into the chest for tension-free anastomosis. Various studies have indicated that there is a significant incidence of anastomotic stenosis and gastroesophageal reflux in patients undergoing total gastric pull-ups [10]. Nevertheless, with partial gastric pull, while there is a lack of comprehensive data, there have been reports suggesting a comparatively increased

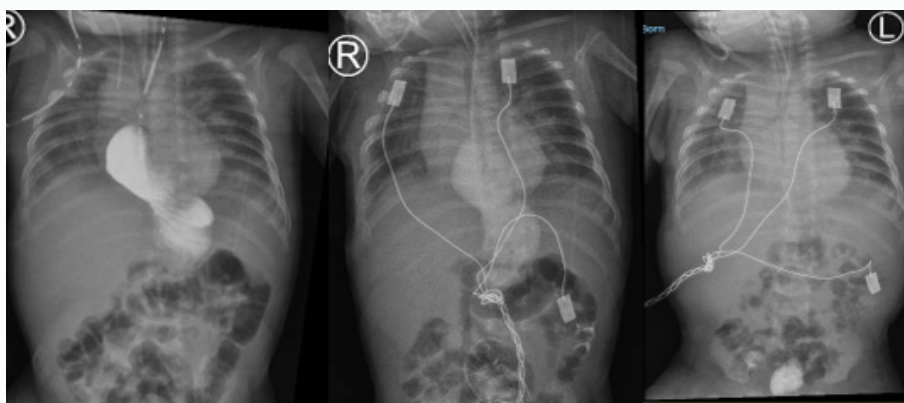


Figure 2: Showing an upper GI contrast study; the left image was taken immediately, the middle one after 12 hours, and the right image at 24 hours. Delayed gastric emptying can be seen.

occurrence of anastomotic leak, gastroesophageal reflux, and the formation of strictures. In the case of the total gastric pull-up, the reported incidence of anastomotic leak is 25% to 30%, whereas anastomotic stricture counts for 40% to 50%, and gastroesophageal reflux about 35% to 50% [11,12].

In the case of the total gastric pull-up, the reported incidence of anastomotic leak is 25% to 30%, whereas anastomotic stricture counts for 40% to 50%, and gastroesophageal reflux is about 35% to 50% [11,12]. In comparison to this, a case series reported an incidence of anastomotic leak of 33%, stricture formation of 66%, and gastroesophageal reflux of 44% in the case of PGP [13]. Alternative surgical techniques for the treatment of LGEA also have high complication rates in the form of graft loss and leak due to multiple anastomoses and long suture lines. Certain authors contend that these figures may be exaggerated because, in cases of PGP, the preservation of the gastroesophageal junction often leads to misclassification as stenosis in both contrast and endoscopic evaluations [14]. A drainage procedure, such as pyloroplasty, has been associated with the potential development of dumping syndrome and, in some instances, an increased likelihood of reflux of alkaline fluid from the duodenum into the stomach [15-17]. As a result, we refrained from performing pyloroplasty in our case. We encountered postoperative delayed gastric emptying, but it was successfully resolved through endoscopic dilation. Furthermore, we identified and preserved the vagus nerve during the surgery, a factor that reinforced our decision to abstain from pyloroplasty. The use of prokinetic agents (Domperidone) and proton pump inhibitor (Omeprazole) also helped in alleviating the symptoms of delayed gastric emptying.

Conclusion

- Trans-thoracotomy approach preserves the native esophagus and vagus nerve.
- No drainage procedure is required.
- Gastroesophageal Reflux Disease (GERD) may still pose a long-term complication, but there is an absence of bile reflux that may lead to gastritis and esophagitis.
- Absence of dumping syndrome.

References

1. Tepeneu NF, Krafka K, Bogovic M, Weber-Eibel J, Hausegger KA, Pranzl TC, et al. Successful staged management of long gap esophageal atresia. *J Pediatr Surg Case Rep.* 2022;85:102419.
2. Nouri A, Ksia A, Bouzaffara B, Munsterer O, Hidouri S, Chahed J, Sahnoun L, Mekki M. A New Operative Approach for Long-Gap Esophageal Atresia. *J Indian Assoc Pediatr Surg.* 2019;24(2):132-4.
3. Afridi FG, Shorter N, Vaughan R, Neptune S, Singh S. Primary repair of long gap esophageal atresia in a neonate employing circular myotomy on the upper pouch and a novel hemircircular myotomy on the distal pouch. *J Pediatr Surg Case Rep.* 2019;44:101188.
4. Baird R, Lal DR, Ricca RL, Diefenbach KA, Downard CD, Shelton J, et al. Management of long gap esophageal atresia: a systematic review and evidence-based guidelines from the APSA Outcomes and Evidence Based Practice Committee. *J Pediatr Surg.* 2019;54(4):675-87.
5. Oliver DH, Martin S, Belkis DM, Lucas WM, Steffan L. Favorable Outcome of Electively Delayed Elongation Procedure in Long-Gap Esophageal Atresia. *Front Surg.* 2011;8:701609.
6. Friedmacher F, Puri P. Delayed primary anastomosis for management of long-gap esophageal atresia: a meta-analysis of complications and long-term outcome. *Pediatr Surg Int.* 2012;28(9):899-906.
7. van Serooskerken ES, Lindeboom MYA, Verweij JW, van der Zee DC, Tytgat SH. Childhood outcome after correction of long-gap esophageal atresia by thoracoscopic external traction technique. *J Pediatr Surg.* 2021;56(10):1745-51.
8. Dingemann C, Eaton S, Aksnes G, Bagolan P, Cross KM, De Coppi P, et al. ERNICA Consensus Conference on the Management of Patients with Long-Gap Esophageal Atresia: Perioperative, Surgical, and Long-Term Management. *Eur J Pediatr Surg.* 2021;31(3):214-25.
9. Stadil T, Koivusalo A, Svensson JF, Jönsson L, Lilja HE, Thorup JM, et al. Surgical treatment and major complications Within the first year of life in newborns with long-gap esophageal atresia gross type A and B – a systematic review. *J Pediatr Surg.* 2019;54(11):2242-9.
10. Saleem M, Iqbal A, Ather U, Haider N, Talat N, Hashim I, et al. 14 Years' experience of esophageal replacement surgeries. *Pediatr Surg Int.* 2020;36(7):835-41.
11. Liu J, Yang Y, Zheng C, Dong R, Zheng S. Surgical outcomes of different approaches to esophageal replacement in long-gap esophageal atresia: A systematic review. *Medicine (Baltimore).* 2017;96(21):e6942.
12. Holland AJA, Ron O, Pierro A, Drake D, Curry JJ, Kiely EM, et al. Surgical outcomes of esophageal atresia without fistula for 24 years at a single institution. *J Pediatr Surg.* 2009;44(10):1928-32.
13. Jensen AR, McDuffie LA, Groh EM, Rescorla FJ. Outcomes for Correction of Long-Gap Esophageal Atresia: A 22-Year Experience. *J Surg Res.* 2020;251:47-52.
14. Reismann M, Granholm T, Ehrén H. Partial gastric pull-up in the treatment of patients with long-gap esophageal atresia. *World J Pediatr.* 2015;11(3):267-71.
15. Hirschl RB, Yardeni D, Oldham K, Sherman N, Siplovich L, Gross E, et al. Gastric transposition for esophageal replacement in children: experience with 41 consecutive cases with special emphasis on esophageal atresia. *Ann Surg.* 2002;236(4):531-9; discussion 539-41.
16. Ho KY. Clinical significance of post-operative bile reflux gastritis. *JGH Open.* 2022;6(3):157-8.
17. Vavricka SR, Greuter T. Gastroparesis and Dumping Syndrome: Current Concepts and Management. *J Clin Med.* 2019;8(8):1127.