

Case Report

Management and Repair of Diaphragmatic Hernia during Pregnancy with a Double Approach

Martínez M, Fernández J, Sánchez P, Morales G, Lorenzo JM, Hernández PL and Salinas T*

Department of Thoracic Surgery, General Surgery, Gynecology and Gastroenterology, Hospital Español, Mexico

Abstract

Diaphragmatic Hernia (DH) is considered when the abdominal viscera shift into the thoracic cavity, it is classified into three categories: congenital, acquire and traumatic. One-third of the patients are symptom-free, it can lead to a high mortality rate, ranging from 22% to 80% if strangulation occurs. The patient with diaphragmatic hernia may be asymptomatic until the late weeks of gestation. DH is a rare complication during pregnancy, which is associated with poor prognosis; it is thought that it has to be treated by early surgery, during the second trimester. We describe the management of a pregnant woman at 27 weeks gestation with a left diaphragmatic hernia with gastric strangulation with a multidisciplinary treatment.

Keywords: Diaphragmatic hernia; Pregnancy; Laparoscopic fundoplication; Thorax

Case Presentation

A 30-year-old woman (Gravida 3, Caesarea 1, Abortion 1) at 27 weeks gestation, she has a history of a laparoscopic fundoplication 5 years after because a hiatal hernia, was admitted to our emergency department at 29 weeks gestation for acute dyspnea and chest pain, it has a 2 weeks symptoms with Postprandial fullness on early satiety, progressive dysphagia to solids, oppressive type epigastric pain, shortness of breath, weight loss of 6 Kgs. Vital signs with moderate distress respiratory rate 26 bpm, systolic blood pressure of 100 mmHg and a diastolic blood pressure of 60 mmHg, heart rate 95 bpm, and body temperature at 36.7°C. Physical examination revealed reduced breath sounds over the lungs with tympani to percussion on the left side. A chest radiograph demonstrated a left herniation of the stomach and bowel to the thorax (Figure 1).

An endoscopy was performed up on admission, finding gastric fungus migration to chest with gastric torsion and gastropathy, the initial management was made by an endoscopy (Figure 2), at that time there was no evidence of fetal distress, ultrasound studies and fetal focus record were performed. Laboratory test showed in the Hematic Biometry a HC 8 g/dl Htc 24% Pl $236 \times 10^3/\mu\text{L}$ WBC $5.9 \times 10^3/\mu\text{L}$ Biochemistry test Gl 84 mg/dl Alb 2.3 g/dl Cr 0.7 mg/dl. The patient was admitted to the maternal unit.

Because of the stable vital signs and less abdominal pain it was treated on the basis of liquid nutrition with polymeric Formula,

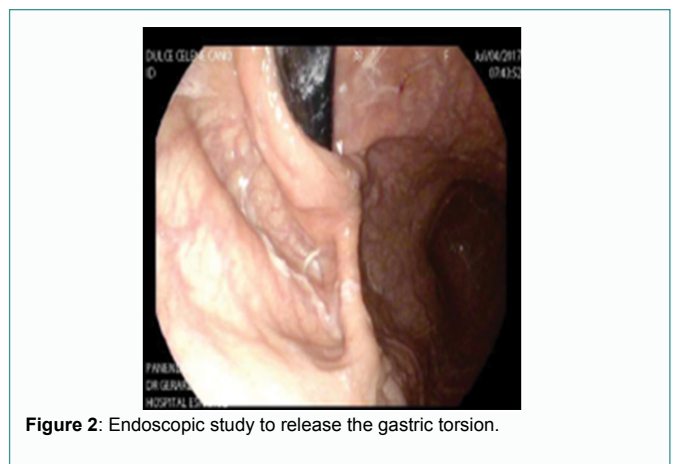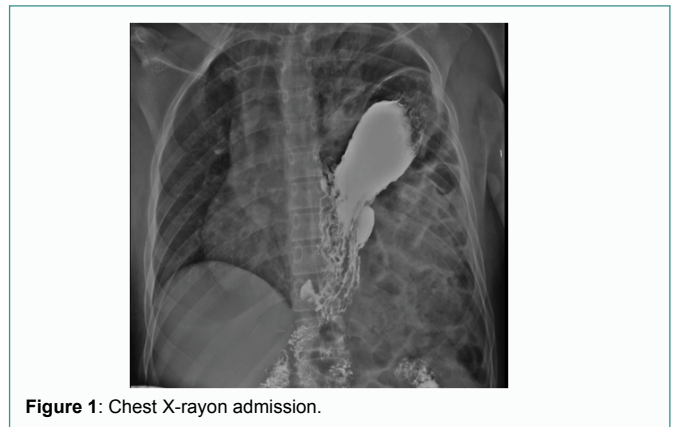Citation: Martínez M, Fernández J, Sánchez P, Morales G, Lorenzo JM, Hernández PL, et al. Management and Repair of Diaphragmatic Hernia during Pregnancy with a Double Approach. *Int J Minim Access Surg.* 2020; 1(1): 1003.

Copyright: © 2020 Martínez M

Publisher Name: Medtext Publications LLC

Manuscript compiled: Feb 07th, 2020

***Corresponding author:** Tania Salinas, Department of Thoracic Surgery, General Surgery, Gynecology and Gastroenterology, Hospital Español, Mexico, E-mail: taysalinasb@gmail.com



intravenous Iron Therapy, during the first two weeks, the diet was progressed to chopped foods and the observation was continued for a week more, was discharged at 30 weeks gestation with pulmonary maturation scheme blood count 10 g/dl Alb 3.1g/dl and a weight gain of 4 Kg.

Pregnancy was interrupted at 36 weeks gestation because the patient started again with weight loss and lack of fetal growth, a

cesarean section was performed, a live baby girl was delivered with 2,390 Kgs, an Apgar 9/9, breast feeding was established, a minimally invasive procedure was performed with double simultaneous approach, abdominal approach was made by 4 ports, and the thoracic approach was made by a single port (Figure 3). A defect in the diaphragm of 10 cms × 10 cms with gastric and intestinal involvement of the thorax was identified, the hernia was reduced releasing adhesions in the thorax and the previous fundoplication was dismantled, the diaphragmatic defect was repaired with interrupted sutures, it was complemented by a gastric fundoplication (Figure 4 and 5). A mesh was placed via thorax and fixed by stapler, simple suture points was fixed with the pleura to cover the hiatus (Figure 6), drains were placed in both cavities, the patient presented a good evolution at the second day was mas a fluoroscopic swallow study without reporting leakage or reflux (Figure 7), liquid diet was started and progressed to chopped food at the third day, intrathoracic drainage was removed at the fifth day, the patient was discharged at the seventh day. A fluoroscopy swallow study was made a month after the surgery as a control (Figure 8).

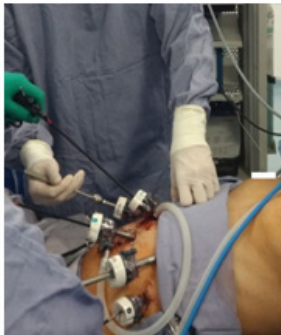

Figure 3: Surgery with double simultaneous approach for minimal invasive, 5 ports at abdominal approach and thoracic uniportal technique.

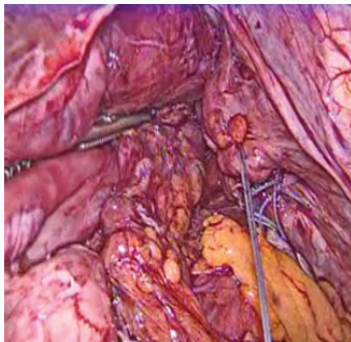


Figure 4: Diaphragmatic hernia defect closure, interrupted sutures were placed.

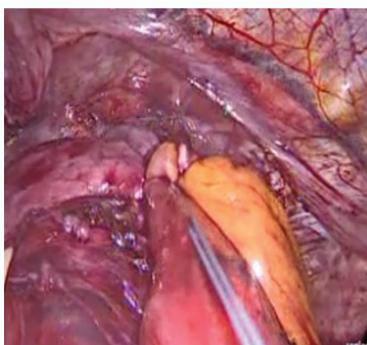


Figure 5: Redu-Fundoplication.

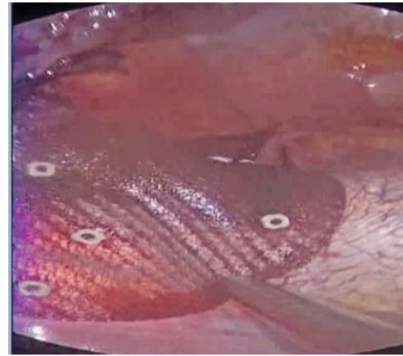


Figure 6: Mesh placed via thorax and fixed by stapler.

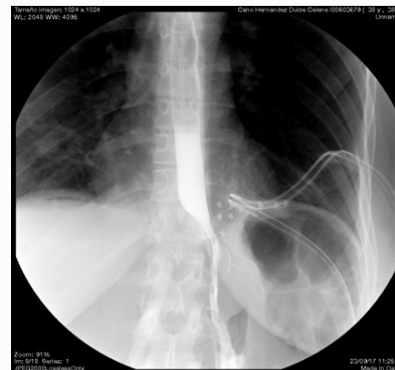

Figure 7: Fluoroscopic swallow study at the second day after surgery, the application effect is observed, the mesh placed by thorax, left pleural drainage.

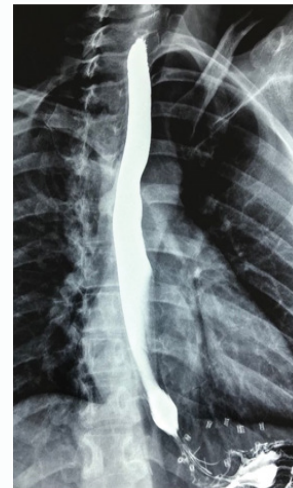

Figure 8: Fluoroscopic swallow study was made a month after the surgery as a control.

Discussion

It is described three categories of DH: Congenital-raising from a faulty embryologic development, Acquired, that is developed at points of anatomical weakness (esophageal hiatus, aortic or caval openings) and Post Traumatic, caused by a direct lesión or indirect trauma, DH during pregnancy can be presented in all of the three categories, with a similar incidence (40%, 30%, 30%) [1-3].

In the Literary review we found 34 cases of diaphragmatic hernia in pregnancy 30 of them were operated within the second and third trimesters, 20 (66%) have been operated on an emergency 11 cases

(55%) were due to a strangulated organ, 9 of 34 cases reported fetal death, in 5 of this 9 cases maternal deaths also occurred [4]. From our perspective, we believe that this condition puts at risk the life of the fetus and the mother if it is not attended at the right time under a multi disciplinary group, we commend that the management of patients be determined by their clinic, as discussed in these reports using different alternatives to stable the mother condition so the surgery can be delayed as long as possible [5-8]. Therefore, antenatal corticosteroids for fetal maturity should be administered to the mother before the surgery if the gestational age is between 24 and 34 weeks [8]. Gastric decompression might improve the clinical condition of the pregnant patient with a diaphragmatic hernia who presents with symptoms and signs of obstruction [6,8]. Standard vaginal delivery should be avoided in these cases because the increase in the intra abdominal pressure may further displace the vicar and result in strangulation of the herniated viscus [9,10].

It should be considered a simultaneous abdominal and thoracic approach since this approach provides greater security for dissection and tissue management makes more complete the repair [10]. In our review, we found the use of mesh [11-14], in our case we report the placement via thoracic as a complement of the repair via abdominal way. We believe that in this case, it was possible to repair the diaphragm in a second time since the patient remained stable at all times, during pregnancy after de endoscopy the patient did not present data of a new event of gastric torsion, intestinal suffering for respiratory compromise.

We do not recommend an aggressive operative approach if the patient is stable, the uterine enlargement can cause displacement of the abdominal viscera but this growth is slow and gradual so in some cases, it can be accommodated in a certain position that does not affect the patient.

Conclusion

The management of pregnant patients with diaphragmatic hernia depends on the clinical presentation and gestational age. It is recommended by all the therapeutic tools to carry a higher gestational age before surgical treatment. It is recommended the use of mesh as a complement to the closure of the hernia defect. We consider that the double approach is the best option since this provides better control of structures. We recommend performing the procedure in a minimally in evasive way because of the direct vision it provides, a better dissection and it can be done simultaneously abdominal and thoracic.

References

1. Chen Y, Hou Q, Zhang Z, Zhang J, Xi M. Diaphragmatic Hernia during pregnancy: A case report with a review of the literature from the past 50 years. *J Obstet Gynaecol Res.* 2011;37(7):709-14.
2. Kushlan SD. Diaphragmatic Hernia in pregnancy: significance and danger. *Conn State Med J.* 1951;15(11):969-78.
3. Yetkinel S, Peksen Ç, Kiziltan R. Symptomatic Bochdalek Hernia in Pregnancy: A Rare Case Report. *Case Rep Surg.* 2017;2017:2862149.
4. Julien F, Drolet S, Lévesque I, Bouchard A. The Right Lateral position for laparoscopic Diaphragmatic hernia Repair in Pregnancy: Technique and Review of the Literature. *J Laparoendosc Adv Surg Tech A.* 2011;21(1):67-70.
5. Kurzel RB, Naunheim KS. Repair of an asymptomatic diaphragmatic hernia during pregnancy. *Obstet Gynecol.* 1988;71:869-71.
6. Fleyfel M, Provost N, Ferreira JF, Porte H, Bourzoufi K. Management of diaphragmatic hernia during pregnancy. *Anesth Analg.* 1998;86(3):501-3.
7. Fardy HJ. Vomiting in late pregnancy due to diaphragmatic hernia. Case report. *Br J Obstet Gynaecol.* 1984;91(4):390-2.
8. Genc MR, Clancy TE, Ferzoco SJ, Norwitz E. Maternal Congenital Diaphragmatic Hernia Complicating Pregnancy. *Obstet Gynecol.* 2003;102(5 Pt 2):1194-6.
9. Luu TD, Reddy VS, Miller DL, Force SD. Gastric Rupture Associated With Diaphragmatic Hernia During Pregnancy. *Ann Thorac Surg.* 2006;82(5):1908-10.
10. Kaloo PD, Studd R, Child A. Postpartum diagnosis of maternal diaphragmatic hernia. *Aust N Z J Obstet Gynaecol.* 2001;41(4):461-3.
11. Thoman DS, Hui T, Phillips EH. Laparoscopic diaphragmatic hernia repair. *Surg Endosc.* 2002;16(9):1345-9.
12. Yamaguchi M, Kuwano H, Hashizume M, Sugio K, Sugimachi K, Hyoudou Y. Thoracoscopic treatment of Bochdalek hernia in the adult: Report of a case. *Ann Thorac Cardiovasc Surg.* 2002;8(2):106-8.
13. Willemsse P, Schütte PR, Plaisier PW. Thoracoscopic repair of a Bochdalek hernia in an adult. *Surg Endosc.* 2003;17(1):162.
14. Sano A, Kato H, Hamatani H, Sakai M, Tanaka N, Inose T, et al. Diaphragmatic hernia with ischemic bowel obstruction in pregnancy: report of a case. *Surg Today.* 2008;38(9):836-40.