

Short Communication

Managing Children with Medulloblastoma Algerian Experience

Ezziane K¹, Bouallag M^{2*}, Habchi N², Mahiou M³ and Bouzid K¹

¹Department Paediatric Oncology, Pierre and Marie Curie Centre, Algiers, Algeria

²Department of Neurosurgery Mustapha Pacha Hospital, Algiers, Algeria

³Department of Radiotherapy, Pierre and Marie Curie Centre, Algiers, Algeria

Abstract

A retrospective study was undertaken on 194 patients in pediatric age group with diagnosis of medulloblastoma, treated from 1994-2009 at our oncologic centre. For all the patients, the diagnosis was made after surgery. All patients received adjuvant chemotherapy.

The combined modality of chemotherapy and radiotherapy results is satisfactory for loco regional control and survival and acceptable for toxicity in patients with medulloblastoma in pediatric age group.

Keywords: Medulloblastoma; Managing; Results; Key for progress

Introduction

While leukaemia's are the most common type of malignancy to afflict the pediatric population, brain tumours are the most common solid tumours in this age group [1]. Medulloblastoma is the most common malignant brain tumour in children constituting nearly 20% of all pediatric brain tumours [2]. It is categorized as an embryonal neuroepithelial tumour of the cerebellum. This is a high-grade tumour that has a propensity to spread *via*. the cerebrospinal fluid.

Objectives

The object if of our work is to establish the characteristics and outcome of the patients with medulloblastoma in pediatric age group.

Material and Methods

A retrospective study was undertaken on 194 patients in pediatric age group with diagnosis of medulloblastoma, treated from 1994-2009 at our oncologic centre. For all the patients, the diagnosis was made after clinical examination, imagery and surgery.

Post-Operative Treatment

All patients have received the adjuvant treatment which depended on the stage of the disease. This treatment was based on chemotherapy, including eight drugs in one day. Vincristine, bicnu, solumedrol, natulan, hydrea, cis-platinum, aracytine, endoxan, (6 courses from the 1st day to 21th day). Since 2004, they received two drugs: carboplatine and etoposide (4 courses from the 1st day to 28th day). Under 5 years old, they received BBSFOP protocol, 7 cycles. For

Citation: Ezziane K, Bouallag M, Habchi N, Mahiou M, Bouzid K. Managing Children with Medulloblastoma Algerian Experience. Clin Neurol Int. 2020; 2(1): 1011.

Copyright: © 2020 Ezziane K

Publisher Name: Medtext Publications LLC

Manuscript compiled: April 16th, 2020

***Corresponding author:** Bouallag M, Department of Neurosurgery Mustapha Pacha hospital, Algiers, Algeria, E-mail: nawelmedbio@yahoo.fr

the radiation therapy they received 55 Gys for posterior fossa and 35 Gyscranio for the spinal axis.

Results

The patients age was from 3 months to 20 years with middle age of 6,7 years. The sex ratio woman/man was 1.6, 18% of patients didn't have residue or metastasis-82% of patients had residue or metastasis (Figure 1) (Tables 1 and 2).

Histological examination revealed 89% classical medulloblastoma (174 cases), 7% desmoplastic (13 cases) and 4% anaplasia (7 cases) (Figure 2A). The distribution of percentages by age is demonstrated

Table 1: Chang staging.

G1: Total or subtotal removal of the tumour no evidence of metastasis disease: 18%.
G2: Gross residual tumour, metastases in the central nervous system: 82%.

Table 2: Os/extent of disease.

	3 years	5 years
G1	65%	60%
G2 M-	45%	26%
G2 M+	19%	1%

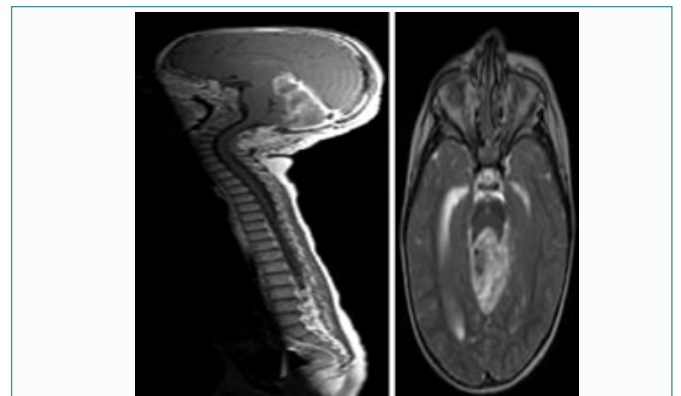


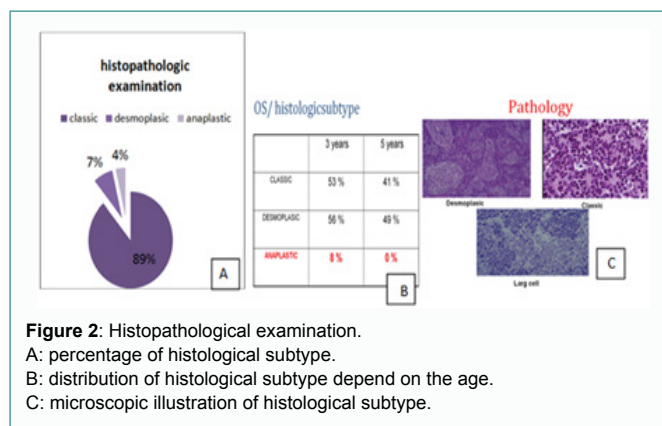
Figure 1: Cerebro spinal MRI show the extension of the medulloblastoma.

in the Figure 2B.

Late effects that appeared after the radiotherapy are neurological deficit (55%), endocrine deficit (21%), TSH-GH Short stature (RTH +/- GH), Neuropsychological disorder (35%) as school failure (Figure 2C).

The evaluation is done after the Clinical examination, Lumbar puncture for CSF cytology and imagery (brain MRI or CT scan).

The combined modality of chemotherapy and radiotherapy revealed: 68% partial response, 13,6% stabilizations and 18,4% progression. After median follow-up of 48 months, overall survival and disease free survival for entire group was 60% and 45%.



Discussion

Within the first few years of diagnosis of the medulloblastoma, mortality approximates 15%; however, cure rates can reach as high as 60% with current therapeutic modalities [3,4]. Surgical resection preceded and/or followed by radiation and chemotherapy is the mainstay of therapy, with five-year survival rates of between 50% - 90%. This wide range is multifactorial, owing in part to age at diagnosis, the presence of metastases at diagnosis, and a histologic variant of medulloblastoma [1,5]. Regardless of long-term survival, treatment-related cognitive, neurologic, and endocrinologic effects remain a debilitating concern and an impetus for the search for further therapeutic modalities.

Current treatment modalities for medulloblastoma combine surgical resection with chemotherapy and radiation. By traditional risk stratification, cure rates in the average-risk group reached three-quarters of patients. However, post-surgical treatment-related neurologic, cognitive, and endocrinologic sequela, including intellectual retardation and growth hormone deficiency, remain a source of morbidity in up to 80% of survivors. The high-risk group experienced up to 50% mortality due not only to the presence of extraneural metastases at diagnosis but also due to their young age at diagnosis, which poses significant limitations to their therapeutic options, namely lower doses of radiation and chemotherapeutic agents [1,6].

Conclusion

Medulloblastoma management strategies, which encompass surgical resection of the tumour, cranio-spinal irradiation and chemotherapy, are discussed, together with the possibility of focusing more on disease biology and robust molecularly driven patient stratification in future clinical trials.

References

- Gilbertson RJ. Medulloblastoma: signalling a change in treatment. *Lancet Oncol.* 2004;5(4):209-18.
- Rossi A, Caracciolo V, Russo G, Reiss K, Giordano A. Medulloblastoma: from molecular pathology to therapy. *Clin Cancer Res.* 2008;14(4):971-6.
- Pfister S, Remke M, Benner A, Mendrzyk F, Toedt G, Felsberg J, et al. Outcome prediction in pediatric medulloblastoma based on DNA copy-number aberrations of chromosomes 6q and 17q and the MYC and MYCN loci. *J Clin Oncol.* 2009;27(10):1627-36.
- Wu X, Northcott PA, Croul S, Taylor MD. Mouse models of medulloblastoma. *Chin J Cancer.* 2011;30(7):442-9.
- Huse JT, Holland EC. Genetically engineered mouse models of brain cancer and the promise of preclinical testing. *Brain Pathol.* 2009;19(1):132-43.
- Bunin GR, Kushi LH, Gallagher PR, Rorke-Adams LB, McBride ML, Cnaan A. Maternal diet during pregnancy and its association with medulloblastoma in children: a children's oncology group study (United States). *Cancer Causes Control.* 2005;16(7):877-91.