

Case Report

Mutation in *PIK3CD* Associated with Immunodeficiency, Autoimmune Hemolytic Anemia and Splenomegaly

Nilgun Eroglu¹, Ömer Akcal^{2*}, Metin Cil³, Hatice Mutlu Albayrak⁴ and Dilek Karagoz⁵

¹Department of Pediatric Hematology and Oncology, Afyonkarahisar Healthy Science University, Turkey

²Department of Pediatrics, Division of Immunology and Allergy Clinic Istanbul Biruni University, Turkey

³Department of Pediatric Hematology and Oncology, Cengiz Gokcek Maternity and Children Hospital, Turkey

⁴Department of Pediatrics, Genetic Cengiz Gokcek Maternity and Children Hospital, Turkey

⁵Department of Pediatric Immunology, Çukurova University, Turkey

Abstract

Activated PI3K-Delta Syndrome (APDS) is an immunodeficiency caused by gain-of-function mutations in *PIK3CD*. This disease exhibits complex immune phenotypes including increased IgM, recurrent infection, and impaired vaccine responses. Patients with APDS also experience other complications including lymphoid hyperplasia, autoimmunity, increased susceptibility to herpes viruses, especially Epstein-Barr virus and cytomegalovirus, and an increased incidence of B-cell lymphoma. In this case report, a young girl with a *PIK3CD* mutation is described, who presents with splenomegaly, cytopenia and lymphadenopathy was presented. Early identification of patients who suffer from such new primary immunodeficiency disorders can prevent complications such as malignancy.

Keywords: Immunodeficiency; Autoimmune hemolytic anemia; Splenomegaly; *PIK3CD*

Introduction

Activated Phosphoinositide-3 kinase Delta Syndrome (APDS) is a rare disorder; resulting from activating mutations of Phosphoinositide 3-Kinase Delta (PI3K δ). PI3K δ as a heterodimer consists of a p85 family regulatory subunit and the phosphatidylinositol-4, 5-bisphosphate 3-kinase catalytic subunit delta isoform (p110 δ). Especially; heterozygous, gain-of-function mutations in the catalytic subunit of p110 δ (*PIK3CD*) can cause APDS. Augmented PI3K δ signaling causes terminal differentiation and senescence of T cells, increased transitional B cells, and immunoglobulin derangements [1,2]. Clinical manifestations of APDS are highly variable, ranging from asymptomatic patients to those with primary antibody deficiency, those with a profound immunodeficiency causing early death, to others suffering from lymphoproliferation and malignancy. Treatment of patients with APDS considerably varying from simple observation to Haematopoietic Stem Cell Transplant (HSCT) during childhood. Disease manifestations mostly have a pediatric onset with recurrent respiratory infections usually the first manifestation occurring in infancy or childhood followed by bronchiectasis and autoimmunity in later childhood as is seen in the case discussed in this report. Other complications such as an increased incidence of B-cell lymphoma, lymphoid hyperplasia, high vulnerability to herpes

viruses, especially cytomegalovirus, and Epstein-Barr Virus (EBV) are the ones which the patients with APDS experience as well.

In this case report, a young girl with a *PIK3CD* mutation is described, who presents with splenomegaly, cytopenia and lymphadenopathy was presented.

Case Presentation

A 10 years old female Syrian patient was referred due to anemia and thrombocytopenia to pediatric hematology and oncology department. Laboratory investigation documented; white blood count: 13600/uL, hemoglobin: 5.7 g/dl, mean corpuscular volume: 76.1 fl, platelet: 22000/uL, reticulocytes 22%. Her twin was died four years ago for an unknown reason. Her parents were died in the war and we learned that they had consanguineous marriage. Our patient was suspected to have lymphoproliferative disease and humoral defects, and pneumonia (at least 15 episodes) during t childhood. She had massive splenomegaly, and multiple lymphadenopathies in the abdomen and servical region. Serologic analysis of EBV and other viral markers were negative. Periportal, parailiac, paraaortic, inguinal multiple 2 cm lymphadenopathy was detected in abdominal ultrasound. The lymph node biopsy from submandibular region was documented lymphoid hyperplasia. Direct coombs and antinuclear antibody were both positive. Work-up at that time revealed IgA 1, 61 (0, 7 g/L-4 g/L), IgG 30, 5 (7 g/L-16 g/L), IgM 6, 03 (0, 4-2, 3 g/L). Flow cytometry revealed normal level of T and B cell, respectively. Her CD4+T cell count was 34, 2 mm³ (38, 27-56, 47) and CD8+ T cell count was 25, 2 mm³ (23-35). The count of Natural Killer (NK) cells was normal. Double negative $\alpha\beta$ T cells were (1%, 3%) within normal limits. Analysis of the granulocytes for oxidative burst and phagocytic potential yielded adequate responses.

She had recurrent hospitalizations due to hemolytic anemia, pneumonias, and sinusitis. Examination of bone marrow aspiration and bronkoscopy were not show abnormalities.

Citation: Eroglu N, Akcal Ö, Cil M, Albayrak HM, Karagoz D. Mutation in *PIK3CD* Associated with Immunodeficiency, Autoimmune Hemolytic Anemia and Splenomegaly. J Clin Pharmacol Ther. 2021;2(2):1020.

Copyright: © 2021 Nilgun Eroglu

Publisher Name: Medtext Publications LLC

Manuscript compiled: Oct 07th, 2021

***Corresponding author:** Ömer Akcal, Department of Pediatrics, Division of Immunology and Allergy Clinic Istanbul Biruni University Istanbul, Turkey, E-mail: omerakcal@hotmail.com

Because of having recurrent respiratory infections accompanying hypogammaglobulinemia, intravenous immunoglobulin was started which also make benefit of decreasing the coombs positive hemolytic anemia attack besides prevention of recurrent infections.

At age of 11 she continued to have recurrent infections on her lower and upper respiratory tract, bilateral otitis media, mastoiditis prompting further laboratory assessment.

Based on the computer tomography imaging, there were mediastinal, subcarinal 3 cm lymphadenopathy and peribronchial thickening as well as adenopathy (Figure 1). She was operated for appendicitis at the age of 11, 5 also she received antibiotics for peritonitis.

Immune deficiency panel (by using the Illumina NextSeq platform) including more than 300 disease related genes was performed for revealing the molecular pathology of the disease. The c.3061G>T p. (Glu1021Lys) heterozygous missense variant (NM_005026.3) was identified on *PIK3CD* gene (Figure 2). This variant was previously reported and classified as a disease causing according to prediction databases ACMG classification criteria. As a consequence of molecular results, the diagnosis of APDS was confirmed.

Rituximab was given at the age of 12 to decrease the size of her hepatosplenomegaly and lymphadenopathy Trimethoprim/sulfamethoxazole prophylaxis was started to help prevent infections.

When she was 13, she received rapamycin to improve her lymphoproliferative disease. She had inconsistent compliance and her blood cell counts showed intermittent declines and she continually had lymphadenopathy (Table 1).

Discussion

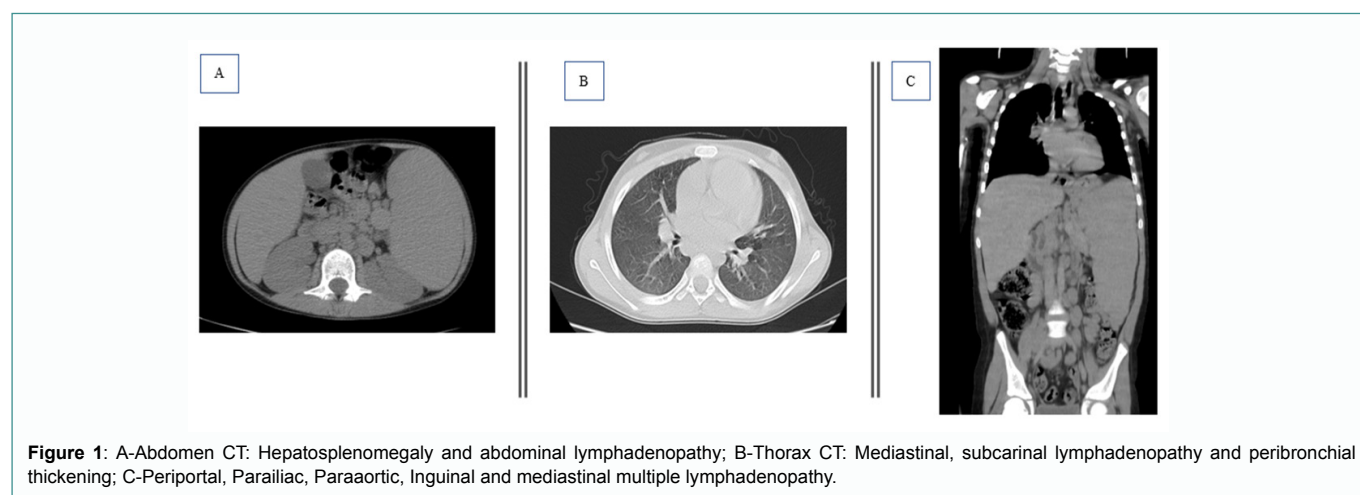
To diagnose the different new primary immunodeficiency disorders, techniques of Next Generation Sequencing (NGS) are continually used. We used targeted NGS to identify the underlying cause of cytopenia, splenomegaly, frequent infection, hyper IgM and found a heterozygous missense mutation in *PIK3CD* [p.(Glu1021Lys)].

Overview of the APDS clinical course with confirmed gain of function *PIK3CD* mutation was presented in the present case. Due to monoallelic GOF (gain of function) mutations in the *PIK3CD* gene and monoallelic LOF (loss of function) mutations in the *PIK3R1* gene encoding p110d (*PIK3CD*) and p85a (*PIK3R1*), APDS are termed APDS1 and APDS2, respectively.

When the clinical features of APDS2 and APDS1 were compared in the literature, there was a similar phenotype between them. But a lower prevalence of lymphoma and a higher prevalence of bronchiectasis were detected in the APDS1 cohort than the APDS2, and the APDS2 was showed growth retardation. Also, their treatments were different [1].

Generally, in the childhood period, recurrent infections of the sinuses, lungs, and ears usually start in these patients [1]. 53 patients with *PI3Kδ* mutations were studied to show that pneumonia (85%) and recurrent respiratory tract infections (98%) were the most common infectious presentations [1]. The literature reported 33%-75% of APDS patients to have bronchiectasis [3-5]. The most common bacterial pathogens were *Streptococcus pneumoniae* and *haemophilus influenzae* [1]. One study showed that there were severe, persistent, or recurrent *herpesvirus* infections, especially *Cytomegalovirus* (CMV), varicella zoster virus, and EBV in 49% of the patients [1]. The study also reported molluscum contagiosum, *aenovirus*, and warts [4]. Our patient had otitis media infections, recurrent respiratory tract infections, and pneumonia. There is also frequent description of the autoimmune manifestations including autoimmune hemolytic anemia and cytopenias that our patient experiences [1].

Abnormal proliferation of white blood cells is stimulated by *PI3Kδ* signaling and it is leading to nodular lymphoid hyperplasia and lymphadenopathy [5]. *PI3Kδ* is present predominantly in leukocytes, and it is effective in proliferation of leukocyte activation, and survival [4]. In immune cells; downstream of toll-like receptors, cytokine receptors, T-cell and B-cell receptors, and small GTP (guanosine triphosphate) ases' Ras super family is activated by *PI3Kδ* [5]. Kinases PDK1 (Pyruvate Dehydrogenase Kinase 1) and AKT are activated by PIP3 produced by *PI3Ks* causing to activate the mTOR complex 1 and inhibit the FOXO (Fork head family of transcription factors) family of transcription factors [6]. A common comorbidity is nonneoplastic lymphoproliferation which has been reported 75% of these patients with mucosal lymphoid hyperplasia 32%, splenomegaly (58%), hepatomegaly (45%) or lymphadenopathy (64%), as the more common manifestations of the disease [1]. Despite the benign changes, there may be complications based on involvement site. B-cell lymphoma development may be affected by increasing B-cell proliferation combined with reduction of immune system [5,6]. In the present case; lymphadenopathy, splenomegaly were detected. About 13% of APDS patients were reported to have lymphoma but our patients' lymph node biopsy was detected as benign proliferation



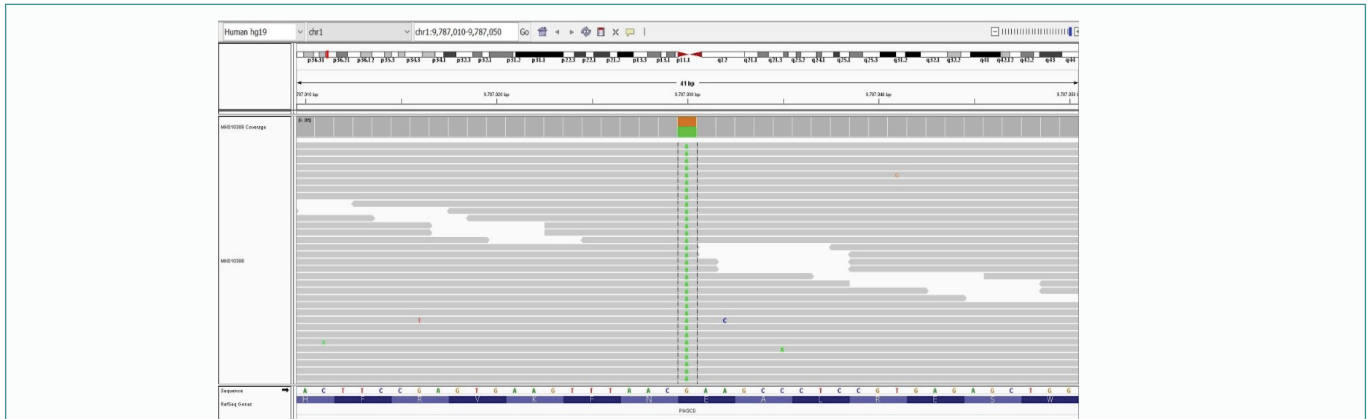
Figure 2: *PIK3CD* gene

Table 1: Laboratory data in clinical follow-up.

	Normal Range	1 year prior	Presentation	1 week after presentation	3 months after rituximab cycle	3 months after rapamycin cycle
White blood cell count	3980-10040/uL	11280	13860	6720	8490	6340
Hemoglobin	11,2-15,7 g/dl	4,9	5,7	4,7	10	14,4
Platelet	140000-369000/uL	154000	22000	152000	81000	195000
Neutrophil count	1560-6130/uL	7100	12750	3910	5670	4490
Lymphocyte count	1180-3740/uL	2770	600	2270	1880	1180
Lactate dehydrogenase	100-332 U/L	442	1120	657	1824	231
Spleen size with USG	17 cm	16,3	16,7	20	20	15

[1]. According to other theories, the persistent lymphoid system activation and the lymphocytes' inherent genetic instability may cause to increase risk of malignancy in APDS7. About 30% of APDS patients have EBV-infection and PI3K δ signaling plays the important role in controlling EBV. Using the *PIK3CD* gene regarded as an oncogene linked to diffuse large B-cell lymphomas, and there has been link between constitutive PI3K activation and other B-cell malignancies, for example, Burkitt lymphomas [5-9].

It was discussed that APDS patients have commonly lymphadenopathy and differential diagnosis makes evaluation of this challenging [1,5,6,10]. There should be more examinations for evaluation of the malignancy particularly in the constitutional symptoms setting due to persistence of lymphadenopathy or worsening despite treatment.

This case report has limitations. We couldn't detect genetic mutation in our Syrian patients' parents and brother.

Hematopoietic stem cell transplantation is currently the curative option only available for APDSs performed for a small-sized cases, being successful in resolution of infection and nonneoplastic lymphoproliferation and restoration of normal growth [11,12].

The purpose of other therapies is to prevent comorbidities related to this syndrome such as autoimmune, lymphoproliferative, and infectious complications. For treatment, the focus is on defending of the immune system and management of dysregulation. There is reported benefit with immunoglobulin replacement and antimicrobial prophylaxis [1,5]. The corticosteroids should be used due to management of lymphoproliferative disease and autoimmune complications [6,13]. It has been reported that Rituximab has been useful for management of non-neoplastic lymphoproliferative disease and autoimmune hemolytic anemia [1,14,15]. There has been clinical benefit for this monoclonal CD20 antibody for our patient and several other APDS patients [1,13].

Mycophenolate, azathioprine, rapamycin and cyclosporine have also been used as other immunosuppressive drugs [1,4,13].

It has been shown that Rapamycin (sirolimus) drug which is used commonly for prevention of transplant rejection has effectively reduced lymphadenopathy and hepatosplenomegaly in APDS and other patients with immune deficiency. The functional testing of the patients who have activating mutations in *PIK3CD* shows mTOR signaling and increasing AKT phosphorylation [4]. Using mTOR inhibitors i.e. rapamycin inhibits lymphocyte activation and the reduction of ribosomal protein S6 phosphorylation has been shown in in-vitro studies.

There has been increase of the targeted therapies in the last few years. APDS patients are cured with a treatment method which includes dysregulation management in PI3K δ . The selective p110 δ inhibitors include GS-1101 (idelalisib or CAL-101), studied in patients suffering from chronic lymphocytic leukemia and the patients have tolerated these drugs, indicating that lymphoma development may be prevented by this treatment [5,14]. A clinical trial of 6 APDS patients found small molecule inhibitor of p110 δ , i.e. Leniolisib (CDZ173), to suppress PI3K δ pathway hyperactivation based on the drug dose [15]. This trial showed an improvement in lymphoproliferation using the oral medication, reducing spleen volumes and lymph node sizes by 39% and 40%, respectively. There was reduction of the senescent CD4 and CD8 T cells levels and also transitional B cells. There was overall good toleration of the medication without clinical side effects noted and significant laboratory disturbances [15].

Conclusion

For the patients with lymphadenopathy, pancytopenia and recurrent infections and autoimmune hemolytic anemia, *PIK3CD* mutations should be considered. Because of the progresses in genetic evaluation of the primary immunodeficiency's and sequencing, such mutation has been recently discovered. The therapeutic interventions such as using the targeted small molecules and immunomodulatory

agents, preventing escalation of autoimmune disease and curtailing progressing of the sequelae such as malignancy and infections. Early identification of patients who suffer from such new primary immunodeficiency disorders can prevent complications such as malignancy.

References

- Coulter TI, Chandra A, Bacon CM, Babar J, Curtis J, Screation N, et al. Clinical spectrum and features of activated phosphoinositide 3-kinase delta syndrome: A large patient cohort study. *J Allergy Clin Immunol.* 2017;139(2):597-606.e4.
- Lucas CL, Chandra A, Nejentsev S, Condliffe AM, Okkenhaug K. PI3Kdelta and primary immunodeficiencies. *Nat Rev Immunol.* 2016;16(11):702-14.
- Chinen J, Notarangelo LD, Shearer WT. Advances in basic and clinical immunology in 2014. *J Allergy Clin Immunol.* 2015;135(5):1132-41.
- Lucas CL, Kuehn HS, Zhao F, Niemela JE, Deenick EK, Palendira U, et al. Dominant-activating germline mutations in the gene encoding the PI(3)K catalytic subunit p110d result in T cell senescence and human immunodeficiency. *Nat Immunol.* 2014;15(1):88-97.
- Kracker S, Curtis J, Ibrahim MA, Sediva A, Salisbury J, Campr V, et al. Occurrence of B-cell lymphomas in patients with activated phosphoinositide 3-kinase d syndrome. *J Allergy Clin Immunol.* 2014;134(1):233-6.
- Crank MC, Grossman JK, Moir S, Pittaluga S, Buckner CM, Kardava L, et al. Mutations in PIK3CD can cause hyper IgM syndrome (HIGM) associated with increased cancer susceptibility. *J Clin Immunol.* 2014;34(3):272-6.
- Suarez F, Lortholary O, Hermine O, Lecuit M. Infection-associated lymphomas derived from marginal zone B cells: a model of antigen-driven lymphoproliferation. *Blood.* 2006;107(8):3034-44.
- Carpier JM, Lucas CL. Epstein - Barr Virus susceptibility in activated PI3Kd syndrome (APDS) immunodeficiency. *Front Immunol.* 2017;8:2005.
- Zhang J, Grubor V, Love CL, Banerjee A, Richards KL, Mieczkowski PA, et al. Genetic heterogeneity of diffuse large B-cell lymphoma. *Proc Natl Acad Sci U S A.* 2013;110(4):1398-403.
- Gompels MM, Hodges E, Lock RJ, Angus B, White H, Larkin A, et al. Lymphoproliferative disease in antibody deficiency: a multi-centre study. *Clin Exp Immunol.* 2003;134(2):314-20.
- Sugiyama M, Iguchi A, Yamada M, Terashita Y, Ohshima J, Cho Y, et al. Successful bone marrow transplantation in two sisters with activated phosphoinositide 3-kinase d syndrome 2. *Bone Marrow Transplant.* 2017;52(12):1678-80.
- Nademi Z, Slatter MA, Dvorak CC, Neven B, Fischer A, Suarez F, et al. Hematopoietic stem cell transplant in patients with activated PI3K delta syndrome. *J Allergy Clin Immunol.* 2017;139(3):1046-9.
- Maccari ME, Abolhassani H, Aghamohammadi A, Aiuti A, Aleinikova O, Bangs C, et al. Disease evolution and response to rapamycin in activated phosphoinositide 3-kinase d syndrome: the European society for immunodeficiencies-activated phosphoinositide 3-kinase dsyndrome registry. *Front Immunol.* 2018;9:543.
- Angulo I, Vadas O, Garçon F, Banham-Hall E, Plagnol V, Leahy TR, et al. Phosphoinositide 3-kinase d gene mutation predisposes to respiratory infection and airway damage. *Science.* 2013;342(6160):866-71.
- Rao VK, Webster S, Dalm VASH, Šedivá A, Hagen PMV, Holland S, et al. Effective "activated PI3Kd syndrome"-targeted therapy with the PI3Kd inhibitor leniolisib. *Blood.* 2017;130(21):2307-16.